

# Primary Papillary Thyroid Carcinoma in Thyroglossal Duct Cyst in an Adolescent Girl: A Rare Case Report and Literature Review

Vijay Shankar S<sup>1,\*</sup>, Nanjundaswamy D<sup>2</sup>, Amita K<sup>3</sup>, Raghuveer CR<sup>4</sup>

<sup>1</sup>Professor, <sup>2</sup>Assistant Professor, <sup>3</sup>Associate Professor, <sup>4</sup>Postgraduate student, Department of pathology, Adichunchanagiri Institute of Medical Sciences, B G Nagara, Nagamangala taluk, Mandya district, Karnataka 571448

**\*Corresponding Author:**

E-mail: vijayshankarpatho@gmail.com

## ABSTRACT

*Thyroglossal duct cysts (TDC) are the most common congenital anomaly resulting in midline masses in children (70% in children and 1 % in adults). The occurrence of carcinoma is extremely rare in children as compared to adults. Because of the classical clinical findings of TDC's preoperative diagnosis of malignancies within them are rarely done. Even fine needle aspiration cytology also less valuable in preoperative diagnosis. The final diagnosis is usually an incidental finding in histopathological examination of excised TDC's. We report a rare case of papillary thyroid carcinoma in a 17 year old girl and reviewed in the pertinent background of evidence based literature*

**Keywords:** Thyroglossal duct cyst, Papillary thyroid carcinoma, adolescent, FNAC, histopathology

## INTRODUCTION

Thyroglossal duct cyst (TDC) is formed due to persistence of the tract during migration of rudimentary thyroid gland during embryogenesis, between the base of tongue and thyroid. The incidence of TDC is around 70 % of congenital cystic lesions in children and 7% in adults. [1] The incidence of malignant transformation is around 1%. [2] The malignant transformation is relatively rare in children as compared to adults. The most common malignancy is papillary thyroid carcinoma (PTC). [2-4] Very few cases have been reported in children and adolescents. We report a case of papillary thyroid carcinoma in thyroglossal duct in a 17 year old girl with special reference to cytology and histopathology findings.

## CASE DETAILS

A seventeen year old presented with complaints of swelling in front of the neck of four months duration which was insidious in onset. The patient had no history of dysphagia, odynophagia, hoarseness of voice. There was no history of radiation exposure. There was no significant past medical or family history. She had no signs and symptoms of hypo or hyperthyroidism. On examination the swelling measured 4 x 3 cm which moved with deglutition and protrusion of the tongue. Her vital signs and systemic examination was normal. Her thyroid function and all other laboratory investigations were within normal limits. Preoperatively a clinical diagnosis of thyroglossal duct cyst was made. Ultrasound examination also suggested the same diagnosis. Her both lobes of thyroid and isthmus were normal. She underwent sistrunk procedure and the specimen was sent for histopathological examination.

## Pathological findings:

Grossly the specimen measured 4x3x2 cm. it was predominantly solid with multiple cysts of varying sizes, one of the cyst showed papillary excrescences (Figure 1). No gross calcification was noted. Histopathologically it was a cyst with an intraluminal papillary tumor. (Figure 2) The cyst was lined by cuboidal to stratified squamous epithelium.(figure 2 Inset) The tumor was predominantly in complex papillary pattern ( figure 3) with characteristic nuclear features of grooving and inclusions (Figure 3 inset). Tiny foci of calcification, psammoma body, cyst macrophages and areas of dense sclerosis noted (Figure 4).

Aggregates of lymphocytes, foreign body giant cell reaction and normal thyroid follicles were seen (Figure 5). The tumor was seen infiltrating into the adjacent soft tissue.(Figure 6). Based on the histopathological findings combining with the features of normal thyroid in sonography, the diagnosis of papillary thyroid carcinoma arising in the wall of the thyroglossal duct cyst was made. The patient was advised subsequent total thyroidectomy, with radioactive iodine ablation and thyroxine supplements and regular follow up.

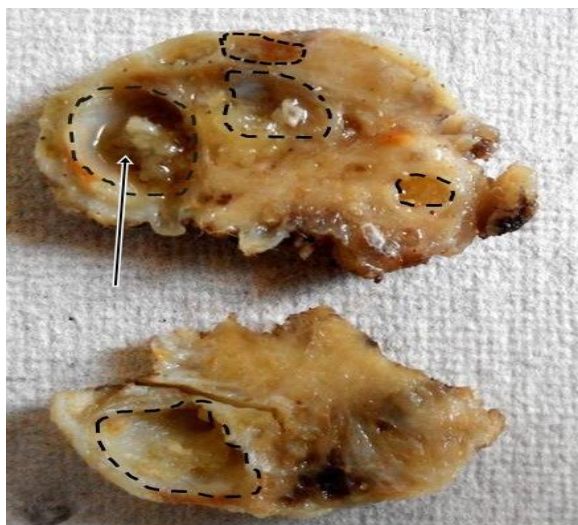

Figure 1: Gross photograph of the specimen showing predominantly solid mass with multiple cystic areas(dotted lines). One of the cyst showing papillary excrescences (arrow)

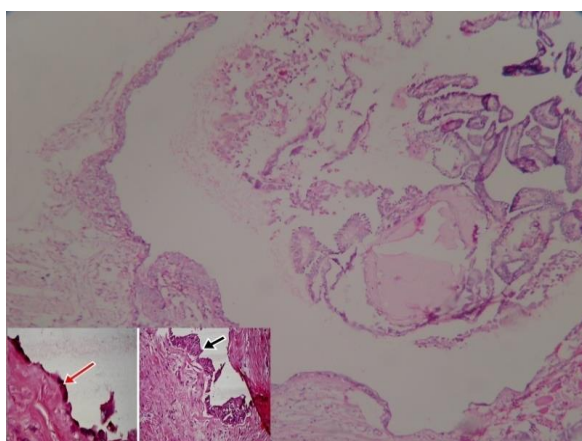


Figure 2: Photomicrograph showing cyst with a intraluminal papillary tumor. H& E X 40. The cyst lined by cuboidal to stratified squamous epithelium(Inset, H& E X 400.).

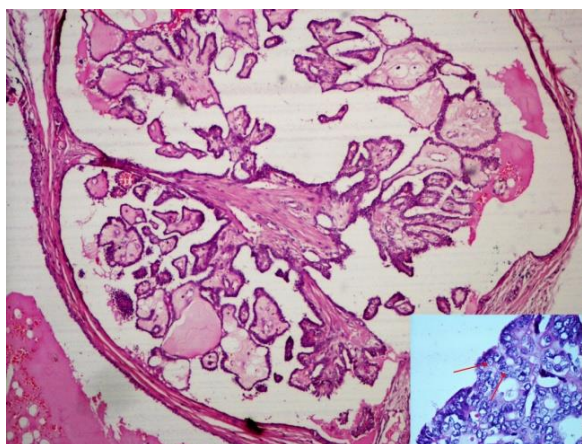


Figure 3: Photomicrograph showing complex papillary pattern (H& E X 100). with characteristic nuclear features of grooving and inclusions(inset, H& E X 400)

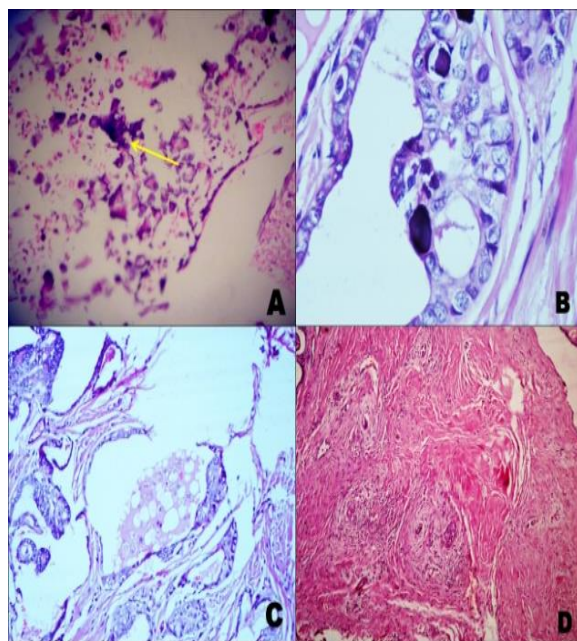


Figure 4: Photomicrograph showing Tiny foci of calcification (A), psammoma body (B), cyst macrophages(C) and areas of dense sclerosis noted (D) (H & E X 100)

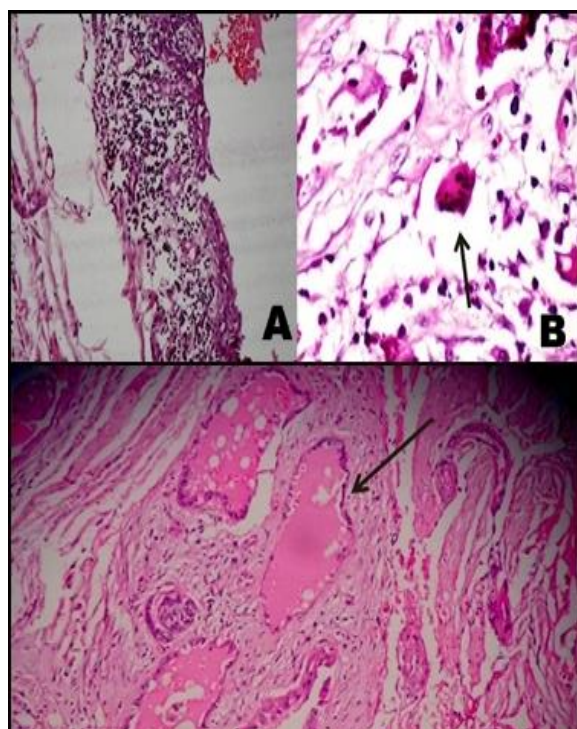
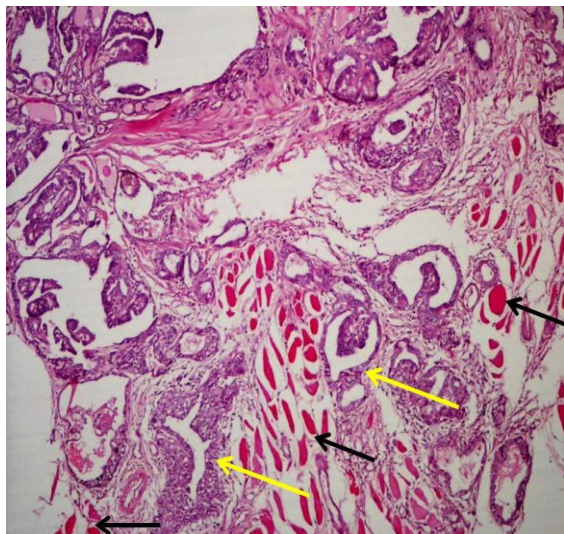


Figure 5: photomicrograph showing Aggregates of lymphocytes(A) , foreign body giant cell reaction(B) and normal thyroid follicles(C) were seen. H&EX 100





**Figure 6: Photomicrograph showing tumor (Yellow arrows) infiltrating into the adjacent skeletal muscle tissue (Black arrows). (H & EX100)**

## DISCUSSION

The thyroglossal duct cyst represents one of the most common causes of anterior midline neck swellings in children. It accounts to around 70 % in children and 7% in adults.<sup>[1]</sup> The incidence of malignant transformation is around 1% of all cases in adults. The development of malignancy is extremely uncommon in children and adolescents and around 26 cases have been reported in English literature. Only around 10 cases have been reported in children aged less than 12 years.<sup>[5]</sup>

The most common presenting symptom in children is the presence of anterior midline neck mass. Clinically it is indistinguishable from TDC. The girls are found to be more commonly affected than boys. The malignancy in TDC can be suspected if there are any recent changes in the swelling, in the form of rapid growth, hard mass, fixed and irregular borders.<sup>[5]</sup> The size of the swelling may vary however the size less than 1 cm has generally a nonthreatening clinical course.<sup>[6]</sup> Regional lymph nodes can be involved. Pfeiffer et al in his study noted lymph node involvement in 50% of pediatric patients.<sup>[4]</sup> This finding is very high as compared to 11% in adults. The malignancy has two origins. The first is from the thyroembryonic remnants resulting in thyrogenic carcinoma and the other is squamous cell carcinoma arising from the metaplastic epithelium of the TDC. Mutations in the genes such as thyroid transcription factor 1 TTF1, TTF2 & PAX 8 are considered as the reasons for causation of thyroglossal duct cancers.<sup>[7]</sup>

The most common malignancy arising in TDC is papillary carcinoma (80%) followed by mixed papillary and follicular (8%) and squamous cell carcinoma (6%). Anaplastic carcinoma is rare. Medullary carcinoma is not reported in TDC till date. Histological typing is important because squamous

cell carcinoma and anaplastic carcinoma carries poor prognosis. The diagnosis of PTC in TDC is most of the times incidental in histopathological examination. It is difficult to diagnose preoperatively unless there is a strong clinical suspicion and ancillary investigations done. Ultrasound and Computerized tomography (CT) scan is an important diagnostic tool in diagnosis of malignancy in suspected swellings. The presence of calcification, lesions with solid parts or multiple septations with irregular boundaries suggests the possibility of malignancy.<sup>[3]</sup>

The role of FNAC in diagnosis of PTC is very limited. The incidence of FNA yielding correct results is only 50-60% of cases.<sup>[8]</sup> The reasons of decreased accuracy is due to the cystic nature of the content, dilution of cells in the fluid and non-representativeness of the aspirate. A diligent search is required to look for malignant cells. The best way to enhance the diagnostic accuracy is aspiration of suspected areas under ultrasound guidance. However this routinely is not done because of not suspecting malignancy routinely in children.

The presence of high cellularity, papillary formations with characteristic nuclear features of grooving and intranuclear inclusions, psammoma bodies are diagnostic cytological features. Hence the final diagnosis is by histopathological examination. Also it is important to differentiate primary carcinoma from metastasis from thyroid. The diagnosis of primary PTC in TDC is by Widstorm criteria which are as follows. 1. Carcinoma should be in the wall of the TDC duct, 2. Demonstration of normal cyst wall lining of either cuboidal/ squamous/ pseudostratified ciliated columnar epithelium, and 3. Absence of malignancy in the thyroid. The third criteria is however controversial as the incidence of incidental PTC in thyroid in cases of TDC carcinoma ranges from 11-45%.<sup>[9]</sup> some researchers believe that the patent TDC can serve as metastatic route from thyroid.

Apart from the above diagnostic features there are few histopathological features in the form of scar formation in the centre of the lesion and tumor infiltrating into the surrounding tissues which favor the diagnosis of primary PTC in TDC. The management of PT in TDC is controversial as numerous doubts have persisted even today. The methods performed are sistrunk procedure, near total/total thyroidectomy with or without neck node dissection, radioiodine ablation and thyroid suppression therapy. Some authors recommend aggressive management involving all the above treatment. If the diagnosis is incidental finding in a TDC, then some authors recommend a close follow up to monitor the signs of future thyroid involvement. However these authors recommended the minimum of local lymph node resection.<sup>[4]</sup>

## CONCLUSION

Papillary carcinoma arising in TDC is extremely rare in children and adolescents. High index of suspicion, supported by relevant investigations are needed to diagnose preoperatively. FNA under imaging guidance can yield better results in preoperative diagnosis. Multidisciplinary approach is must in the management of PTC in TDC in children and adolescents.

**Authors declare no conflict of interest.**

**Acknowledgements:** Nil

## REFERENCES:

1. Tharmabala M, Kanthan R. Incidental thyroid papillary carcinoma in a thyroglossal duct cyst - management dilemmas. *Int J Surg Case Rep.* 2013;4(1):58-61.
2. Chu YC, Han JY, Han HS, Kim JM, Min SK, Kim YM. Primary papillary carcinoma arising in a thyroglossal duct cyst. *Yonsei Med J.* 2002 Jun;43(3):381-4.
3. Suzuki, A, Suzuki, K, Mori, Y, Fujita, Y, Hatano, T et al. Preoperative Diagnosis of Thyroglossal Duct Cancer: A Case Report and Literature Review. *International Journal of Otolaryngology and Head & Neck Surgery* 2015 4, 196-203. doi: 10.4236/ijohns.2015.43033.
4. Pfeiffer MS1, Kim GH2, Krishnan M3. Thyroglossal duct papillary carcinoma in a 15-year old female and review of pediatric cases of thyroglossal duct carcinoma. *Int J Pediatr Otorhinolaryngol.* 2014 Jan;78(1):135-8.
5. Tahir A, Sankar V, Makura Z. Thyroglossal duct cyst carcinoma in child. *J Surg Case Rep.* 2015 Apr 15;2015(4). pii: rjv042. doi: 10.1093/jscr/rjv042.
6. Peretz A, Leiberman E, Kapelushnik J, Hershkovitz E. Thyroglossal duct carcinoma in children: case presentation and review of the literature. *Thyroid.* 2004 Sep;14(9):777-85.
7. Pietruszewska W, Wągrowaska-Danilewicz M, Józefowicz-Korczyńska M. Papillary carcinoma in thyroglossal duct cyst with uninvolved thyroid. Case report and review of the literature. *Arch Med Sci.* 2014 Oct 27;10(5):1061-5.
8. Agarwal K, Puri V, Singh S. Critical appraisal of FNAC in the diagnosis of primary papillary carcinoma arising in thyroglossal cyst: A case report with review of the literature on FNAC and its diagnostic pitfalls. *J Cytol.* 2010 Jan;27(1):22-5.
9. Sobri FB, Ramli M, Sari UN, Umar M, Mudrick DK. Papillary Carcinoma Occurrence in a Thyroglossal Duct Cyst with Synchronous Papillary Thyroid Carcinoma without Cervical Lymph Node Metastasis: Two-Cases Report. *Case Rep Surg.* 2015;2015:872054. doi: 10.1155/2015/872054. Epub 2015 Feb 15.