

CYTOMORPHOLOGY OF RECURRENT BACK SWELLING – ECCRINE SPIRADENOMA

Sily Sreedharan^{1,*}, Geethu G Nair²

^{1,2}Assistant Professor, Department of Pathology, Malabar Medical College, Modakkallur P.O., Atholi, Kozhikode, Kerala- 673315

***Corresponding Author:**

E-mail: silysreedharan@rediffmail.com

ABSTRACT

Eccrine spiradenoma is an uncommon benign adnexal tumour. Though its histopathology is well established, there are only very few case reports describing its cytomorphology. We are reporting one such rare case of recurrent swelling in back. Cytological features were suggestive of benign appendage tumour of eccrine differentiation, possibly eccrine spiradenoma. This case report is being presented for its rare description in the literature.

Keywords: Appendage tumor; Eccrine spiradenoma; Fine needle aspiration

INTRODUCTION

Eccrine spiradenoma is a benign cutaneous adnexal tumour, arising from lower portion of eccrine sweat gland. ^[1, 2] They can occur almost anywhere in the body especially trunk, proximal extremities, head & neck region. These can be very painful lesions. ^[3] Cytological features of this benign lesion have been rarely described because clinicians prefer to resort to excision biopsy than fine needle aspiration cytology studies for diagnosis. A knowledge of cytology findings helps in giving a correct diagnosis of appendage tumours with fine needle aspiration cytology itself.

CASE HISTORY

A 62 year old male, known diabetic & hypertensive presented with recurrent swelling over right lower back since 2 months. On local examination, the nodule was measuring 2x1cm, mobile along one plane. A scar mark was noted over the nodule. No skin puckering or discoloration noted. He also gives past history of undergoing removal of a similar nodule at the same site 1 year back at a local hospital for which no records were available.

With the provisional clinical diagnosis of fibroma, patient was investigated. His routine blood examination was normal. He was sent for Fine Needle Aspiration Cytology (FNAC) to the Department of Pathology. Aspiration was done with 22 gauge needle & 5cc syringe. Aspirate yielded blood tinged granular material. All the smears were alcohol fixed & stained with Papanicolaou (PAP) stain. Cellular aspirates revealed cohesive multilayered clusters of round to oval epithelial cells with few scattered spindle shaped myoepithelial cells (Fig 1). These epithelial cells had scanty cytoplasm, uniform nucleus with inconspicuous nucleoli (Fig 2). Some of the epithelial cells were arranged as pseudo-rosettes with central eosinophilic material in the

lumen (Fig-3). Background showed scattered lymphocytes & blood. Cytomorphological features were consistent with benign eccrine appendage tumour- possibly Eccrine spiradenoma.

Excision of the nodule was done under local anaesthesia & specimen sent for histopathology. Gross examination revealed skin with a nodule measuring 1.5x1x1cm. Cut section was grey white with cystic & myxoid areas. Histopathology revealed a well circumscribed lesion arranged as lobules separated by hyalinised stroma. Cells in the lobules were arranged as intertwining cords (Fig 4). Higher power showed two types of cells, one having small dark nuclei with scanty cytoplasm, other cell has large pale nucleus with inconspicuous nucleoli (Fig 5). Pseudo-rosettes were seen with central hyaline like material. Scattered lymphocytes were also noted within the lobules. Histo-pathological findings were consistent with eccrine spiradenoma. Post-operative period was uneventful & wound healed well on follow up.

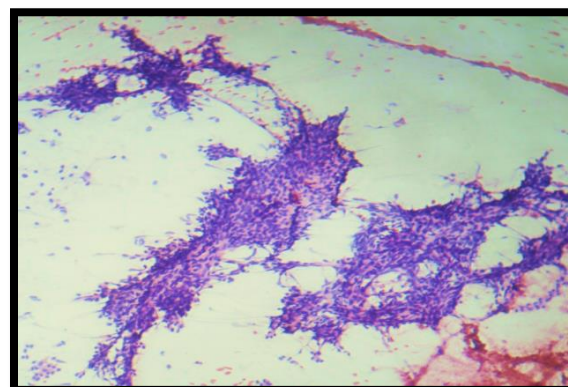


Fig 1: Cytology smear showing multilayered cell clusters Papanicolaou Stain (100X).

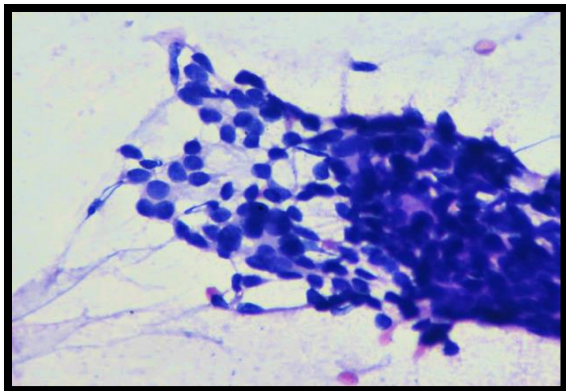


Fig 2: Pap stained smear shows large pale cells, myoepithelial cells & third type of small dark cells (400X).

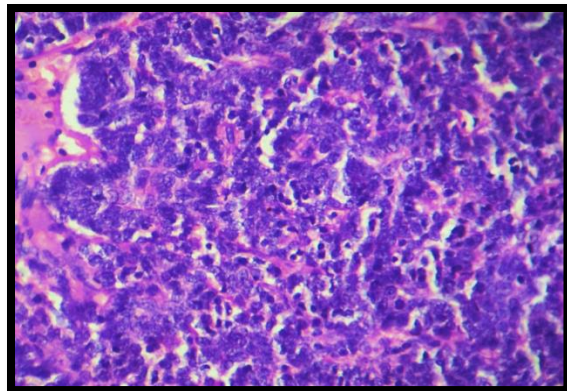


Fig 5: H&E showing lobules composed of pale large cells, smaller dark cells with sprinkling of lymphocytes (400X).

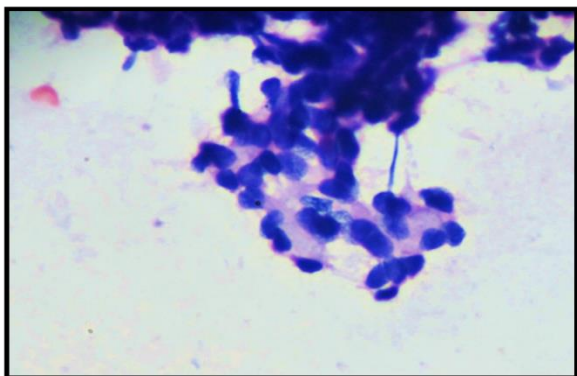


Fig 3: Pap stained smear shows pseudo-rosette formation with hyaline like material in the lumen (400X).

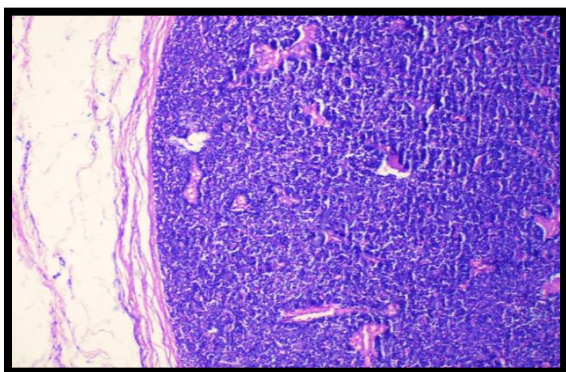


Fig 4: H&E showing circumscribed lobular lesion (100X).

DISCUSSION

Eccrine spiradenoma is a rare benign adnexal tumour arising from the intraductal portion of eccrine sweat gland. [1, 2] It was first described by Sutton in 1934 and extensively described by Kersting et al in 1956. Head and neck is the common location but it may also occur on the trunk [4], as in our case. The lesion is mostly solitary and is one among the painful tumors of the skin. Most of the cases of eccrine spiradenoma are 1-2 cm in size but cases of large size (giant) also have been documented. [3, 4]

Though histopathology of eccrine spiradenomas is well established, diagnostic cytological criteria are still lacking. Very few cases of cytological diagnosis have been reported till date. Cytology of eccrine spiradenoma comprises of tight clusters of multilayered uniform, cuboidal bland epithelial cells arranged surrounding hyalinized material. Tubules and pseudo-rosette formation by epithelial cells along with spindle-shaped myoepithelial cells, many scattered bare nuclei and small lymphocytes are the key components of cytology of eccrine spiradenomas. [1, 2, 5]

Cytologically, eccrine spiradenomas should be differentiated from adenoid cystic carcinoma. Cytology of adenoid cystic carcinoma contains a single type of cells and hyaline globules in contrast to epithelial-myoepithelial-lymphocytic cells in eccrine spiradenomas. [6]

Histologically eccrine spiradenoma composed of lobules of packed neoplastic cells. In higher magnification, two distinct populations of cells are exhibited—peripherally placed darker basaloid cells with hyper chromatic nuclei and larger pale cells with ample of cytoplasm and vesicular nucleus. Stroma intervening the lobules may exhibit edematous or hydropic degeneration with lymphocytic infiltration. [3] The diagnosis of eccrine tumors sometimes cannot be made definitely on cytology or even on histopathology also. In these cases, immunohistochemistry can play an important

role.^[7] Immunohisto-chemically eccrine spiradenomas show cytokeratin (CK) positivity (epithelial marker), carcino embryonic antigen reactivity (tubules) and lymphocytes exhibit T-cell phenotype.

Treatment of Eccrine spiradenoma is surgical excision. Local recurrence is quite uncommon & if it recurs then some degree of cytological atypia is seen in the lesion^[8], which was not seen in our case. Malignant transformation is quiterare.^[9]

CONCLUSION

Knowledge of cytological features of benign adnexal lesions will help in making an exact diagnosis & help in appropriate management of the patient. With the findings of this case, we hope that we were able to lay emphasis on subtle cytological features required for the diagnosis of eccrine spiradenoma.

REFERENCES

1. Pailoor K, Jayaprakash LS, Naik RC, Marla NJ, Fernandes H, Pai MR et al. Chondroid Syringoma & eccrine spiradenoma. *Online J health Allied Sci.* 2011;10:10.
2. Lee H H, Park SH, Choi H Y, Park HK. Eccrine spiradenoma arising in the breast misdiagnosed as an epidermal inclusion cyst. *Korean J Radiol.* 2011;12:256-60.
3. Anuradha Sinha, Subrata Pal & Jyoti Prakash Phukan. FNAC of Eccrine spiradenoma of back: Report of rare case. *J Lab Physicians.* 2014; Jul- Dec:6(2):130-132.
4. Lin O, Zakowski MF. Cytology of soft tissue, bone and skin. In: *Comprehensive Cytopathology.* 3rd edition. Elsevier. P. 471-514.
5. Devanand B, Vadiraj P. Fine needle aspiration cytology of eccrine skin adnexal tumours. *J Cytol Histol.* 2011;2:129.
6. Kolda TF, ArdamanTD, Schwartz MR. Eccrine spiradenoma mimicking adenoid cystic carcinoma on fine needle aspiration. A case report. *Acta Cytol.* 1997;41:852-8.
7. Missall TA, Burkemper NM, Jensen SL, Hurley MY. Immuno-histo-chemical differentiation of four benign eccrine tumors. *J CutanPathol.* 2009;36:190-6.
8. Delfino S, Toto V, Brunetti B, Bianchi A, Baldi A, Persichetti P. Recurrent atypical eccrine spiradenoma of the forehead. *In Vivo.* 2008; Nov-Dec;22(6):821-3.
9. Scheinfeld NS, Tarlow MM, Burgin S. Blaschkoid eccrine spiradenomas. *Cutis.* 2002;70:73-5.