

Fine needle aspiration cytology: A diagnostic tool in evaluation of lymphadenopathy in paediatric age

Komal Sawaimul¹, M. Banyameen Iqbal^{2,*}, Vijayalaxmi Sawaimul³, Tusar Kambale⁴

^{1,3}Assistant Professor, ^{2,4}Associate Professor, ^{1,2,4}Dept. of Pathology, ³Dept. of Orthodontics, ^{1,2,4}Dr. D.Y Patil Medical College, Hospital and Research Centre, Pimpri, Pune, Maharashtra, ³VYWS Medical College, Amravati, India

***Corresponding Author:**

Email: banzey@gmail.com

Received: 22nd November, 2017

Accepted: 08th February, 2018

Abstract

Introduction: Lymphadenopathy is one of the commonest clinical presentations in children and a common scenario for pediatrician. Unexplained lymphadenopathy often poses a great deal of anxiety and concern in parents. Fine needle aspiration cytology (FNAC) is a minimally invasive, cost effective and a well established technique as a high diagnostic efficacy tool. FNAC especially in benign inflammatory condition has aided in clinical practice by avoiding unnecessary excision biopsies also limiting its complications and psychological trauma to patient. The present study was conducted to evaluate FNAC as a diagnostic tool in pediatric lymphadenopathy and study spectrum of various cytomorphological patterns in paediatric age group.

Materials and Methods: The present study was undertaken in the Department of Pathology, in a tertiary care hospital in Maharashtra. Reports of 312 pediatric FNAC (<16years) of various lymph nodes were studied from July 2014 to November 2017 retrospectively.

Results: Maximum number of aspirates were found in 12-16 years (38.78%) i.e older age group and were of benign nature i.e. 96.80% with remaining (3.20%) malignant in nature. Anterior cervical lymph nodes predominate over other lymph nodes (41.02%) followed by posterior cervical lymph nodes (31.40%) when FNAC anatomical site subdivision was done. Maximum number of aspirates were found to be reactive lymphadenitis (61.53%) followed by tuberculous lymphadenitis (8.65 %).

Conclusion: To conclude fine needle aspiration cytology has emerged as a reliable initial screening tool in all the lymphadenopathy cases in pediatric age group due to its cost-effectiveness and high diagnostic accuracy. A spectrum of different lesions can be evaluated by using FNAC. Pediatrician plays a very important role by taking initiative in referring all the pediatric patients for FNAC, in a resource limited settings like India.

Keywords: Fine needle aspiration cytology, Lymphadenopathy, Lymphadenitis.

Introduction

Lymphadenopathy is one of the commonest clinical presentation in children and a common scenario for pediatrician.^{1,2} A Spectrum of diseases and conditions can present as lymphadenopathy.³ Evaluation of a child with lymphadenopathy often pose diagnostic dilemma for the pediatricians as well.⁴ Earliest diagnostic workup is essential in all such cases to reach a final and proper diagnosis.³

Lymph nodes provide ideal first line defense against pathogens, hence most of the normal children have small palpable cervical, axillary and inguinal lymph nodes.² They are considered as enlarged, if their diameter exceeds 1cm for cervical and axillary nodes and more than 1.5 cm for inguinal nodes.⁵

Fine needle aspiration cytology (FNAC) is one of the important diagnostic modality which has emerged as a important tool in evaluation of various superficial and deep masses in pediatric age group.³ A spectrum of different lesions can be evaluated by using FNAC thereby avoiding operative procedure.⁴ FNAC has emerged since decades as a well established technique with rapid diagnosis and minimum intervention.⁴ It is a well-accepted technique by parents and patients which

helps in speedy diagnosis and is also having a high specificity.⁶

The present study was conducted to evaluate FNAC as a diagnostic tool in pediatric lymphadenopathy and study spectrum of various cytomorphological patterns in pediatric age group. Correlation between cytological diagnoses with the histomorphological diagnosis was done as per availability.

Materials and Methods

The present study was undertaken in the Department of Pathology, in a tertiary care hospital in Maharashtra. Reports of 312 pediatric FNAC (<16years) of various lymph nodes were studied retrospectively from July 2014 to November 2017. Cytology smears of all patients were retrieved from departmental records. In all cases cytomorphological features were studied and cytopathologic diagnoses were compared with histopathologic diagnosis wherever it is available.

Results

Total 312 FNAC of lymph nodes are studied in cases falling in the age group <16 years. Inadequate smears were seen in 21 cases, accounting for 6.74%. Subdivision of age range was done in three groups, 0-5 years, 6-11 years and 12-16 years. Maximum numbers

Table 1: Age distribution and FNAC Diagnosis

Age in years	Benign cases	Malignant cases	Total cases	Percentage
0-5	79	3	82	26.28%
6-11	107	2	109	34.94%
12-16	116	5	121	38.78%
Total	302	10	312	100%
Percentage	96.80%	3.20%	100%	

A slight male predominance is noted in our study with a ratio of 1.05:1. The males were 51.28 % as compared to females which were 48.72%. [Table 2]

Table 2: Sex distribution of FNAC cases

Sex	Cases	Percentage
Males	160	51.28
Females	152	48.72
Total	312	100

Anterior cervical lymph nodes predominate over other lymph nodes (41.02%) followed by posterior cervical lymph nodes (31.40%) with least number of cases seen in Supraclavicular lymph nodes (0.32%) when FNAC anatomical site subdivision was done. [Table 3]

Table 3: Anatomic sites of LYMPH nodes aspirated

Site	Number of cases	Percentage
Anterior Cervical	128	41.02%
Posterior Cervical	98	31.40%
Submandibular	15	4.80%
Submental	06	1.95%
Post auricular	14	4.48%
Occipital	04	1.30%
Supraclavicular	01	0.32%
Cervical (group not specified)	14	4.48%
More than one group	24	7.70%
Axillary	05	1.60%
Inguinal	03	0.96%
Total	312	100%

Maximum number of aspirates was found to be reactive lymphadenitis (61.53%) followed by tuberculous lymphadenitis (8.65%) granulomatous lymphadenitis (7.70%) acute suppurative lymphadenitis (6.42%) and acute necrotizing lymphadenitis (5.76%). [Table 4]

of aspirates were found in 12-16 years (38.78%) i.e. elder age groups then the younger ones. Maximum number of aspirates were of benign nature i.e. 96.80% and the remaining i.e. 3.20% were malignant. [Table 1]

Table 4: Cytologic diagnosis of lymphadenopathy

Diagnosis	No. of cases	Percentage
Reactive Lymphadenitis	192	61.53%
Tuberculous Lymphadenitis	27	8.65%
Acute suppurative Lymphadenitis	20	7.70%
Necrotising Lymphadenitis	18	6.42%
Granulomatous Lymphadenitis	24	5.76%
Malignancy (Lymphomas)	6	1.92%
Metastasis	3	0.96%
Positive for malignancy	1	0.32%
Inadequate	21	6.74%
Total	312	100%

10 aspirates were positive for malignancy (3.20%) with maximum cases of lymphomas. Sub typing of lymphoma showed one case of Burkitts lymphoma and other of Hodgkin's lymphoma [Table 5]. Cervical region predominance was seen in lymphoma cases as well. Monomorphic population of lymphoid cells was noted on cytology in all lymphomas. One case which had presented as a supraclavicular lymphadenopathy showed prominent vacuoles on cytology and subtyped as Burkitts lymphoma on cytology.

Correlation between cytological and histopathologic diagnosis was available in only 51 /312 cases (6.34%) [Table 5]. Maximum number of diagnosis were inflammatory lesions which usually disappear after a short antibiotic therapy, hence they were probably not subjected to any surgical excision or biopsy. Most of these patients were followed up in the out-patient department for a period of 6 months to check for any recurrence.

Table 5: Cytomorphological and histopathological diagnosis correlation

Cytology		Histopathology	
Cytomorphological Diagnosis	No. of Cases	Histopathologic Diagnosis	No. of cases
Tuberculous lymphadenitis	18	Tuberculous lymphadenitis	18
Reactive Lymphadenitis	24	Reactive Lymphadenitis	23
Inadequate/insufficient aspirates	5	Tuberculous lymphadenitis	1
		Reactive Lymphadenitis	4
		Tuberculous lymphadenitis	1
Lymphomas	3	Non Hodgkins lymphoma	2
		Hodgkins lymphoma	1
Metastasis	1	RMS (metastasis)	1
Necrotising lymphadenitis	1	Tuberculous lymphadenitis	1
Granulomatous lymphadenitis	1	Tuberculous lymphadenitis	1
Total	51		51

Table 6: Comparison of various studies on FNAC in pediatric age group

	M Jain et al., ⁹	Mitra P et.al., ¹¹	Handa U et al., ¹⁰	Amy Rapackwiz et al., ⁸	Present study
No. of pediatric cases studied	748 cases	100	692 cases	85 cases	312
Age range	0–12 years	0–15	0–14 years	0–18 years	0-16
Adequacy of Material	94%	93%	93.4%		93.26%
Age preponderance		10–15 years	6–10 years		12-16
Sex preponderance		Male 55%	M:F ratio 1.5:1	Male [69.4%]	Male 51.28%
Cervical lymphadenopathy cases (commonest lesion)	81%	87%	84.3%	69.4%	89.74%
Benign aspirates	98.5%	88.17%	98.46%	83%	96.80%
Malignant aspirates	1.5%	11.83%	1.54%	17%	3.20%

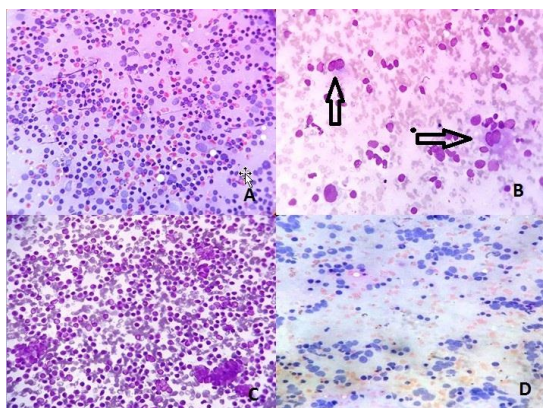


Fig. 1: Photomicrograph showing polymorphous population of lymphoid cells in a case of reactive lymphadenitis (A). Photomicrograph with Reed Sternberg Cells (RS Cell) (B). Photomicrograph showing monomorphic lymphoid cell population (C). Photomicrograph showing Metastatic deposits from round cell carcinoma in lymph node (D)

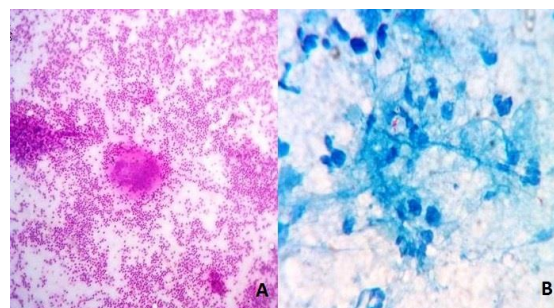


Fig. 2: Photomicrograph of an epithelioid cell granuloma (A). Photomicrograph of Acid Fast Bacilli (AFB) on ZN staining (B)

Discussion

Initially FNAC was used as a diagnostic tool in adult patients for evaluation of different lesions. However, as FNAC showed high accuracy and rapidity it was also used in few pediatric cases as an established diagnostic tool with low complications. The FNAC

aspirates in present study are from various lymph nodes and includes spectrum of cytomorphological diagnosis. Various investigators have done studies in pediatrics age group, revealed similar results as were found in present study.

Unsatisfactory aspirates were shown to be 6-8% in various studies with material adequacy falling in the range of 93-94%.⁹⁻¹¹ Material adequacy was found to be 93.26% while inadequate/ unsatisfactory FNAC aspirate was found in 6.74% cases, comparing well with findings in other studies. [Table 6]

In a study by Mitra et al.,¹¹ and Maheshwari et al.,¹² maximum number of cases (40.82%) were 10-15 years and 11-14 years of age group respectively. Maximum number of cases in present study was found in the age group of 12-16 years accounting for 38.78%, correlating well with above mentioned studies.

Male preponderance was noted in 51.28% while male to female ratio was 1.05:1. In all above mentioned studies males predominate over females.^{8,10,11}

Majority of the cases were of benign nature (96.80%) while remaining 3.20% cases were malignant. This is in accordance with various other studies done.⁹⁻¹¹

FNAC diagnosis based on anatomical site subdivision revealed anterior cervical lymph node preponderance, over all other lymph nodes (41.02%), with least number of aspirates from the supraclavicular lymph node (0.32%). Correlating well with studies done by Steel et al.,⁴ Handa et al.,¹⁰ Multiple lymph node involvement was seen in 7.69%.

Pratima et al.¹³ study showed cervical lymph node as the commonest site for FNAC accounting for 48.3%. Reactive lymphadenitis followed by acute suppurative lesion was the most common lesions among non-neoplastic lesions, accounting for 38.8% and 16.22% respectively. Other lesions in cervical lymph node include granulomatous lymphadenitis accounting for 10.7%, and tubercular lymphadenitis accounting for 10.1%. Study done by Annam et al.,¹⁴ showed that maximum number of cases were reactive lymphadenitis 58.08%, this was followed by granulomatous lymphadenitis cases and tubercular lymphadenitis cases accounting for 30.55% and 29.01% respectively.¹⁴ Other study showing similar results with non-specific reactive hyperplasia as dominant pattern was done by Hag et al.⁶ Hence all results correlating well with present study.

Localized lymphadenopathy constituted nearly 92.31% while generalized lymphadenopathy comprised of 7.69%. This is in correspondence with the study done by Tilak et al.¹⁵

Cytological diagnosis and there histopathological correlation was available in only 51/312 (16.34%). Majority of the diagnosis in our study are inflammatory lesions which usually disappear after a proper antibiotic therapy thereby avoiding there surgical excision. The cytomorphological and histopathological findings are

found to be concordant in 45/51 cases with accuracy rate of 88.23%. One case was diagnosed as reactive lymphadenitis on cytology showed tuberculous lymphadenitis on histopathology. Out of total 5 cases which showed inadequate aspirate on cytomorphological diagnosis 4 cases were diagnosed as reactive lymphadenitis and one case as tubercular lymphadenitis. Similarly one case each of granulomatous lymphadenitis and necrotizing lymphadenitis were finally confirmed as tuberculous lymphadenitis on histopathology.

In Mohan et al.,¹⁶ study comparison between cytological and histopathological diagnosis were available in only 8.33% cases; with a concordance in cytomorphological findings and histopathological diagnosis in 88.89% cases while discrepancy in 11.11% cases.¹⁶ Prathima et al.,¹³ showed concordant results in 81.6% cases with cyto-histopathological correlation in 9.4% cases.

Conclusion

Fine needle aspiration cytology (FNAC) is one of the important diagnostic modality and has emerged as a reliable initial screening tool in all the lymphadenopathy cases in pediatric age group due to its cost-effectiveness and high diagnostic accuracy. A spectrum of different lesions can be evaluated by using FNAC. It is a well-accepted technique by parents and patients which helps in speedy diagnosis with minimum intervention.

Since commonest clinical presentation in paediatric population is reactive lymphadenitis, surgical excision is usually not indicated as this tends to resolve on its own or resolves with proper antibiotic treatment. FNAC especially in benign inflammatory condition has aided in clinical practice by avoiding unnecessary excision biopsies also limiting its complications and psychological trauma to patient. Proper and prior planning with rational use of surgery /treatment can be done in few suspicious cases where histopathological examination is mandatory. Also histopathology is mandatory where a clear cut distinction between benign and malignant lesions is needed.

Initial screening of all pediatric patients presenting with lymphadenopathy be done by FNAC considering its diagnostic efficacy and cost effectiveness. Pediatrician plays a very important role by taking initiative in referring all the pediatric patients for FNAC, in a resource limited settings like India.

References

1. Kelly CS, Kelly RE Jr. Lymphadenopathy in children. *Pediatr Clin N Am.* 1998;45:875-888.
2. Lymphadenitis and Lymphangitis. In: *Case Based Pediatrics for Medical Students and Residents.* New York: Churchill Livingstone. 2003:34.

3. Saad RS, Singh HK, Silverman FJ. Fine needle aspiration cytology. In: Orell SR, Sterett GF, editors. *Pediatric Tumors*. 5th ed. New Delhi: Churchill Livingstone Elsevier Ltd; 2012. pp. 445–67.
4. Steel BL, Schwartz MR, Ibrahim R. Fine needle aspiration biopsy in diagnosis of lymphadenopathy in 1,103 patients *Acta Cytologica* 1995 39:76-81.
5. Chesney P. Cervical Adenopathy. *Pediatrics in Review*. 1994;15:276-284.
6. el Hag IA, Chiedozi LC, al Reyees FA, Kollur SM. Fine needle aspiration cytology of head and neck masses. Sevenyears' experience in a secondary care hospital *Acta Cytol* 2003 47:387-92.
7. Cohen MB, Bottles K, Ablin AR, et al: The use of fine-needle aspiration biopsy in children. *West J Med* 1989 Jun;150:665-66.
8. Rapkiewicz Amy, Bich Thuy Le, Aylin Simsir, Joan Cangiarella, Pascale Levine, *Cancer Cytopathol* 2007 111:242-51.
9. Jain M, Majumdar DD, Agarwal K, FNAC as a diagnostic tool in Pediatric head and neck lesions *Indian J of paediatrics* 1999 36:921-23.
10. Handa U, Mohan H, Bal A, Role of fine needle aspiration cytology in evaluation of pediatric lymphadenopathy *Cytopathology* 2003 14:66-69.
11. Mitra P, Bharti R, Pandey MK. Role of fine needle aspiration cytology in head and neck lesions of Pediatric age group. *Journal of Clinical and Diagnostic research*.2013 June Vol-7(6):1055-1058.
12. Maheshwari V, Alam K, Jain A, Agarwal S, Chana RS. Diagnostic utility of fine needle aspiration cytology in pediatric tumors. *J Cytol*. 2008;25:45–9.
13. S Prathima, TN Suresh, ML Harendra Kumar, J Krishnappa. Fine needle aspiration cytology in pediatric age group with special references to pediatric tumors: A retrospective study evaluating its diagnostic role and efficacy. *Ann Med Health Sci Res*. 2014 Jan-Feb;4(1):44-47.
14. Annam V, Kulkarni MH, Puranik RB. Clinicopathologic profile of significant cervical lymphadenopathy in children aged 1-12 years. *Acta Cytol*. 2009;53:174–8.
15. Tilak V, Dhaded AV, Jain R. Fine needle aspiration cytology of head and neck masses. *Indian J Pathol Microbiol*. 2002;45:23–29.
16. Mohan A, Jain RK, Thakral RK. Cytomorphological spectrum of pediatric head and neck lesions – a comparative study in a tertiary teaching hospital in Western Uttar Pradesh, India. *Indian Journal of Pathology and Oncology*, July-Sept2016;3(3):450-55.