

Soft tissue metastasis of renal cell carcinoma: A case report

Sujitha J.¹, Leena D Joseph^{2,*}, J. C. Bose³, P. Prithviraj⁴, Sathish Srinivasan⁵

¹Student, ²Professor, ³Professor & HOD, ⁴Medical Officer, ⁵Professor, ^{1,2}Dept. of Pathology, ^{3,4}Dept. of Surgical Oncology, ⁵Dept. of Radiation Oncology, Sri Ramachandra Medical College, Tamil Nadu, India

***Corresponding Author:**

Email: leenadj@gmail.com

Abstract

Renal cell carcinoma (RCC) is the most common primary renal malignant neoplasm in adults, accounting for 90% of renal tumours and 2% of all adult malignancies. Distant metastasis has been reported commonly to bone, lung, abdomen, brain etc. Soft tissue and skeletal muscle metastasis is rare. This is the case of a 59 year old female, who presented with a left lower chest wall mass, which was proven to be a metastatic deposit from a clear cell RCC. The rare presentation in skeletal muscle should be suspected, which should also be differentiated from a benign soft tissue tumour.

Keywords: Chest wall, Metastasis, RCC, Skeletal muscle.

Received: 20th August, 2017

Accepted: 09th October, 2017

Introduction

Renal cell carcinoma has a widespread and very unpredictable metastatic potential, even after a nephrectomy. Its metastatic potential most commonly extends to lungs, lymphnodes, bones, liver, and brain.¹ In few autopsy series, approximately 0.4% of cases with skeletal muscle metastasis have been reported.² Skeletal muscle metastasis is very rare and unpredictable. Hence diagnosis of this condition at this site becomes difficult.

Case Report

A 59 year old female patient presented to the OPD of the oncology unit with complaints of pain over the hip region. She is a known diabetic and hypertensive on regular medication. She is postmenopausal with no significant family or personal history.

On examination she was anaemic with a HB value of 6.9 gms/dl. There was no icterus, cyanosis, clubbing, lymphadenopathy, pedal edema or thyromegaly. Her cardiovascular and respiratory system examination did not reveal any abnormalities. There was a swelling in the lower lateral chest wall which was firm in consistency and measured approximately 4cm in greatest dimension.

A biopsy was taken and send to Pathology department. The two linear cores of soft tissue had been processed and microscopy showed fibrocollagenous tissue infiltrated by sheets of atypical clear cells, some of which were arranged in a papillary pattern, with moderate

pleomorphism and hyperchromatic nuclei (Fig.1,2).

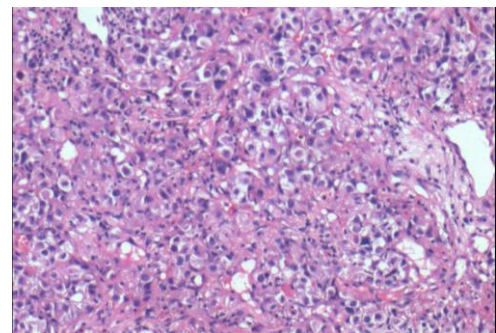


Fig 1: Sheets of tumor cells with moderate amount of clear cytoplasm, pleomorphic hyperchromatic nuclei, loss of polarity, many atypical mitosis (H & E 200X LPF)

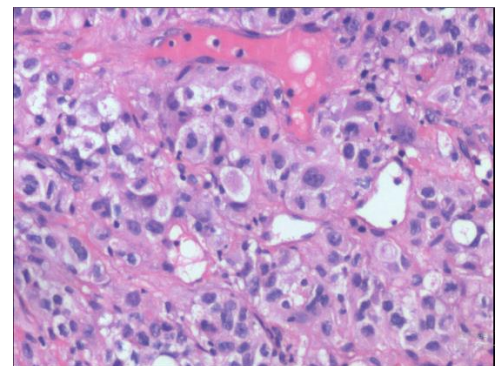


Fig. 2: Tumor cells with well defined cell border, moderate clear to eosinophilic cytoplasm, irregular nuclear membrane, hyperchromatic nuclei. (H & E 400X HPF)

The patient gave a history of radical nephrectomy, following which she received few cycles of chemotherapy. With the previous history of renal cell carcinoma and nephrectomy, the diagnosis of metastatic deposit from a clear cell RCC was given on histopathology. Four cycles of radiation were given and inj. Erythropoietin 10,000 units weekly thrice was given subcutaneously for correction of the anaemia, Sunitinib was planned after a gap of 2 weeks.

Discussion

Renal cell carcinoma is the most common primary renal malignant neoplasm in adults and accounts for approximately 90% of renal tumours which makes upto 2% of all adult malignancies. Solitary metastasis develops in 1/3rd of cases of RCC, which is normally localised at the time of initial diagnosis. The most common sites of distant metastasis are lungs (50%), lymphnodes (35%), liver (30%), bone (30%) and adrenal gland (5%). Skeletal muscle metastasis is usually a very rare phenomenon.

RCC is reported to have a widespread and unpredictable metastatic potential, inspite of a curative nephrectomy. Late recurrence is very unusual presentation of this tumour. In a study of Mc Nichols's,³ 11% of metastatic RCC cases occurred more than 10yrs after the initial diagnosis, even after total resection. The protease inhibitors in the extracellular muscle matrix is considered to result in the invasion by tumour enzymes. Muscle contractions also dislodge the tumour cells, and the acidic conditions within the muscle is also said to contribute to the inhibition of metastatic growth within the skeletal muscle. Tograll et al also described solitary large masses in the gluteus maximus and medius muscles in two patients, who had a history of renal cell carcinoma and treated with nephrectomy⁵ Unusual features on MRI helped in identifying the metastatic deposit in the Sartorius muscle, as an initial presentation in a 48 years old man, who presented with a right thigh swelling.⁶ Biopsy finding of a tumour with clear cells and the characteristic architecture helps in the differential diagnosis.

Making a diagnosis of metastatic RCC to the skeletal muscle is very challenging, because the differential diagnosis is a soft tissue tumour. It is important to differentiate the two, as aggressive surgical resection is necessary for metastatic RCC, but not for benign soft tissue tumour. RCC is characterised by high signal intensity in T1

and T2 weighted images, which helps to differentiate it from primary soft tissue tumours.⁷

Conclusion

Renal cell carcinoma has the potential for distant metastasis, many years after nephrectomy. Rare sites of metastasis, like skeletal muscle, should be considered in the differentials of a soft tissue setting, with a known history of RCC. Biopsy finding of a clear cell lesion should also arouse the suspicion of a clear cell RCC metastasis.

References

1. Holland JM, Proceedings: Cancer Of The Kidney- Natural History And Staging. Cancer 1973;32:1030.
2. Nabeyama R, Tanaka K, Matsuda S, Iwamoto Y. Multiple Intramuscular Metastasis 15 Yrs After Radical Nephrectomy In A Patient With A Stage 4 Rcc. J Orthop Sci 2001;6:189-92.
3. McNichols Dw, Segura Jw, De Weerd Jh. Renal Cell Carcinoma : Long Term Survival And Late Recurrence. J Urol. 1981;126:17-23.
4. Merimsky O, Levine T, Caitechik S. Recurrent Solitary Metastasis Of Renal Cell Carcinoma In Skeletal Muscles. Tumori 1990;76:407-9.
5. Guray Tograll, Murat arikan, safakgungor. Rare skeletal muscle metastasis after radical nephrectomy for renal cell carcinoma: evaluation of two cases. Journal of surgical case reports 2014; doi:10.1093/jscr/rjul01
6. Paraj S Birud, Rohit Singh, PritiBhirud, SharadKankalia. Thigh metastasis of renal cell carcinoma masquerading as soft tissue sarcoma: A Role of MRI. Medical journal of Dr DY Patel University, 2014;7:195-7.
7. Akio Sakamoto, Taksuya Yoshida, Suguru Matsuura, Kazuhiro Tanaka, et all. 2007; doi>1186/1477- 7819- 5-88.