

A dynamic approach to gynaecomastia

K. Anji Reddy¹, G. Vahini^{2,*}

¹Director & Plastic Surgeon, Dept. of Plastic Surgery, ²Associate Professor, Dept. of Pathology, Asram Medical College, Eluru, Andhra Pradesh, India

***Corresponding Author:**

Email: gudelivahini@yahoo.co.in

Abstract

Introduction: Gynaecomastia is characterized by enlargement of the male breast, caused by glandular proliferation and fat deposition. Although a fairly common presentation in the primary care setting and is mostly of benign etiology, it can cause patient considerable anxiety. Sometimes it could be due to serious underlying illness or a medication or inherited. Breast cancer risk is slightly higher in males with gynaecomastia.

Aim: To determine the prevalence, pathophysiology, etiology and therapy of gynaecomastia. A stepwise approach that includes imaging and laboratory testing to exclude neoplasms and endocrinopathies.

Materials and Methods: A one year prospective study of twenty four gynaecomastia cases was done. A detailed clinical history taken and physical examination was done. Laboratory investigations like hepatic, renal and thyroid function tests, hormonal levels like serum estradiol, testosterone, follicular stimulating & luteinizing hormone levels, prolactin, human chorionic gonadotropin and dehydroepiandrosterone levels were done. Other investigating aids like MRI and ultrasonography, mammography, cytogenetics were useful in some of them. However, histopathology proved to be gold standard.

Results: We had twenty four cases of gynaecomastia of which there were one case of Klinefelter syndrome, five cases each of idiopathic gynaecomastia, two case each of true hermaphroditism, one case each of androgen insensitivity syndrome, Ehlers danlos syndrome, cirrhosis, drug induced, renal failure, hyperthyroidism, testicular torsion, androgen insensitivity syndrome, choriocarcinoma, pituitary adenoma, adrenal neoplasm and Leydig cell tumour. Six cases were those of physiological gynaecomastia.

Conclusions: Gynaecomastia is a common condition that may be attributable to an oestrogen /androgen imbalance caused by several etiological factors. After confirming the diagnosis, searching for a specific cause and classifying the case according to severity grade, the therapy for gynaecomastia should be personalized. Lifestyle guidance, reassurance, medical treatment and surgical correction are valid tailored therapeutic options.

Keywords: Approach, Breast, Gynaecomastia, Male.

Received: 29th July, 2017

Accepted: 31st August, 2017

Introduction

Gynaecomastia (GM) is characterized by enlargement of the male breast, caused by glandular proliferation and fat deposition.^{1,2} Occurs in adolescents, adults and in old age.³ A hormonal imbalance between estrogens and androgens is the key hallmark. Breast cancer risk is slightly higher in males with GM. In true gynecomastia a disc of firm tissue, concentric with nipple-areolar complex is felt. Pseudogynecomastia does not show mound resistance of this nature, and no firm tissue. Breast cancer there is hard or firm eccentric located mass from the nipple associated with skin dimpling, nipple retraction or discharge and axillary lymphadenopathy. Sonography findings of gynecomastia include hypoechoic retroareolar masses (nodular, poorly defined or flame shaped) with increased anteroposterior depth at the nipple.⁴

The aim of the present study is to determine the incidence of gynecomastia at our hospital and

discuss the pathophysiology, etiology, evaluation and therapy. Classify GM into severity grades and to guide the treatment. Classification of gynecomastia into severity grades is done by Cordova and Moschella which takes into account different relationships between structural component of the breast, in particular the inframammary fold and nipple-areolar complex (NAC), which is the watershed between mild forms and serious forms.⁵

Materials and Methods

A prospective study of twenty four cases presenting with gynecomastia was conducted over a period of one year. History and physical examination was taken. Suspected breast mass (hard, eccentric) mammography, image guided or surgical biopsy was done. Palpable scrotal mass performed testicular ultrasound. Hormone testing (total and bioavailable testosterone, estradiol, prolactin, luteinizing hormone, human chorionic gonadotrophin) were done. In case of

raised HCG performed testicular ultrasound to rule out testicular germ cell tumour and if normal findings then evaluated for extragonadal germ cell tumours (bronchogenic, hepatic, renal), Non trophoblastic HCG-secreting tumours. Those cases of raised prolactin with or without testosterone and normal or low LH performed MRI of the head. To rule out pituitary adenoma,

empty Sella or mass panhypopituitarism. In case of raised estradiol and normal to low luteinizing hormone we performed testicular ultrasound to rule out Leydig / Sertoli cell tumour. In case of normal findings performed CT abdomen to rule out adrenal neoplasm. All the patients underwent percutaneous biopsy.

Results

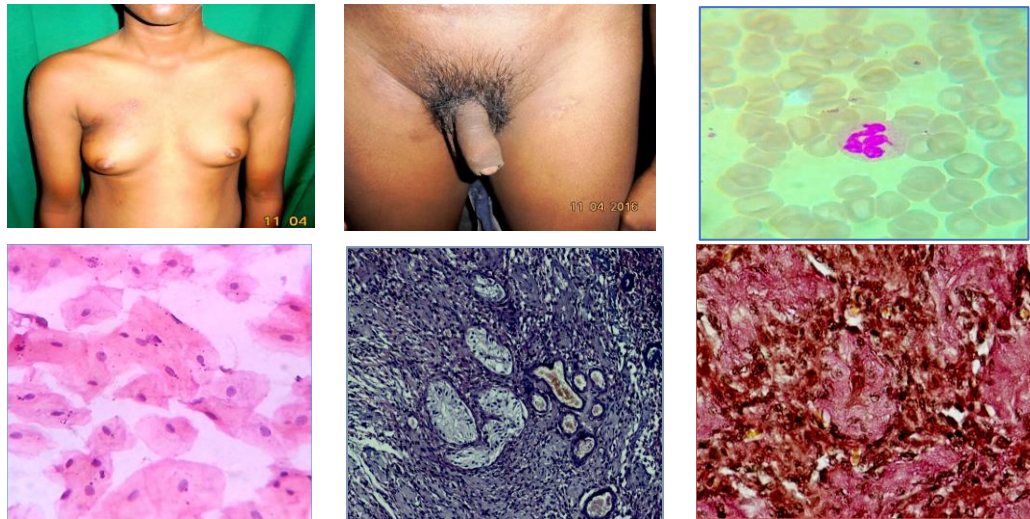


Plate 1: Klinefelters Syndrome: Fig. 1: Gynecomastia; Fig. 2: Penial hypospadias; Fig. 3&4: Barr body positive in peripheral smear and buccal smear; Fig. 5: Leydig cell hyperplasia in H&E stain; Fig. 6: Vangeison stain

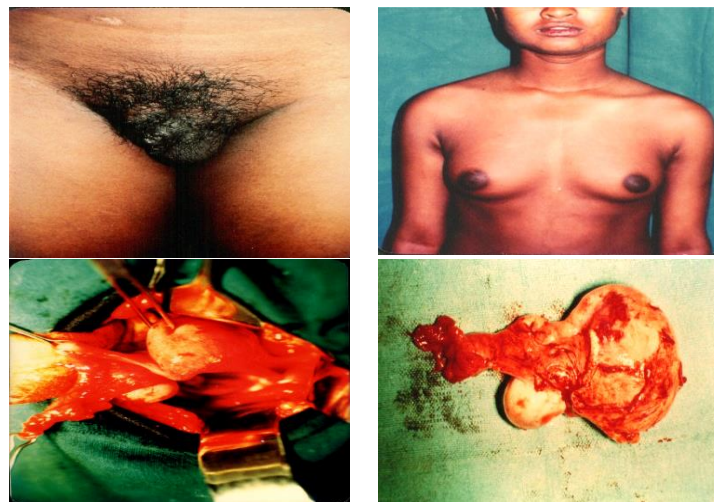


Plate 2: True Hermaphroditism: Fig. 7: Perineal hypospadias; Fig. 8: Gynecomastia; Fig. 9&10: Right sided adnexae removal

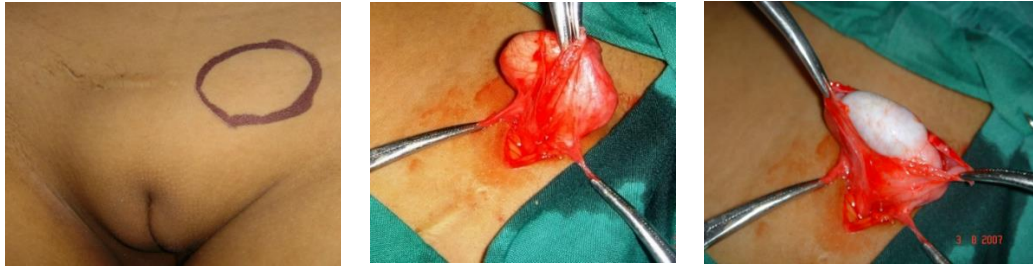


Plate 3: Androgen Insensitivity Syndrome: Fig. 11: Left sided inguinal hernia; Fig. 12&13: Removal of the hernia

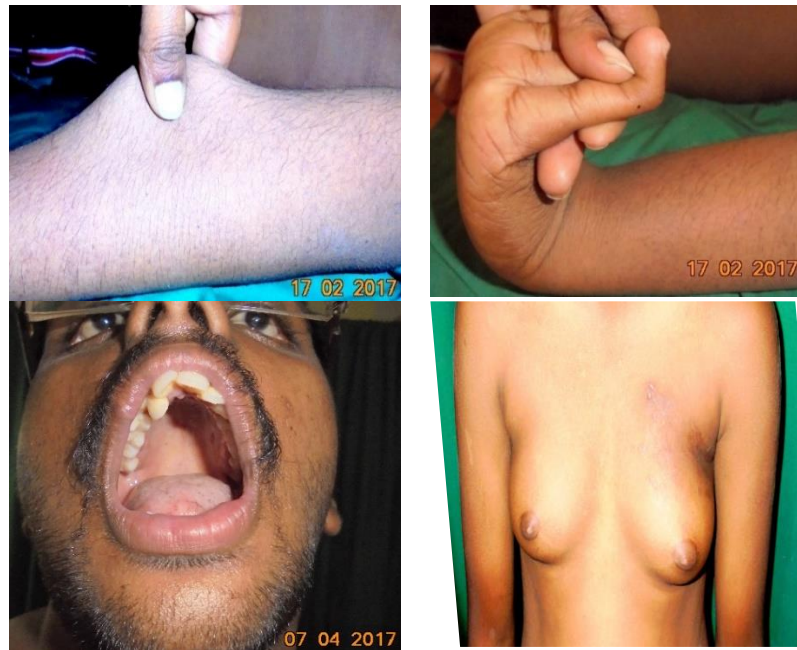


Plate 4: Ehlers Danlos Syndrome: Fig. 14: Laxity of skin; Fig. 15: Hyperextensibility of joints; Fig. 16: High arched palate; Fig. 17: Tension of interphalangeal joint

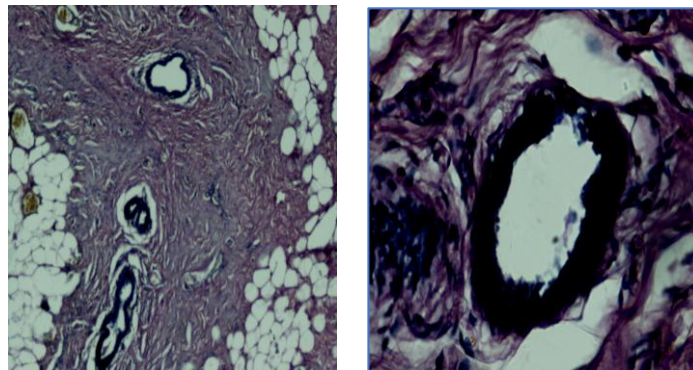


Plate 5: Fig. 18: HPE X 10, X 40. Predominance of fibrous connective tissue with characteristic halo effect around duct

There were twenty four cases of gynaecomastia. We had one case of Klinefelters syndrome, two cases of True hermaphroditism, one case of Ehlers Danlos syndrome, one case of Androgen insensitivity syndrome, five cases of Idiopathic gynaecomastia, one drug induced, one case of Leydig cell tumour, six cases of Physiological gynaecomastia, one case of

Testicular torsion, one case of Ulcerative colitis, one case of Pituitary adenoma, one case each of Cirrhosis, Kidney failure and Choriocarcinoma. All our cases were bilateral in presentation. Age of the patient ranged from 1 to 45 years. Most common age group of presentation 20 to 35 years. Classification gynaecomastia by Cordova and Moschell we had 90% of cases grade IV and

remaining 10% of cases grade III. Microscopically all these of GM were characterised by proliferation of the ductules, without terminal acini in fibroconnective stroma. In early phase onset stage (florid phase), there was extensive ductal hyperplasia, over time glandular elements became less prominent and fibrosis became the main finding.

Discussion

Asymptomatic gynecomastia is very common and has trimodal age distribution, occurring in neonatal, pubertal, and elderly males. In our study it is 70% of the cases. The prevalence of asymptomatic gynecomastia is 60% to 90% in neonates, 50% to 60% in adolescents, and up to 70% in men aged 50 to 69 years. The prevalence of symptomatic is markedly low in other studies including our study (30%). Gynecomastia is clinically bilateral in approximately half of the patients.⁶ In our study, all the cases (100%) were bilateral. Nipple discharge is very uncommon.⁶

We had one case of True hermaphrodite where sixteen years old male came with complains of gynecomastia, colicky pain lower abdomen once in 2-3 months lasting for four days last 3 years. Was operated for perineal hypospadias in childhood. Born to nonconsanguineous parents with normal siblings. On examination, external genitalia were underdeveloped. Buccal smear was positive for sex chromatin. Laparoscopy showed normal uterus with right side adnexa, No attachment on left side. Testicular biopsy showed testicular atrophy and no spermatogenesis.

Chromosomal study revealed mixoplasty of 46xx/46xy with predominant of 46xx cell line (95%). Conventional stains shows no chromosomal abnormalities. Laparotomy was performed.

Hysterectomy with salpingoophorectomy done. Operative findings showed dark colored blood and a loop of ileum was adherent to posterior surface of uterus. Bowel resection was done and end to end anastomosis performed. True hermaphrodite known as ovotesticular disorder of sex development is a medical term for an intersex condition in which an individual is born with ovarian and testicular tissue. External genitalia are ambiguous, the degree depending mainly on the amount of testosterone tissue. Karyotype is 47XXY, 46XX/46XY or 46XX/46XY, 46XX/47XXY, varying degree of mosaicism. An ovum fertilised is by 2 sperms or 2 ova fertilised by 2 sperms will fuse to formation of tetragametic chimera or one male

zygote and one female zygote fuse. It can be associated with mutation in SRY gene.⁷

Pseudohermaphroditism in which a person is born with primary sex characteristics of one sex but develops the secondary sex characteristics that are different from what would be expected on the basis of the gonadal tissue (ovary or testis). Male pseudohermaphrodite when testis is present and female pseudohermaphrodite when ovary is present. We had a two cases of male pseudo hermaphrodite. Male pseudo hermaphroditism with Morris syndrome (testicular-feminization) is often associated with normal female breast appearance due to gonadal oestrogen production.²²

We also had a case of Klinefelter syndrome. A 16year old male complains of gynecomastia, lack of facial hair (no moustache & beard), reduced pubic hair & axillary hair, abnormally tall, small testis, positive barr body in buccal smear and peripheral smear. Klinefelter syndrome is a chromosomal disorder (47XXY) associated with hypogonadism and infertility; gynecomastia is seen in 70% of cases. The reason why extrapresence of an X chromosome is linked to gynecomastia is unclear. There is 50-fold higher risk of developing breast cancer among men than among men in the general population.^{8,9}

There was a case of 22 years patient with Ehlers Danlos syndrome. Patient complained of hyperextensibility of the wrist and elbow joint, laxity of the skin, high arched palate, gynecomastia, birth asphyxia, delayed milestones. Walking at 3 years and toilet training at 3-4 years. Patient had general gross hypotonia, floppy child syndrome, cerebral palsy, bilateral Erbs palsy with kyphosis and congenital dislocation of both shoulders. First product of consanguineous couple. Colour doppler study of venous system of left lower limb –deep venous thrombosis involving displaced branch of left femoral vein.

There was 15 years female with androgen resistance syndrome. Not attained menarche. Appeared as female with shallow vagina and breast development, but has no uterus, very little axillary and pubic hair. Was operated in childhood for swelling in right inguinal region. Now presented with swelling in left inguinal region which was reducible. At puberty breasts develop as female. No menarche and could not become fertile. Testosterone levels, Luteinizing hormone (LH), Follicle stimulating hormone (FSH) were low. Sex chromatin was negative, Karyotyping--XY and Pelvic ultrasound showed absence of uterus and ovaries. Androgen resistance syndromes due to impaired activity of

enzymes involved in the biosynthesis of testosterone can be associated with gynecomastia.¹⁰ Left inguinal swelling operated and Indirect Inguinal hernia with testis in the sac was excised. The imbalance between the oestrogen action relative to androgen action at the breast tissue is the cause of gynecomastia.

Although testicular tumours are rare, approximately 10% of patients with testicular tumour present with gynecomastia. In a study of 175 men who were referred to a breast surgeon for evaluation of gynecomastia, a testicular tumour was diagnosed in 3 percent. The elevated oestrogen levels may be a result of oestrogen secreting neoplasms or their precursors like Leydig or Sertoli cell tumours, human chorionic producing tumours and more commonly caused by increased conversion of androgen to oestrogens by tissue aromatase.¹¹ We had a single case of 36 years old male with Leydig cell tumour and 33 year old with choriocarcinoma. Gynecomastia occurs in 10 to 40 percent of men with hyperthyroidism although it is rarely the only symptom at presentation. Pituitary adenomas producing prolactin (prolactinomas) induce gynecomastia. Also there is a case of 28 years old with Pituitary adenoma and hyperthyroidism presenting with gynecomastia.¹²

HCG secreting tumours of ectopic origin (Carcinoma of lungs, liver, stomach and kidney).¹³⁻¹⁶ Chief sex hormone abnormalities in liver cirrhosis are decreased serum testosterone levels and increased oestradiol levels. Increased secretion of androgenic hormone androstenedione from the adrenal glands and increased conversion of this hormone into oestrogen, increased levels of Sex hormone binding globulin which leads to decreased blood levels of free testosterone. We had a case of 34 years old with cirrhosis presenting with gynecomastia.

Men with chronic renal failure are hypogonadal with defects in testicular steroidogenesis. Diuretic spironolactone, which is a competitive antagonist of aldosterone. Inhibits testosterone production in the testes, enhances the aromatization of testosterone to oestradiol and binds to androgen receptors in some tissues, having antiandrogen effect.^{17,18} We have a case of chronic renal failure in 40 years old male and a case of spironolactone induced gynecomastia in 45 years male. The mechanism is oestrogen like activities, stimulation of testicular production of oestrogens, Inhibition of testosterone synthesis or blockade of androgen action.

We had five cases of idiopathic gynecomastia. Multiple endocrine disruptors are

the cause.²² Pubertal GM appear at 13 to 14 years of age, last for 6-12 months and then regress spontaneously in 95% of the cases.¹⁹

Older men over the age of 65 years often present relative hypogonadism with decline in plasma testosterone levels, elevation of Sex hormone binding globulin and decrease in free testosterone.²⁰

Surgery was the mainstay of treatment for those patients who didn't respond to therapy. Surgical excision or liposuction or both. In most cases, considering that fibrous and fatty tissues need to be removed, the best results are achieved by combining liposuction and mammary adenectomy.²¹

Conclusion

Analysis of our twenty four cases as per histopathology examination revealed varying underlying causes. Though gynecomastia is a common condition, the patients that are usually investigated are young. Associated with causes related to elevated estrogen levels. Reports suggest that gynecomastia along with genetic abnormality has higher risk of developing carcinoma. Investigating aids like ultrasonography, mammography, MRI and cytogenetics were useful in some of them.

References

1. Niewoehner, CB; Schorer, AE (March 2008). "Gynecomastia and breast cancer in men". *BMJ*. 336(7646):709-13.
2. Shulman, DI; Francis, GL, Palmert, MR, Eugster, EA; Lawson Wilkins Pediatric Endocrine Society Drug and Therapeutics Committee (April 2008). "Use of aromatase inhibitors in children and adolescents with disorders of growth and adolescent development." *Pediatrics*. 121(4):e975-983. doi:10.1542/peds.2007-2081. PMID 18381525.
3. Narula HS, Carlson HE (August 2014). "Gynecomastia-pathophysiology, diagnosis and treatment". *Nat Rev Endocrinol*. 10(11):684-698. doi:10.1038/nrendo.2014.139. PMID 25112235.
4. Dialani V, Baum J, Mehta TS. Sonographic features of gynecomastia. *Ultrasound Med*. 2010;29(4):539-47.
5. Cordova A, Moschella F. Algorithm for clinical evaluation and surgical treatment of gynecomastia. *J Plast Reconstr Aesthet Surg*. 2008;61(1):41-9.
6. Braunstein GD. Clinical practice. Gynecomastia. *N Engl J Med*. 2007;357(12):1229-37.
7. Lee P. A., Houk C. P., Ahmed S. F., Hughes I. A.; Houk; Ahmed; Hughes (2006). "Consensus statement on management of intersex disorders".

- Pediatrics. 118 (2): e488–500. PMID 16882788.
doi:10.1542/peds.2006-0738. CS1 maint:
Multiple names: authors list
8. Narula HS, Carlson HE. Gynaecomastia. *Endocrinol Metab.Clin North Am.*2007;36(2):497-519.
 9. Lanfranco F, Kamischke A, Zitzmann M, Nieschlag E. Klinefelter's syndrome. *Lancet.*2004;364(9430):273-83.
 10. Braunstein GD. Gynecomastia. *N Engl J Med.*1993;328(7):490-5. Pearlman G, Carlson HE. Gynaecomastia: an update. *The endocrinologist.*2006;16(2):109-15.
 11. Pearlman G, Carlson HE. Gynaecomastia : an update. *The endocrinologist.*2006;16(2):109-15.
 12. Braunstein GD. Enviroment gynecomastia. *Endocr Prac.*2008;14(9):409-11.
 13. Narula HS, Carlson HE. Gynaecomastia. *Endocrinol Metab Clin North Am.*2007;36(2):497-519.
 14. Thompson DF, Carter JR. Drug-induced gynecomastia. *Pharmacotherapy.*1993;13(1):37-45.
 15. Ismail AA, Barth JH. Endocrinology of gynecomastia. *Ann Cln Biochem.*2001;38(pt 6):596-607
 16. Johnson RE, Murad MH. Gynaecomastia: pathophysiology, evaluation and management. *Mayo Clin Proc.*2009;84(11):1010-5.
 17. Eckman A, Dobs A. Drug – induced gynecomastia. *Expert Opin Drug Saf.*2008;7(6):691-702.
 18. Goldman RD. Drug-induced gynecomastia in children and adolescents. *Can Fam Physician.*2010; 56(4):344-5.
 19. Mazur T, Clopper RR. Pubertal disorders .Psychological and clinical management. *Endocrinol Metab Clin North Am.*1991;20(1):211-30.
 20. Harman SM, Metter EJ, Tobin JD, et al .Longitudinal effects of aging on serum total and free testosterone levels in healthy men. Baltimore Longitudinal Study of Aging. *J Clin Endocrinol Metab.*2001;86(2):724-31.
 21. Laituri CA, Garey CL, Ostlie DJ, et al. Treatment of adolescent gynecomastia. *J Pediatr Surg.*2010;45(3):650-4.
 22. Braunstein GD. Gynecomastia. *N Engl J Med.*1993;328(7):490-5.
 23. Couillard C, Gagon J, Bergeron J, et al. Contribution of body fatness and adipose tissue distribution to age variation in plasma steroid hormone concentrations in men: the HERITAGE family study. *J Clin Endocrinol Metab.*2000;85:1026-31.

Abbreviations: GM-Gynaecomastia, HCG-Human chorionic gonadotropin.