

Epidemiology of neoplastic eyelid lesions in tertiary care hospital

Sushma TA¹, Geethamani V², Thejaswini MU^{3,*}, Suguna BV⁴, Dharani VC⁵

^{1,3}Associate Professor, ²Professor & Head, ⁵Assistant Professor, Dept. of Pathology, BGS Global Institute of Medical Sciences, Bengaluru, Karnataka, ⁴Professor & Head, Dept. of Pathology, Kempegowda Institute of Medical Sciences, Bengaluru, Karnataka, India

***Corresponding Author:**

Email: thejaswinimu@gmail.com

Abstract

Introduction: Lesions from cutaneous portion of eyelid account for the considerable number of ocular specimens sent to the histopathology laboratory for evaluation. Wide spectrum of lesions ranging from non-neoplastic to neoplastic lesions can arise from different tissues of eyelid.

Aim: The aim of our study was to categorise the Neoplastic lesions, evaluate the prevalence of tumors and to compare with epidemiological data.

Materials and Methods: Retrospective analysis of 774 consecutive cases of Eyelid tumors over a period of 5 years was carried out in tertiary health care system through histopathological confirmation.

Results: A total of 774 eyelid tumors consisted of 718 Benign lesions (92.76%) and 56 Malignant lesions (7.24%). Benign tumors were common in the fifth decade with female predominance affecting upper eyelid. Maximum number of Benign tumors were 318(44.28%) cases of Cystic lesions followed by 135(18.8%) Melanocytic lesions and 126(17.54%) cases of Epithelial proliferations. Malignant tumors were predominant in seventh decade with female preponderance and preference for lower eyelid. Sebaceous gland carcinoma 24(42.85%) was the commonest malignant tumor followed by 18(32.14%) Basal cell carcinoma, 5(8.92%) Squamous cell carcinomas and 4(7.14%) cases of Malignant melanomas. An interesting case of Squamous cell carcinoma arising from Pilomatricoma was also seen. Rare tumors noted were 3 cases of Keratoacanthoma and one each case of Merkel cell carcinoma and Non-Hodgkin's lymphoma.

Conclusion: Benign tumors comprise majority of eyelid tumors. A high index of suspicion for malignant lesion will enable the patients for early diagnosis and management with the better prognosis of these tumors.

Keywords: Basal cell carcinoma, Malignant melanoma, Pilomatricoma, Sebaceous gland carcinoma, Squamous cell carcinoma.

Received: 12th September, 2017

Accepted: 08th February, 2018

Introduction

Eyelid comprises of diverse histological structures and contribute to a variety of non-neoplastic and neoplastic lesions of epithelial, adnexal, vascular, neural, histiocytic and melanocytic origin. Eyelids are often involved in various systemic diseases like thyroid ophthalmopathy, sarcoidosis and lymphoproliferative diseases.^{1,2} Most of these lesions present as lumps to clinician and histopathological study is required to confirm the diagnosis. Eyelid tumors represent 15% of the face tumors and 5-10% of all the cutaneous tumors.³ Literature search has revealed variable prevalence of benign and malignant tumors in different geographical locations. Our study is aimed at categorising various neoplastic eyelid lesions to assess the prevalence of primary eyelid tumors and to compare the results with those reported in other countries across the world.

Materials and Methods

We accomplished a retrospective analysis of eyelid tumors from a tertiary care hospital over a period of 5 years from 2011-2015. A computerised retrieval system was used to collect data of all patients who underwent eyelid mass excisions and histopathological examination was made for the same tissue. Patients age, gender, topography of the tumor was documented. All Benign and Malignant eyelid tumors were included in the study. All Congenital lesions, Canthal lesions, Conjunctival lesions, Involutional changes and Systemic diseases affecting the eyelids were excluded from the study.

The biological material comprised of 774 neoplastic eyelid lesions presenting as eyelid lumps. All these materials were processed according to the standard protocol of processing of ocular tissue. Routine Haematoxylin and Eosin staining was done. Special stains were used as and when required. Immunohistochemistry was carried out whenever

necessary. All the eyelid lesions encountered in the study were classified into distinct categories (Figure 1) and analysed (Table 1 & 2).⁴ The data collected were entered to Microsoft excel worksheet and then subjected to descriptive statistical tabulation.

Results

During the 5-year interval, a total of 4770 ocular specimens was sent for histopathological analysis. Among them, 774 neoplastic eyelid lesions comprised of 16.22% of total ocular biopsy samples. A wide spectrum of Benign 718 cases (92.76%) and Malignant tumors 56 cases (7.24%) were encountered.

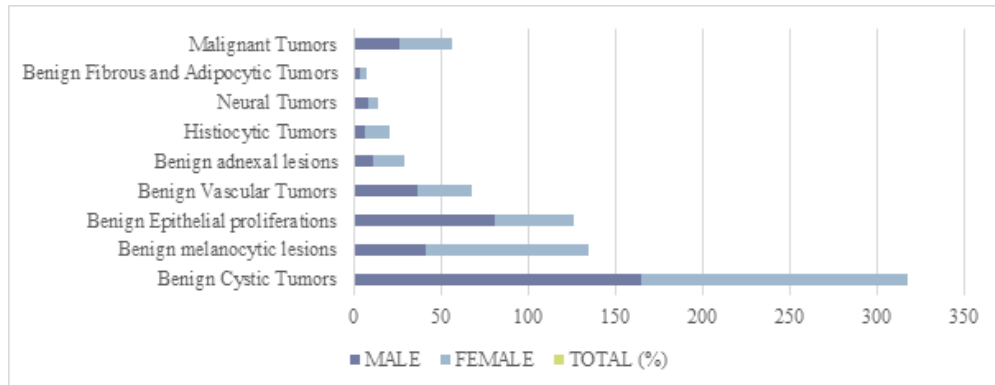


Fig. 1: Distribution of various categories of neoplastic eyelid tumors according to the gender

Benign Tumors

Patients age ranged from 1 year to 89 years. Majority of the Benign tumors were seen in fifth decade (Figure 2). Regarding the gender, 365 (50.84%) Benign tumors were found in females and 353 (49.16%) cases in males. Right eyelid (367 cases) was more frequently involved than left eye (351 cases). Bilateral involvement was seen in 43 cases. Upper eyelid (390 cases) was more commonly involved than the lower lid lesions (328 cases).

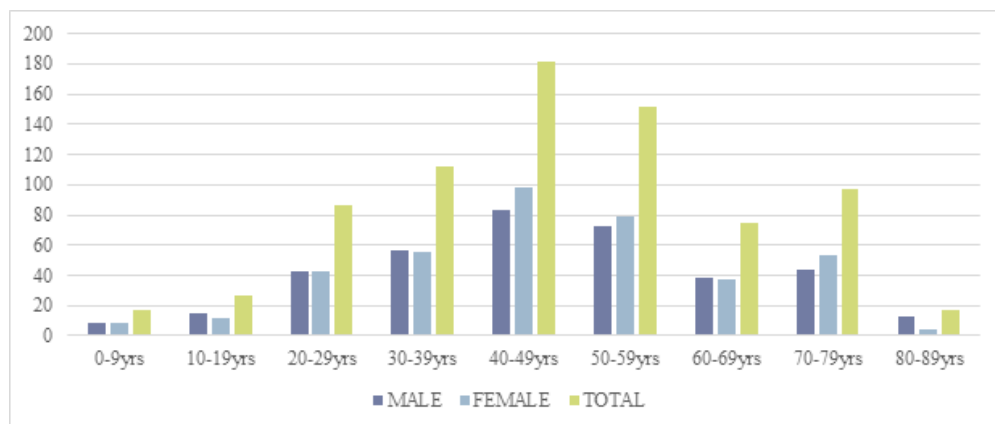


Fig. 2: Distribution of Neoplastic Eyelid lesions in various age groups

The Cystic eyelid tumor formed the bulk of benign tumor constituting 318 (44.28%) cases. It affected almost all age groups from 2 years to 87 years. Histopathological analysis revealed Epidermal cyst 144 (20.05%), Sebaceous cysts 95 (13.23%), Hidrocystoma 73 (10.16%), Zeiss gland cyst 3 (0.42%), parasitic cyst in 2 (0.28%) and a case of trichilemmal cyst (0.14%). Epidermal cyst was common in the fifth decade affecting left eyelid predominantly in males.

In the category of Benign melanocytic tumors, Intradermal nevus represented 118 (16.43%) cases. It was seen more often in females in the fifth decade in the right lower eyelid. Other melanocytic lesions reported were 15 (2.09%) cases of compound nevi, of which 4 cases (0.55%) had junctional activity. Two cases of epidermal nevi were also found.

Among the category of Benign Epithelial proliferations, Squamous papilloma 91(12.67%) was the most frequently encountered lesion. It showed a bimodal peak distribution in 4th and 6th decade of life. There was a slight preference to right eyelid. Most cases were seen in males. Lesions like fibroepithelial polyp or acrochordons/skin tags were also included under this group. Other significant lesions encountered in this category were 24 cases of seborrheic keratosis and 11 cases of inverted follicular keratosis.

Among the Adnexal lesions, 9(1.25%) cases of Sebaceous gland hyperplasia of oil gland origin, 3(0.42%) cases of Pilomatricoma of hair follicle origin and 5 (0.7%) cases of pleomorphic adenoma/Chondroid syringoma of sweat gland origin were some of the lesions encountered together accounting for 4.03% cases.

Among the soft tissue tumors, Pyogenic granulomas 39(5.43%) and Vascular hemangiomas 28(3.92%) were the commonest lesion. Neural lesions frequently occurred were 11(1.54%) cases of Neurofibroma and 3(0.42%) cases of neurilemmoma. Xanthelasma with 21(2.92%) cases contributed to considerable number of histiocytic lesions, which predominantly affected females. The rest of the benign lesions in the order of frequencies are shown in Table 1.

Table 1: Prevalence of Various Benign Eyelid Lesions (n=718)

Benign tumors	Males	Females	Total	Percentage
BENIGN CYSTIC EPITHELIAL LESIONS			318	44.28%
Epidermal Cyst	76	68	144	20.05%
Sebaceous Cyst	48	47	95	13.23%
Hidrocystoma – Apocrine/ Eccrine	39	34	73	10.16%
Cysts of Zeiss	01	02	3	0.42%
Parasitic Cyst	0	02	2	0.28%
Trichilemmal Cyst	01	0	1	0.14%
MELANOCYtic LESIONS			135	18.8%
Intradermal Nevi	37	81	118	16.43%
Compound Nevi	2	9	11	1.54%
Compound Nevi with Junctional Activity	01	03	04	0.55%
Epidermal nevi	01	01	02	0.28%
BENIGN EPITHELIAL PROLIFERATIONS			126	17.54%
Squamous Papilloma	60	31	91	12.67%
Seborrheic Keratosis	15	9	24	3.33%
Inverted Follicular Keratosis	6	5	11	1.54%
BENIGN ADNEXAL LESIONS			29	4.03%
a) SEBACEOUS GLAND LESIONS			14	1.94%
Sebaceous Gland Hyperplasia	06	03	9	1.25%
Sebaceous Adenoma	01	03	4	0.55%
Nevus Sebaceous of Jadassohn	0	01	1	0.14%
b) LESIONS OF HAIR FOLLICLE ORIGIN			5	0.69%
Pilomatricoma	0	3	3	0.42%
Trichilemmoma	0	1	1	0.14%
Trichoepithelioma	0	1	1	0.14%
c) LESIONS OF SWEAT GLAND ORIGIN			10	1.4%
Pleomorphic Adenoma	2	3	5	0.7%
Nodular Hidradenoma	1	2	3	0.42%
Eccrine Spiradenoma	0	1	1	0.14%
Hidroacanthoma Simplex	1	0	1	0.14%
VASCULAR TUMORS			68	9.49%
Pyogenic Granuloma	21	18	39	5.43%

Hemangiomas	16	12	28	3.92%
Angiokeratoma	0	1	1	0.14%
HISTIOCYTIC LESIONS			21	2.92%
Xanthelasma	06	15	21	2.92%
NEURAL LESIONS			14	1.96%
Neurofibroma	7	3	10	1.4%
Neurilemmoma	0	3	3	0.42%
Plexiform Neurofibroma	1	0	1	0.14%
FIBROUS AND ADIPOCYTIC LESIONS			7	0.98%
Fibroma	01	02	3	0.42%
Lipoma	02	01	3	0.42%
Fibrous Histiocytoma	1	0	1	0.14%

Malignant tumors

In this study, 56(7.24%) cases of Malignant tumors were reported. The most common eyelid malignancy was Sebaceous gland carcinoma 24(42.85%), followed by 18(32.14%) Basal cell carcinoma, 5(8.92%) Squamous cell carcinomas and 4(7.14%) Melanoma cases. The peak incidence of malignant tumors was in seventh decade followed by sixth decade (Fig. 2). Out of 56 malignant tumors, 30 were females and 26 were males. Thirty-three malignant tumors were on the right eye and twenty-two cases were on left eye. A case of keratoacanthoma affected bilaterally. Majority of the lesions were on the lower lids.

Sebaceous gland carcinoma (SGC) showed female preponderance involving 16 females and 8 males. The age group ranged from 33years to 77years. The mean age at diagnosis was 59.9 years. Upper eyelid was commonly involved than lower eyelid. Right eyelids were more frequently affected than the left. Majority of the lesions (22/24) were reported to be well differentiated tumor with polygonal cells having abundant vacuolated cytoplasm (Fig. 3). Two cases showed features of poorly differentiated SGC.

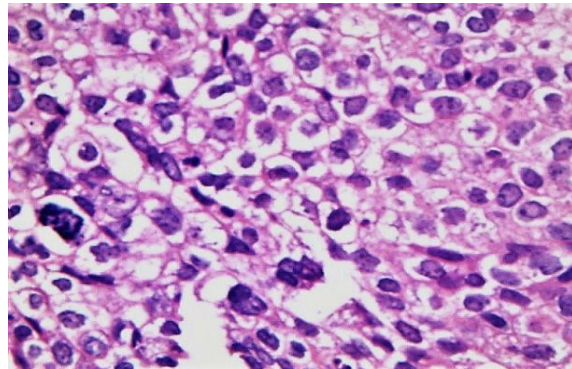


Fig. 3: Sebaceous gland carcinoma showing nests of tumor cells with abundant clear vacuolated cytoplasm (40x)

In our study, Basal Cell Carcinoma (BCC) and its variants were the second common malignant tumor. BCC showed predilection for males and were equally distributed in both the eyes. The mean age at diagnosis was 62.8 years. Among 18 cases of BCC, two each case of Baso-Squamous cell type (Fig. 4) and Pigmented variant of BCC were recognised. Baso-Squamous cell variants were seen in males aged 70 and 72 years.

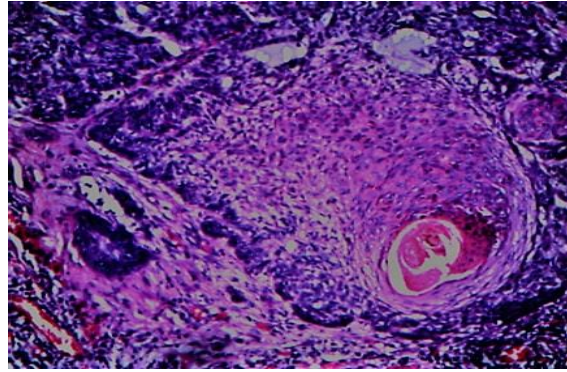


Fig. 4: Baso-Squamous cell carcinoma showing proliferation of basaloid cells with squamoid differentiation and keratinisation in the centre (10x)

Out of 5 cases of Squamous cell carcinoma (SCC), 3 were reported in males in the age group of 65-80 years. Two cases occurred in 65-year-old females. There was a preference for right eyelid involvement. A case of SCC was identified in a pre-existing Pilomatrixoma in a 65-year-old male patient.

Out of 4 cases of Malignant melanoma (MM) reported, 3 were seen in males and a case was reported in 58-year-old female. Right eyelid was preferentially affected than the left eyelid.

Out of 3(5.35%) cases of Keratoacanthoma (KA), one case was seen affecting both the eyelids (Figure 5). Other 2 cases were seen one on each side. An interesting case of Merkel cell tumor (MC) was reported in a 45-year-old female as a nodule on left eyelid. A case of Non-Hodgkin's Lymphoma was also reported in a 67-year-old female, which presented clinically as an abscess in left eyelid.

Table 2: Prevalence of Malignant Eyelid Lesions (n=56).

Malignant tumors	Males	Females	Total	Percentage
Sebaceous Gland Carcinoma	08	16	24	42.85%
Basal cell carcinoma	10	08	18	32.14%
Squamous cell carcinoma	03	02	5	8.92%
Melanoma	03	01	4	7.14%
Keratoacanthoma	02	01	3	5.35%
Merkel Cell Carcinoma	0	01	1	1.8%
Non-Hodgkin's Lymphoma	0	01	1	1.8%

Discussion

Our study is one of the largest local case series describing the histopathological spectrum, epidemiology and frequency of eyelid tumors in referred patients. This data reflects the evidence of point prevalence of histologically proven eyelid tumors in our setting.

Prevalence rate of neoplastic eyelid lesions vary according to the geographic location due to the differences in skin types, sunlight exposure, disease awareness and surveillance practices. Majority of the studies have shown that prevalence rate of benign tumors outnumbered malignant tumors. Benign tumors (718 cases) accounted for a much larger percentage 92.76% than the malignant tumors (7.24%; 56 cases) which was comparable to the study by Huang YY et al study from Taipei.⁵ Table 3 shows prevalence rate of neoplastic eyelid tumors in studies reported in various countries.

Table 3: Prevalence of Benign and Malignant Eyelid tumors by different studies

Eyelid tumors	Obata H et al (2005) ⁷	Mondal SK et al (2008) ⁸	Sanjay CC et al (2009) ⁹	Coroi MC et al (2010) ³	Paul S et al (2011) ¹⁰	Shaikh IY et al (2012) ¹¹	Mary Ho et al (2013) ⁶	Ramya et al (2014) ¹²	Huang YY et al (2015) ⁵	Present study (2017)
Benign (%)	73	60	79	45.8	75.9	78.1	86	52.3	95	92.76
Malignant (%)	27	40	21	54.2	24.1	21.9	14	47.7	5	7.24

Although, there is statistical variation in mean age at diagnosis of neoplastic eyelid tumors. Majority of the benign eyelid lesions occurred in relatively younger age group in the range of 40-49 years. Malignant tumors were common in age group of 60-69 years which correlated with the study found in Singapore, Taiwan, Japan, Hong Kong and Romania.^{6,3}

Overall Sex distribution of benign eyelid tumors revealed 353(49.16%) males and 365(50.84%) females, the findings were in close correlation with the study by Al-Faky YH et al, which also showed a preponderance in females.¹³ Our study showed 53.57% of females with malignant tumors (30 cases). Similar Indian study by Sathish MK et al showed a female preponderance of 56.28% in a study of 85 malignant eyelid tumors.¹⁴

The topographic analysis in our study showed that majority of benign eyelid tumors affected upper eyelid and malignant tumors occurred on lower lid. This was concordant with the data available in literature and studies by Coroi et al, Wang et al and Mary H et al.^{3,15,6}

In this study, wide spectrum of benign eyelid tumors was identified. Eyelid cystic lesions accounted for highest number 318(44.28%) of cases. Obata H et al, found Intradermal Nevus was the most common

Benign lesion in a total of 288 eyelid lesions.⁷ Epidermal cyst constituted 20.05% (144 cases) which correlated with the study by Gupta S et al of 22.91% and Hsu and Lin et al of 23.1%.^{16,13} While Farhat F et al showed a rate of 26.66%.²

Intradermal nevi accounted for 16.43% of eyelid tumors. Chauhan et al reported an incidence of 12.2%, while Ramya et al reported 20% of intradermal nevus.^{9,12} Our study also had 15 cases of compound nevi, 4 with junctional activity.

Our study reported 12.67% of Squamous papilloma. While, Kersten et al and Ni Z et al reported a higher rate of 43.9% and 27.9% respectively.^{13,3} In our study, Hemangiomas accounted for 3.92% cases which was concordant with the study by Mondal et al and Mary Ho et al.^{8,6} Chauhan et al reported a higher incidence of 7%.⁹

Our study included few adnexal lesions, of which 5(0.7%) were Benign mixed tumor/Chondroid tumor which correlated with the study by Mary Ho et al.⁶ We had 3(0.42%) cases of Pilomatricoma in our study. Similar studies reported varying range of 0.6% to 4%.^{6,17}

Table 4 gives a comparative analysis of various malignancies in different geographical locations.

Table 4: Percentage Distribution of Various Malignant Eyelid tumors in different studies

Eyelid lesions	Jahagirdhar et al (2007) ¹⁸	Kumar R et al (2008) ¹⁹	Coroi MC et al (2010) ³	Farhat F et al (2010) ²	Satish M et al (2012) ¹⁴	Mary Ho et al (2013) ⁶	Ramya et al (2014) ¹²	Huang YY et al (2015) ⁵	Gupta Y et al (2017) ¹	Present study (2017)
SGC	37	28.6	19.6	14.94	31.2	7.1	41.4	21.1	52.1	42.85
BCC	44.5	28.6	72.55	56.32	48.2	42.9	26.8	57.8	10.41	32.14
SCC	14.8	38.1	1.96	20.69	13.7	17.9	21.9	10.1	12.5	8.92
MM	-	4.7	5.89	1	-	7.1	2.4	3.5	10.41	7.14
KA	-	-	-	-	-	-	-	-	-	5.35
MC	-	-	-	1	-	-	-	-	-	1.8

NHL	-	-	-	1	-	3.6	-	-	-	1.8
Others	3.7	-	-	5	6.9	21.4	7.5	7.5	14.57	-

SGC of the eyelid is relatively common in Asians. Our study revealed SGC as the most common malignancy accounting for 42.85% cases which correlated with Asian study by Bastola et al (41.7%).²⁰ While Indian study by Jahagirdar SS et al observed 37% of SGC.¹⁸ Chinese cohort study by Beijing et al reported higher rate of 39%.⁶ SGC occurred in large age range of 33-79 years with mean age at diagnosis was 59.9 years. Wang JK et al reported a mean age of 68.1 years with age range of 48-91 years.¹⁵ There was a gender predilection for females which predominantly affected right upper eyelid. The findings correlated with study by Mary Ho et al and Wang JK et al.^{6,15} This justifies the fact that upper eyelids have increased number of Meibomian glands. SGC are potentially lethal, aggressive tumors with recurrence rate of 6-29% and hence high degree of suspicion is of paramount importance especially in Asian population.

In contrast to SGC, BCC is still the commonest cancer of eyelid reported in western literature, accounting for 80-90% of all eyelid cancers. Our study showed BCC as the second commonest tumor accounting for 32.14% cases. This difference in incidence rate explains that along with geographical factors, genetic and racial factors plays a role in cancer physiology.^{3,5} In our study, BCC was predominantly seen in males with predilection for right lower eyelid and mean age of 62.8 years (age range 43-84). Wang JK et al also reported a mean age of 61.8 years (range 48-91) and preferential involvement of lower eyelid.¹⁵ While Coroi et al reported mean age of 68.9 years with range group of 28.7-91.3 years.³

SCC accounted for 8.92% cases which correlated with study by Huang et al.⁵ Sathish et al reported a much higher prevalence of 13.7%.¹⁴ Malignant melanoma accounted for 7.1% tumors in study by Mary Ho et al⁶ which correlated with our present study of 7.14% cases. While another study by Beijing Xu et al and Lin et al showed prevalence of 4% and 2% respectively.⁶ An interesting case of Merkel cell carcinoma (MC) reported in our study correlated with the study by Fouzia F et al.²

Conclusion

Eyelid being heterogenous tissue, encompasses a wide spectrum of neoplastic tumors. Most of these lesions cause irritative symptoms and are not vision threatening. They

are of cosmetic concern and are excised frequently. Timely management of malignant lesions will improve the patient outcome. In our study, Eyelid cystic tumors comprised of most overwhelming cases of Benign eyelid tumors followed by melanocytic lesions. Sebaceous gland carcinoma was commoner than basal cell carcinoma which emphasises the role of climate and geographic locations in the prevalence trends of malignant tumors more so in the Asian population. This study has allowed us a unique opportunity to study the spectrum of eyelid tumors in the referral centre.

Acknowledgement

Our sincere thanks and gratitude to the Directors of Narayana Nethralaya Hospital, Bangalore and Laboratory staff for their support and co-operation.

References

- Gupta Y, Gahine R, Hussain N, Memon MJ. Clinico-Pathological spectrum of ophthalmic lesions: An experience in tertiary care hospital of Central India. *Journal of Clinical and Diagnostic Research* 2017;11:
- Fouzia Farhat, Qamar Jamal, Mahmood Saeed, Zia Ghaffar. Evaluation of Eyelid Lesions at a Tertiary Care Hospital, Jinnah Postgraduate Medical Centre (JPMC), Karachi. *Pak J Ophthalmol* 2010;26(2):83-6.
- Mihaela-Cristiana Coroi, Elena Rosca, Gabriela Mutiu, T. Coroi, Marinela Bonta. Eyelid tumors: histopathological and clinical study performed in County Hospital of Oradea between 2000-2007. *Romanian Journal of Morphology and Embryology* 2010;51(1):111-5.
- Jay Justin Older. *Eyelid Tumors-Clinical Diagnosis and Surgical Treatment. Tumors and Related Conditions.* Manson publishing Ltd.2003.
- Huang YY, Liang WH, Tsai CC, Kao SC, Yu WK, Kau HC, Liu JL. Comparison of the clinical characteristics and outcome of Benign and Malignant Eyelid Tumors: An analysis of 4521 Eyelid tumors in a Tertiary Medical Centre. *Bio Med Research International*.2015.
- Mary Ho, David TL Liu, Kelvin KL Chong, HK Ng, Dennis SC Lam. Eyelid tumors and pseudotumors in Hong Kong: a ten-year experience. *Hong Kong Med Journal* 2013; 19:150-5.
- Obata H, Aoki Y, Kubota S, Kabuki N, Tisuru T. Incidence of benign and malignant lesion of eyelid and conjunctival tumors. *Nippon Ganka Gakkai Zasshi.* 2005;109(9):573-79.
- Mondal SK, Dutta TK. Cytohistological study of eyelid lesions and pitfalls in fine needle aspiration cytology. *Journal of Cytology* 2008;25(4):133-7.
- Chauhan SC, Shan SJ, Patel AB, Rathod HK, Surve SD, Nasit JG, A histopathological study of

- ophthalmic lesions at a teaching hospital. National J Medical Research 2012;2:133-6.
10. Sean Paul, Dat TVo, RonaZ, Silkiss. Malignant and benign eyelid lesions in San Francisco: Study of a diverse urban population. American Journal of Clinical Medicine. Winter2011;8(1).
 11. Sheikh IY, Shah FR, Gandhi MB, Shan CK, Shah NR, Ophthalmic neoplastic lesions. A retrospective study of 4 years. Gujarat Medical Journal.2012;67(2):53-7.
 12. Ramya BS, Dayananda SB, Chinmayee JT, Raghupathi AR. Tumors of the eyelid- A Histopathological Study of 86 cases in a Tertiary Care Hospital. International Journal of Scientific and Research Publications,2014;4(11):1-5.
 13. Al-Faky YH. Epidemiology of benign eyelid lesions in patients presenting to a teaching hospital. Saudi Journal of Ophthalmology.2012;26:211-6.
 14. Kale SM, Patil SB, Khare N, Math M, Jain A, Jaiswal S. Clinicopathological analysis of eyelid malignancies-A review of 85 cases. Indian J Plast Surg 2012; 45(1):22-8.
 15. J-K Wang, S-L Liao, J-R Jou, P-C Lai, SCS Kao, P-K Hou et al. Malignant eyelid tumors in Taiwan. Eye2003;17,216-20.
 16. Gupta S, Paricharak DG, Inamdar AA, Verma A, Ghatge RM and Sujatha N. Histopathological study of ophthalmic lesions. Int J Adv Res 2017;5(2):667-72.
 17. Bhadarge PS, Datar SS, Shrivastava AC, Umap PS, Shrikande AV. A Study of Common and Uncommon Eyelid Lesions-Telescoping Through Histopathology.JMSCR2016;4(12):14370-5.
 18. Jahagirdhar SS, Thakre TP, Kale SM, Kulkarni H, Mamtani M.A Clinicopathological study of eyelid malignancies from central India. Indian J Ophthalmol 2007 Ma-Apr;55(2): 109-12.
 19. Kumar R, Adhikari R, Sharma M, Phokharel D, Gautam N. Pattern of ocular malignant tumors in Bhairahwa, Nepal. The Internet Journal of Ophthalmology and Visual science2008;7(1):1-6.
 20. Bastola P, Koirala S, Pokhrel G, Ghimire P, Adhkari RK, A clinico-histopathological study of orbital and ocular lesions: A multicenter study. Journal of Chitwan Medical College. 2013;3(4):40-4.