

Thyroid cytology reporting by the Bethesda System: A two-year experience at an academic institute

Lalji G. Valiya¹, Seema N Baxi^{2,*}

¹Assistant Professor, ²Associate Professor, Dept. of Pathology, Government Medical College, Bhavnagar, Gujarat, India

***Corresponding Author:**

Email: seemabaxi@yahoo.com

Abstract

Introduction: Present study was aimed to report thyroid FNACs according to the latest guidelines given by the TBSRTC into diagnostic categories and subcategories, analyse category-wise cytomorphological characteristics and provide brief management guidelines to the treating consultants.

Materials and Methods: A total 276 patients with thyroid lesions were studied using non-aspiration FNA technique. The stained cytological slides were reported according to the TBSRTC monograph. The cytomorphological findings were compared with clinical findings and relevant investigations.

Result: Of 276 lesions, 240 (86.96%) cases were females. The commonest age group was 31-40 years. Benign category was the largest (84.78%) followed by non-diagnostic/unsatisfactory which was 6.16%. Malignant and suspicious of malignancy constituted 1.45% and 1.09% respectively.

Conclusion: Majority of thyroid lesions were benign and the Bethesda monograph provides uniform reporting system along with management guidelines, thus reduces inter observer variability and unnecessary surgical procedures.

Keywords: Bethesda, FNAC, Goiter, Thyroid.

Received: 15th May, 2017

Accepted: 02nd September, 2017

Introduction

Thyroid disorders are the most common among all the endocrine diseases in India.¹ Though thyroid nodules are common clinical findings with a reported prevalence of 4–7% in adult population, the vast majority is non-neoplastic lesions or benign neoplasms and only less than 5% are malignant.² Surgical intervention is preferred only in suspicious cases of cancer, thereby minimising unnecessary surgery as well as surgical complications like hypoparathyroidism, thyroid hormone dependence and injury to recurrent laryngeal nerve in cases with benign thyroid lesions.² Clinical presentation alone cannot be reliably distinguish these benign thyroid lesions from malignant nodules.² For thyroid swellings (either diffuse or nodular), cytopathological examination is now considered as a well-established and first line investigation for confirming benign lesions and thereby, minimising unnecessary surgery.³

Thyroid FNACs (Fine Needle Aspiration Cytology) reporting formats vary widely in different setups and different regions of the world, so it seems very difficult to interpret the report by the treating physicians. At some places reporting is done in categories which are equivalent to the histological categories, while at

other places various inconclusive or equivocal terms like possibly/probably neoplastic or malignant, suspicious of neoplastic or malignant, atypia present etc. are being used for thyroid cytology smears that show features in-between benign and malignant lesions.⁴ The National Cancer Institute (NCI) organised a conference at Bethesda, to deal with various issues related to terminologies and diagnostic criteria used for thyroid cytology reporting.⁵ To act with different fields about thyroid cytology, there were a total six committees. Cytomorphological criteria as well as diagnostic terminology for thyroid FNAC reporting were dealt by committee IV. Various recommendations made by the committees were widely published.^{5,6} The NCI subsequently defined six diagnostic categories along with category-wise brief management plan and risk of malignancy which is known as “The Bethesda System for Reporting Thyroid Cytopathology (TBSRTC) monograph”.⁷

Thyroid swelling is a common condition in Bhavnagar (Gujarat) region as it is one of the endemic goitre-belt in India. The present study, performed at an academic medical institute was aimed to pursue the TBSRTC guidelines for thyroid FNACs reporting, study their cytological features and guiding appropriate management policy to the clinical consultants.

Materials and Methods

A total of 276 successive thyroid swelling patients, which were referred to cytopathology section of Sir Takhtasinhji General Hospital and Government Medical College, Bhavnagar, Gujarat (India), were studied over a period of two years (from January 2014 to December 2015). After taking a detailed clinical history with relevant investigations, a complete medical examination was carried out including palpation of the swelling to check mobility, consistency & tenderness as well as searching for enlarged cervical lymph nodes. Informed written consent was taken from all the cases. Patient was instructed to lie down in a supine position with a pillow under the shoulder and neck to optimise exposure of the gland. During the procedure the patient was asked to refrain from swallowing and speaking. The procedure was carried out under aseptic precautions using 24-26 G needle attached to a 10 ml disposable syringe. No or minimal negative pressure was applied unless the

lesion was cystic. In the case of cystic lesions, the cysts' content was completely evacuated and if any palpable lesion remained after evacuation, re-aspiration was performed to exclude a neoplasm. Smears were made from the aspirated onto clean labelled glass slides. Slides were stained by Haematoxylin & Eosin and Papanicolaou methods after methanol fixation or stained by May-Grunwald-Giemsa (MGG) method after air drying. Whenever only fluidic material was aspirated, smears were made from the sediment after centrifugation. If the smears were acellular or excessively hemorrhagic, a repeat aspiration was performed once or twice. The stained smears were microscopically examined by consultant pathologists and reported according to the TBSRTC monograph (Table 1). The cytomorphological findings were correlated with clinical findings and relevant investigations. All collected clinical and cytological data were tabulated and analyzed using appropriate statistical methods.

Table 1: The Bethesda System for reporting thyroid cytopathology: recommended diagnostic categories, implied risk of malignancy, and recommended clinical management.⁷

Diagnostic category	Risk of malignancy (%)	Usual management ^a
(I) Nondiagnostic or unsatisfactory (ND/UNS)	-	Repeat FNA with ultrasound guidance
Cyst fluid only		
Virtually acellular specimen		
Other (obscuring blood, clotting artifact, etc.)		
(II) Benign	0-3	Clinical follow-up
Consistent with a benign follicular nodule (includes adenomatoid nodule, colloid nodule etc.)		
Consistent with lymphocytic (Hashimoto) thyroiditis in the proper clinical context		
Consistent with granulomatous (subacute) thyroiditis		
Other		
(III) Atypia of undetermined significance or follicular lesion of undetermined significance (AUS/FLUS)	5-15 ^b	Repeat FNA
(IV) Follicular neoplasm or suspicious for follicular neoplasm (FN/SFN)	15-30	Surgical lobectomy
-specify if Hurthle cell (oncocytic) type		
(V) Suspicious for malignancy (SFM)	60-75	Near-total thyroidectomy or surgical lobectomy ^c
Suspicious for papillary carcinoma		
Suspicious for medullary carcinoma		
Suspicious for metastatic carcinoma		
Suspicious for lymphoma		
Other		
(VI) Malignant	97-99	Near-total thyroidectomy ^c
Papillary thyroid carcinoma		

Poorly differentiated carcinoma		
Medullary thyroid carcinoma		
Undifferentiated (anaplastic) carcinoma		
Squamous cell carcinoma		
Carcinoma with mixed features (specify)		
Metastatic carcinoma		
Non-Hodgkin lymphoma		
Other		

^aActual management may depend on other factors (e.g., clinical and sonographic) besides the FNA interpretation.

^bEstimate extrapolated from histopathologic data from patients with “repeated atypicals”

^cIn the case of “suspicious for metastatic tumor” or a “malignant” interpretation indicating metastatic tumor rather than a primary thyroid malignancy, surgery may not be indicated.

Results

Out of a total 2470 FNAC cases over a period of 2 years, FNAC of thyroid swellings constituted 276 (11.17%) cases. FNAC of thyroid swellings was performed in the wide age range between 6 months to 100 years. The major presenting complaint in all the cases was diffuse or nodular long standing swelling in midline of the front neck, which moves on deglutition. Pain in the swelling, dysphagia, change in voice and cough were other rare complaints. **Table 2** shows distribution of cases as per TBSRTC guidelines. Benign category (Category-II) was the largest (84.78%) followed by Non-diagnostic/unsatisfactory (ND/UNS) category (Category-I) which was 6.16%. Category-VI (malignant) and category-V (suspicious for malignancy) constituted 1.45% and 1.09%, respectively, making a total of 2.54%. Category-III constituted 1.81% cases, while Category-IV had 4.71% cases.

Table 2: Distribution of lesions into six diagnostic categories of TBSRTC (N=276)

Diagnostic category	No. of cases	%
(I) Nondiagnostic or unsatisfactory (ND/UNS)	17	6.16
(II) Benign	234	84.78
(III) Atypia of undetermined significance or follicular lesion of undetermined significance (AUS/FLUS)	5	1.81
(IV) Follicular neoplasm or suspicious for follicular neoplasm (FN/SFN)	13	4.71
(V) Suspicious for malignancy (SFM)	3	1.09
(VI) Malignant	4	1.45
Total	276	100

240 cases (86.96%) were females and 36 cases (13.04%) were males. Ratio of Male: Female was 1: 6.7. Age group 31-40 years was the commonest (27.9%), followed by 21-30 years (23.55%) and 41-50 years (18.84%). Of the total, 194 (70.29%) cases were between 21-50 years of age (**Table 3**).

Table 3: Distribution of thyroid lesions according to age and sex after applying TBSRTC (N=276)

Age in years	Male	Female	I	II	III	IV	V	VI	Total (%)
0-10	2	3	0	4	0	0	0	1	5 (1.81)
11-20	6	24	0	30	0	0	0	0	30 (10.87)
21-30	5	60	4	58	0	2	1	0	65 (23.55)
31-40	10	67	4	68	3	2	0	0	77 (27.9)
41-50	10	42	2	43	2	2	1	2	52 (18.84)
51-60	1	27	6	19	0	3	0	0	28 (10.15)
61-70	0	11	1	8	0	2	0	0	11 (3.98)
>70	2	6	0	4	0	2	1	1	8 (2.9)
Total (%)	36 (13.04)	240 (86.96)	17	234	5	13	3	4	276 (100)

In the category-I, out of a total 17 cases, 9 had cyst fluid only with scattered cyst macrophages over fluidic background, 7 had scanty hemorrhagic aspirate with virtually acellular smears and one had few clusters of cells which morphology was obscured by excessive hemorrhagic background. In the category-II, majority of cases (60.87% of total) were consistent with a benign follicular nodule. It had low to moderately cellular smears comprised of mono-layered sheets of follicular cells without atypia over a background of colloid with or without blood. The smears of lymphocytic thyroiditis (11.96% of total cases) were moderately cellular composed of polymorphic population of lymphoid cells closely associated with benign thyroid follicular cells. The subcategory Grave's disease (11.96% of total cases) had thyroid function tests consistent with hyperthyroidism, moderately cellular smears comprised of cells with a large amount of pale, finely vacuolated cytoplasm, diffuse follicular structures, little or no colloid in the background and fire flares' in occasional MGG stained smears. Other subcategories were as per **Table 4**, including one case of amyloid goitre which was subsequently confirmed by fluorescent stain (Thioflavin T) at higher centre (**Fig. 1**).

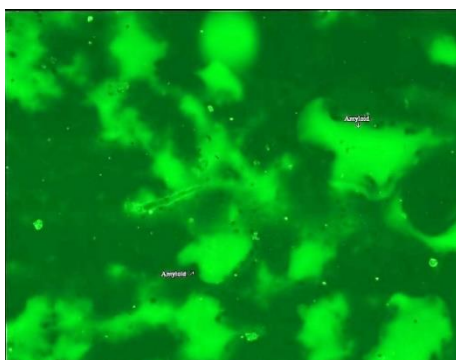


Fig. 1

Table 4: Number of cases in various diagnostic categories and subcategories according to TBSRTC (N=276)

Cytological categories	Subcategories	Number of cases	%
I	Cyst fluid only	9	3.26
	Virtually acellular specimen	7	2.54
	Obscuring blood	1	0.36
II	Consistent with benign follicular nodule(includes adenomatoid nodule, colloid nodule, etc.)	168	60.87
	Grave's disease	33	11.96
	Consistent with lymphocytic thyroiditis	16	5.8
	Consistent with Hashimoto thyroiditis	2	0.72
	Consistent with granulomatous (subacute) thyroiditis	2	0.72
	Amyloid goiter	1	0.36
	Dyshormogenic goiter	1	0.36
	Acute thyroiditis	4	1.45
	Thyroglossal duct cyst	7	2.54
III	Follicular lesion of undetermined significance (FLUS)	4	1.45
	Atypia of undetermined significance (AUS)	1	0.36
IV	Follicular neoplasm (FN)	11	3.99
	Suspicious for a follicular neoplasm (SFN)	2	0.72
V	Suspicious for papillary carcinoma	3	1.09
VI	Papillary thyroid carcinoma	3	1.09
	Poorly differentiated carcinoma	1	0.36

Of 5 cases of category-III, 4 cases of FLUS (follicular lesion of undetermined significance) had mild to moderate cellularity consisting of micro follicles dominance and focal atypia in a minor population of cells. In a case of AUS (atypia of undetermined significance), there is moderately cellularity with atypia in the form of nuclear enlargement along with irregular contour and pale chromatin, however micro follicles dominance was not seen.

In the category-IV, all cases (4.71% of total) had highly cellular smears comprised of crowded and overlapped mildly enlarged cells arranged in repetitive micro follicles over a hemorrhagic background devoid of colloid (**Fig. 2**). Of 14 cases, 3 cases had smears comprised predominantly of oxyphilic cells (Hurthle cell neoplasms) and one case had marked nuclear atypia and pleomorphism.

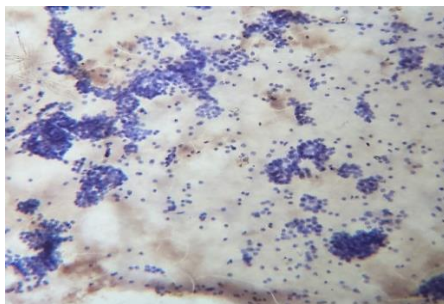


Fig. 2

Of 3 cases of category-V, one had scanty cellular smears with cells having all nuclear features (clearing, grooving, intranuclear cytoplasmic inclusions) of papillary carcinoma. Two had cellular smears comprised of sheets of cells with enlarged ovoid pale nuclei, occasional of them had nuclear grooving, but Intracytoplasmic nuclear inclusions were not seen at all.

In the category-VI, all cases (1.45% of total) had cellular smears. Three cases reported as papillary thyroid carcinoma (PTC) had smears consisting of syncytial cell aggregates or sheets having well defined anatomical borders, pale enlarged ovoid shaped nuclei, nuclear groove and intranuclear cytoplasmic inclusion in few cells (**Fig. 3**). One case had thick, ropy 'chewing gum' colloid. None of them had psammoma bodies. One case was diagnosed as poorly differentiated carcinoma had smears comprised of small aggregates of overlapped cells without microfollicular formation, singly scattered cells and hemorrhagic background. The cells had hyper chromatic nuclei and nuclear membrane irregularities but without the typical nuclear features of papillary thyroid carcinoma.

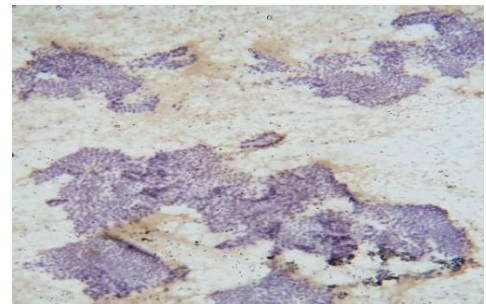


Fig. 3

Discussion

Before proceeding to surgical interventions, several other non-invasive tests including radioisotope scanning, high resolution ultrasonography etc. have been employed for evaluation of thyroid swellings. However FNAC is the most accurate, simple, safe, rapid and cost effective technique with a minimal complication rate, it is considered to be the gold standard initial investigation for managing thyroid lesions.⁸ Although the vast majority of thyroid nodules are benign, FNAC must be performed to exclude malignancy as well as to determine whether surgical removal of a detected nodule is recommended or not.⁹ Due to inception of the simplified six diagnostic categories of the Bethesda reporting system, reproducibility of the diagnosis may be increased and are logically relates to the prognosis.¹⁰ TBSRTC's each diagnostic category provides percentage-wise risks of malignancy and brief management plan, which offers uniform guidance for further management of the patients.¹¹

Being an academic institute situated in a goitre belt of India, we have lots of patients with thyroid disorders. Majority of these disorders are due to benign conditions and require no surgical treatments. For appropriate management of these patients, each and every case should be interpreted crucially. Also we want to bridge the communication gap between the pathologist, radiologist and treating physicians or surgeons, so that there would be no confusion regarding further management. We followed six tier (from category I to VI) reporting guideline of the TBSRTC, which can establish uniform communication and is useful to maintain uniformity not on in the confined region but also worldwide.

In present study, the patients were in age ranging from 6 months to 100 years. The mean age was found to be 38.11 years. Most patients (77 cases) were in 31-40yrs age group. This was similar to the studies by authors such as Verma

AK *et al.*¹² who also found most patients in the age group 31 to 40 yrs with mean age 37 yrs. Sinna EA *et al.*¹³ found the mean age to be 44 years. There was female preponderance as 240 patients (86.96%) were females and 36 patients (13.04%) were males. This was in concordance with the studies of other authors like Verma AK *et al.*, Sinna EA *et al.* and Tepeoglu M *et al.*¹²⁻¹⁴ who also reported prevalence of thyroid lesions in female population as 80.9%, 83.8% and 78.7% respectively. In present study female to male ratio was 6.7:1. Sinna EA *et al.*¹³ and Verma AK *et al.*¹² found the ratio to be 5.2:1 and 4.2:1 respectively.

Category-I: Out of the total 276 cases studied, 17 cases (6.16%) were Non Diagnostic/Unsatisfactory in our study. This was similar to Sinna EA *et al.*¹³ and Mehra P *et al.*¹⁵ who found 7.1% and 7.2% cases belonging to category I. Mondal SK *et al.*¹⁶ found these to be only 1.2% as they performed the FNA under USG guidance. Ultra sound guidance allows the precise localisation of the site to be aspirated, thus reduces the incidence of non diagnostic aspirate. Lower incidence as compared to the studies by authors like Jo VY *et al.*¹⁷ (18.6%) or Tepeoglu M *et al.*¹⁴ (12%) can be due the fact that in our institute, either consultant pathologist or resident doctor him/herself performs the procedure of FNAC, leading to an adequate aspirate as well as better quality of the smear, thereby allowing a more specific cytopathological diagnosis. This category was used whenever there were insufficient cellular materials or cellular details obscured by blood or artefacts. Such cases were further managed by repeat FNA with ultrasound guidance.¹⁸

Category-II: 234 cases (84.87%) were found to be benign in present study. Among these, the most common lesion reported was benign follicular nodule which was reported in 168 cases. This was followed by Grave's disease and lymphocytic thyroiditis, which were reported in 33 cases and 16 cases respectively. Other benign lesions were Hashimoto thyroiditis, granulomatous thyroiditis, amyloid goiter, dyshormogenic goiter, acute thyroiditis and thyroglossal duct cyst. Our study was in concordance with the study by Mondal SK *et al.*¹⁶ who reported 87.5% cases in the benign category. Mehra P *et al.*¹⁵ and Theoharis CG *et al.*¹¹ also reported the benign category as the most common category (80% and 73.8% respectively).

Category-III: We found 5 cases (1.81%) in this category which was similar to be the studies of Jo VY *et al.*, Theoharis CGA *et al.* and Mondal SK *et al.*^{17,11,16} who found these cases to be

3.4%, 3% and 1% respectively. This category was reserved for cases in which degree of nuclear atypia and/or architectural abnormalities were subtle than the category IV & V. Management plan for this category is a repeat FNAC preferably after a suitable interval.

Category-IV: We found 13 cases (4.71%) of follicular neoplasm or suspicious for follicular neoplasm (FN/SFN). The basic aim of the category is to detect all probable malignant lesions (follicular carcinomas). These cases are further managed by surgical lobectomy.

Category-V: In present study, 3 cases (1.09%) were Suspicious for papillary carcinoma. Similar findings were observed by Theoharis CG *et al.*¹¹ and Mondal SK *et al.*¹⁶ who found 1.3% and 1.4% cases in this category respectively. These cases are further managed either by near total thyroidectomy or by surgical lobectomy.

Category-V: In our study, only 4 (1.45%) FNA cases were malignant in which majority (3 cases) were papillary carcinomas except one which was poorly differentiated carcinoma. Sinna EA *et al.* and Tepeoglu M *et al.*^{13,14} also found the papillary carcinoma to be most frequent malignant lesion (72.4%). A malignant thyroid FNAC diagnosis is expected to account for 4–8% of all thyroids FNACs^{11,17} but much higher and lower results have been reported in the literature.^{19,20} However, the 'malignant' category consists mostly of PTC cases¹⁶⁻¹⁹ which was in concordance with the present study. Once cytological findings are indicative of a malignant lesion, it is further sub classified according to the cellular and architectural morphology. Malignant lesions are further managed by near total thyroidectomy except in cases of secondary tumours, unresectable/anaplastic carcinoma or lymphoma.¹⁸

Conclusion

We conclude that 'The Bethesda System for Reporting Thyroid Cytopathology' is best for thyroid disorders as it confirms uniformity by classifying the lesions in six categories along with category wise management guidelines, thus it reduces the inter observer variability, minimizes the unnecessary surgical procedures and plays a crucial role in bridging the communication gap between the medical personnel. The results of the present study are quite comparable with other studies conducted worldwide. Majority of thyroid lesions were due to benign conditions and are most prevalent in reproductive age group females.

References

1. N Kochupillai. Clinical Endocrinology in India-2. *Current Science* 2000;8:1061- 67.
2. Roman SA. Endocrine tumors. Evaluation of thyroid nodule. *Curr Opin Oncol* 2003;15:66-70.
3. Orell SR. In: Orell SR, Sterrett GF, Walters MN, Whitakar D, editors. Manual and atlas of fine needle aspiration cytology. New Delhi: Churchill-Livingstone;2005. p.125-64.
4. H. H. Wang. "Reporting thyroid fine-needle aspiration: Literature review and a proposal," *Diagnostic Cytopathology* 2006;34(1):67-76.
5. E. S. Cibas and M. A. Sanchez. "The national cancer institute thyroid fine-needle aspiration state-of-the-science conference: inspiration for a uniform terminology linked to management guidelines," *Cancer Cytopathology* 2008;114(2):71-3.
6. Z. W. Baloch, V. A. LiVolsi, S. L. Asa et al. "Diagnostic terminology and morphologic criteria for cytologic diagnosis of thyroid lesions: a synopsis of the national cancer institute thyroid fine-needle aspiration state of the science conference," *Diagnostic Cytopathology* 2008;36(6):425-37.
7. S. Z. Ali and E. S. Cibas, Eds., *The Bethesda System for Reporting Thyroid Cytopathology. Definitions, Criteria and Explanatory Notes*, Springer, New York, NY, USA, 2010.
8. Caruso P, Muzzaferrri EL. Fine needle aspiration biopsy in the management of thyroid nodules. *Endocrinology* 1991;1:194-202
9. Langer JE, Baloch ZW, McGrath C,Loevner LA, Mandel SJ. Thyroid nodule fine-needle aspiration. *Semin Ultrasound CT MR*, 2012;33:158-65.
10. Poller DN, Stelow EB, Thyroid FNAC cytology: Can we do it better? *Cytopathology*, 2008;19:4-10.
11. Theoharis CG, Schofield KM, Hammers L, Udelsman R, Chhieng DC. The Bethesda thyroid fine -needle aspiration classification system: Year 1 at an academic institution. *Thyro* 2009;19:1215-23.
12. Verma AK, Kohli S, Mehra P, Singhal A, Narang S, Kumar V. Correlation of sonographic criteria with Bethesda system of thyroid cytopathology reporting in thyroid nodules. *Indian Journal of Basic and Applied Medical Research*. 2014;3(2):582-92.
13. Sinna EA, Ezzat N. Diagnostic accuracy of fine needle aspiration cytology in thyroid lesions. *Journal of the Egyptian National Cancer Institute*. 2012;24:63-70.
14. Tepeoglu M, Bilezikci B, Bayraktar SG. A histological assessment of the Bethesda system for reporting thyroid cytopathology (2010) abnormal categories: a series of 219 consecutive cases. *Cytopathology*. 2014;25:39-44.
15. Mehra P, Verma AK. Thyroid Cytopathology Reporting by the Bethesda System: A Two-Year Prospective Study in an Academic Institution. *Pathology Research International* 2015,1-11.
16. Mondal SK, Sinha S, Basak B, Roy DN, Sinha SK. The Bethesda system for reporting thyroid fine needle aspirates: a cytologic study with histologic follow-up. *J Cytol*. 2013;30(2):94-9.
17. Jo VY, Stelow EB, Dustin SM, Hanley KZ. Malignancy risk for fine-needle aspiration of thyroid lesions according to the Bethesda system for reporting thyroid cytopathology. *Am J ClinPathol*. 2010;134:450-6.
18. Bhagat VM, Tailor HJ, Kaptan KR, Baladawa V, Prasad GH, Saini PK. Diagnostic role of the Bethesda system for reporting thyroid lesions: Effective tool for managing thyroid lesions. *Global J of Medical Research (C)*. 2014;14 (1):12-8.
19. Wu H H-J, Rose C, Elsheikh TM. The Bethesda system for reporting thyroid cytopathology: an experience of 1,382 cases in a community practice setting with the implication for risk of neoplasm and risk of malignancy. *DiagnCytopathol*.2011, 2012;40:399-403.
20. Broome JT, Solorzano CC. The impact of atypia/follicular lesion of undetermined significance on the rate of malignancy in thyroid fine-needle aspiration: evaluation of the Bethesda system for reporting thyroid cytopathology. *Surgery*. 2011;150:1234-41.