

Histopathological spectrum of appendicectomy specimens - A prospective study

R. Sujatha^{1,*}, Anushree CN², Neha Singh³

^{1,2}Associate Professor, ³PG Graduate, Dept. of Pathology, Dr. BR Ambedkar Medical College, Bangalore

***Corresponding Author:**

Email: drsujatha02@gmail.com

Abstract

Introduction: Acute appendicitis accounts for one of the most common conditions that demands emergency surgery. It is a clinical entity with an ongoing diagnostic challenge. Grossly, normal-appearing appendix, removed from patients with suspected acute appendicitis, on histopathological examination may reveal a more serious underlying pathology. Hence, histopathological studies form the gold standard for diagnosis of acute appendicitis. Faecoliths are the usual cause of obstruction, though there are many other causes, ranging from inflammatory conditions to malignancies.

Aim: To study histopathological patterns in all the patients who underwent appendectomy at our institution for a duration of 18 months, and to correlate with the clinical diagnosis.

Materials and Method: This is a prospective study of 230 appendicectomies carried out at Dr. B.R. Ambedkar Medical College and Hospital during a period of 18 months from April 2015 to October 2016. Clinical data was collected from patients of corresponding appendicectomy specimens received in histopathology department of Dr. B.R. Ambedkar Medical College and were processed routinely. Sections obtained were studied to determine various histopathological patterns in appendicectomy specimens.

Results: A total of 230 specimens were analyzed. 139(60.4%) were males and 91(39.6%) were females. The histopathological examination showed Acute appendicitis (46.5%), Chronic/recurrent appendicitis (27.8%), Acute suppurative appendicitis (6.5%), Eosinophilic appendicitis (3.5%), Gangrenous appendicitis (2.2%), Perforated appendicitis (1.3%), Carcinoid tumor (1.3%), Parasitic infestation (1.3%), Mucinous cystadenoma (0.4%). Negative appendectomy rate was found to be 9.2%.

Conclusion: Most of the cases in this study were diagnosed with usual features of appendicitis, though a few of them were essential incidental diagnoses which were missed preoperatively or intraoperatively. These important incidental diagnoses undeniably support the notion that all appendectomy specimens should be sent routinely for histopathological examination, which is not followed in many hospitals in India.

Keywords: Appendicectomy, Histopathology, Appendicitis, Cystadenoma

Introduction

Appendicitis accounts for most common abdominal emergency and appendicectomy is routinely performed surgeries all over the world.⁽¹⁾ Incidence of appendicitis is increasing in India and other developing countries, mainly in urban cities due to increased acceptance towards western diet.⁽²⁾ Appendicitis occurs commonly in children and young adults with a lifetime risk of 7%.⁽³⁾ In spite of all the recent advancements, clinical diagnosis of acute appendicitis is accurate in only 60-80% of cases.⁽⁴⁾ Therefore, histopathological examination stays the gold standard method of choice for confirmation of appendicitis.

Appendicitis can be obstructive/non-obstructive type. Luminal obstruction is the main factor in acute appendicitis and some of the common classical obstructive lesions are faecolith, lymphoid hyperplasia and foreign bodies. However some unusual factors could be involved which includes parasitic infestations like enterobiasis, ascariasis, bacterial infections like tuberculosis or a tumor as carcinoid, primary/secondary adenocarcinoma, lymphoma, gastrointestinal stromal tumor.⁽⁵⁾

So, the aim of present study is to evaluate the various histopathological diagnoses of appendicectomy specimens to find out unusual factors for appendicitis and compare them with other studies.

Materials and Method

This study was carried out in the department of Pathology at Dr. B.R. Ambedkar Medical College and Hospital, Bangalore. A total of 230 appendicectomy specimens were received in the histopathology section during a period of 18 months from April 2015 to October 2016. All emergency appendicectomies and interval appendicectomies done for cases of clinically suspected appendicitis and incidental appendicectomies done for other surgeries, were included. Relevant clinical data was retrieved. Gross findings were noted. Specimens were fixed in 10% formalin, routine tissue processing and paraffin embedding was done and 5 micrometre thickness sections obtained, were studied. Haematoxylin and eosin staining was used. Histopathological diagnoses were proposed based on the data.

Results

230 appendicectomy specimens were received in the pathology department for a study period of 18 months from April 2015 to October 2016. Among these patients, 139 were males and 91 were females, thus making a male: female ratio of 1.5:1. [Table 1] Out of these 230 cases, 209 cases had histologically proven appendicitis.

Majority of cases i.e. 129 out of 230 cases

presented clinically as Acute appendicitis followed by Recurrent appendicitis (89 cases), Appendicular abscess (10 cases) & Perforated appendix (02 cases).

In the current study, about 7 cases out of 230 cases showed incidental findings. 3 out of these 7 cases showed intraluminal parasite consistent with *Enterobius vermicularis*. Carcinoid tumor of appendix was found in 3 cases. An interesting finding was that of Mucinous cystadenoma of appendix which was seen in 1 case out of these 7 cases.

These 7 cases of incidental unusual diagnosis on histopathological examination were diagnosed preoperatively as Acute/Recurrent appendicitis. So, detection of these findings had a considerable impact on patient management.

Negative appendicectomy rate was 9.2% which accounted for 21 cases. These cases were diagnosed clinically as Acute/Recurrent appendicitis and after

histopathological examination, found that the primary cause of acute abdominal pain was due to some other pathology. [Table 2]

Table 1: Age & gender specific distribution in acute appendicitis patients

Age (years)	Males	Females	Total
0-9	1	1	2
10-19	32	20	52
20-29	78	45	123
30-39	23	21	44
40-49	2	2	4
50-59	2	1	3
60-69	1	1	2
Total	139 (60.4%)	91 (39.6%)	230

Table 2: Analysis of histopathological findings of appendicectomy specimens

Clinical Diagnosis	Histopathological Diagnosis	No of Cases	%
Acute Appendicitis (129 cases)	Acute Appendicitis	64	49.6
	Chronic/Recurrent appendicitis	35	27.1
	Acute suppurative appendicitis	05	3.8
	Eosinophilic appendicitis	04	3.1
	Gangrenous appendicitis	02	1.5
	Perforated	01	0.9
	<i>Enterobius vermicularis</i>	02	1.5
	Carcinoid	01	0.9
	Negative appendicectomy	15	11.6
Total	129		
Recurrent Appendicitis (89 cases)	Acute Appendicitis	43	48.3
	Chronic/Recurrent appendicitis	29	32.6
	Eosinophilic appendicitis	04	4.5
	Gangrenous appendicitis	03	3.4
	<i>Enterobius vermicularis</i>	01	1.1
	Carcinoid	02	2.2
	Mucinous cystadenoma	01	1.1
	Negative appendicectomy	06	6.8
Total	89		
Appendicitis with perforation (02 cases)	Perforated	02	
Appendicular abscess (10 cases)	Acute suppurative appendicitis	10	

Discussion

Acute appendicitis is the most frequently encountered surgical emergency. It accounts for about 40% of all surgical emergencies in the western world. It is rare in Asian and African countries. Due to adoption of western diet and lifestyle, recent studies show that there is an increase in incidence of appendicitis in African countries. Incidence of appendicitis varies considerably by country, race, age, sex, geographic region, socio-economic status, dietary habits, and hygiene.⁽²⁾

The vermiform appendix is considered by most to be a vestigial organ. Its clinical importance lies in its predilection for inflammation which results in clinical syndrome known as acute appendicitis. Acute appendicitis was recognized as a clinical entity first by Reginald Fitz. Soon afterwards, Charles Mc Burney described the clinical manifestation of acute appendicitis including the point of maximum tenderness in right iliac fossa, that's how it bears his name.⁽⁵⁾

Obstruction is usually in the form of luminal obstructions such as faecolith, fibrosis or stricture

which can lead to proliferation of aerobic and anaerobic bacteria. Lymphoid hyperplasia can also narrow the lumen leading to luminal obstruction. Once obstruction occurs, there is continued mucus secretion and inflammatory exudation which leads to increased intraluminal pressure resulting in obstruction of lymphatic drainage.⁽⁵⁾

It has been observed that in around 15-30% of cases diagnosed as acute appendicitis, there is discrepancy between the histopathological and clinical diagnosis. The histopathological study of appendix has the advantage that it confirms the diagnosis of acute appendicitis. Also, it reveals other important pathological findings that may not be obvious on gross examination intraoperatively but may affect further clinical management of patient.⁽⁶⁾

Regardless of advances in technology, there is no laboratory test or examination with adequate specificity and sensitivity to diagnose appendicitis consistently. Around 7% of the total population will be diagnosed with appendicitis in their lifetime with peak age incidence between 10 and 30 years.⁽⁵⁾

The current study was done for a period of 18 months and shows the histopathological findings of 230 appendectomy specimens received in the Pathology Department, Dr. B.R. Ambedkar medical college, Bangalore. In this study, emergency appendectomy were the most common cases followed by interval appendectomy. Maximum number of patients (53.5%) who underwent appendectomy belonged to the age group of 20-29 years [Table 1], which correlated with the study done by Marudanayagam et al. which also showed that most of the appendectomies (64.58%) were done in the second decade of life.¹ Number of appendectomies performed were more in males (60.4%) as compared to females (39.6%) which were consistent with findings by Zulfikar et al. who studied 323 cases of appendectomies retrospectively, in which, 196 (60.7%) were males and 127 (39.3%) were females.⁽⁷⁾

Among 230 appendectomy specimens, 205 (89.1%) were found to be non-neoplastic lesions and only 04 (1.8%) cases were diagnosed as neoplastic lesions, remaining 21 (9.1%) cases showed normal histology of appendix. [Table 4]. In a retrospective study by Blair et al. it was reported that 80% of appendectomy cases were non-neoplastic lesions and 4% were neoplastic.⁽⁸⁾ In the remaining cases(8.7%), normal histology of appendix was seen which was in concordance with our study.

In this study, majority of patients presented with right iliac fossa pain followed by generalized abdominal pain. Edino et al. in their study also reported that abdominal pain was the most common presenting symptom in such patients.⁽⁹⁾ Most common unusual gross finding in our study was mucosal congestion (78.2%) followed by presence of faecolith in appendiceal lumen (13.1%). This correlated with the

study by Majid et al who studied 250 appendectomy cases and found that mucosal congestion was the most common finding in 218 (87.2%) cases.⁽¹⁰⁾

In the present study, acute appendicitis accounted for the most common histopathological lesion for which appendectomy was done and was seen in 46.5% of patients. These findings correlated with the study done by Blair et al⁽⁸⁾ and Edino et al.⁽⁹⁾ Chronic appendicitis constituted the second most common lesion, seen in 27.8% cases. On the contrary, Edino et al. in their study reported 17% cases of chronic appendicitis.⁽⁹⁾ Acute suppurative appendicitis was reported in 15 (6.5%) patients.

Our study included 08 cases (3.5%) of eosinophilic appendicitis. Eosinophilic appendicitis is characterized by lack of neutrophils, there is eosinophilic infiltration in muscle layer with oedema supporting muscle fibres.¹¹ It may be associated with helminth infection e.g. Schistosomiasis, strongyloides or enterobius. Many studies have revealed that Type I hypersensitivity may also trigger the condition.⁽¹²⁾

The findings of appendicitis with gangrene and perforation were reported in 05 (2.2%) and 03 (1.3%) cases, respectively. These findings justified the delay by patients in seeking medical care.

The presence of *Enterobius vermicularis* in appendix usually produces symptoms resembling acute appendicitis. In our study, we reported 03 cases (1.3%) of *enterobius vermicularis* presenting with features of acute appendicitis. Interestingly, it was an incidental finding in histopathological examination. Worldwide, the reported incidence of *enterobius* infection in patients with symptoms of appendicitis ranges from 0.2% to 41.8%.⁽¹³⁾ [Fig. 1]

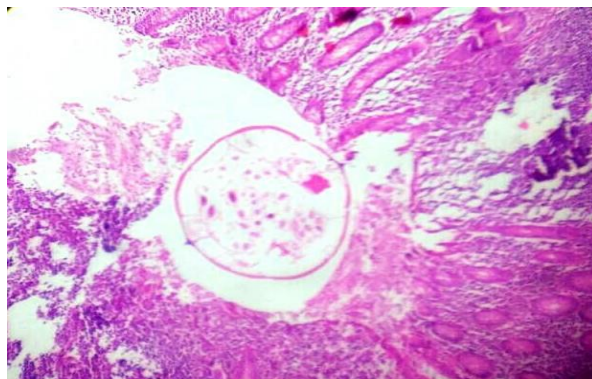


Fig. 1: Microphotograph showing enterobius vermicularis in lumen of Appendix (H & E, 10X)

Other incidental findings diagnosed were 3 cases of carcinoid which accounted for 1.3% of total cases. Likewise, Hof et al. in their study diagnosed carcinoid in only 07 (0.47%) cases.⁽¹⁴⁾ Carcinoids are the most common appendiceal tumors and are characteristically small, firm, well circumscribed yellow brown lesions on gross examination.⁽¹⁵⁾ Carcinoid tumor of appendix is found in 0.3%-2.27% of patients undergoing

appendicectomy.⁽¹⁶⁾ Clinical presentation of these tumors mimic appendicitis because they lead to luminal obstruction and produce increased levels of serotonin, histamine and kinin which are all potent mediators of inflammation.⁽¹⁷⁾ [Fig. 2,3]

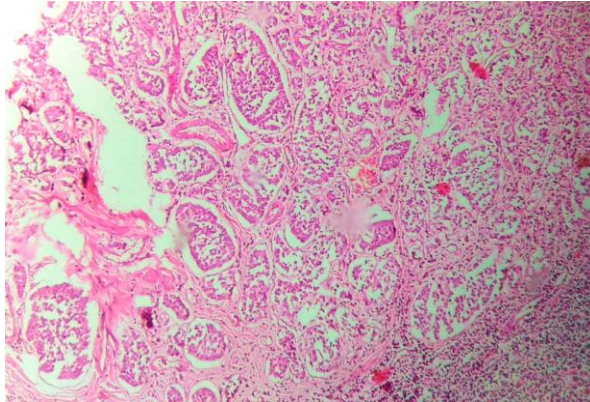


Fig. 2: Microphotograph of Carcinoid tumor showing monomorphic cell population arranged in nests and insular pattern involving the wall of appendix (H & E, 10X)

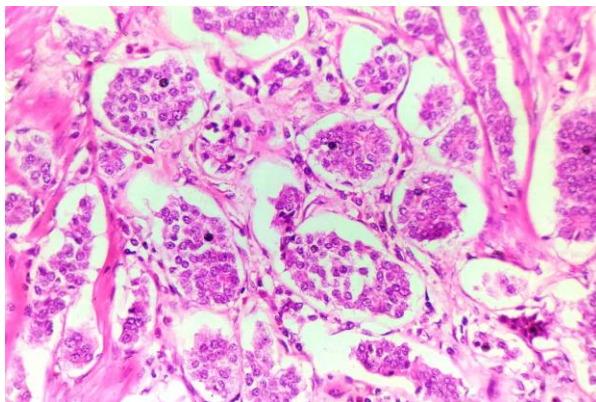


Fig. 3: Microphotograph of Carcinoid tumor with individual cells showing salt and pepper chromatin and retraction of peripheral tumor cells from stroma (H & E, 40X)

An incidental diagnosis of Mucinous cystadenoma was also made in our study (0.4%) which correlated with the study by Marudanayagam et. al who reported mucinous cystadenoma in 0.6% of cases.⁽¹⁾

In remaining cases (21 cases), no pathological abnormality was seen microscopically and these were labelled as normal appendices, which accounted for a negative appendicectomy rate of 9.2%. [Table 3] This correlated with various other studies where the negative appendicectomy rate has been found to be between 6.1 to 34.2%.^(6,7,18) [Fig. 4]

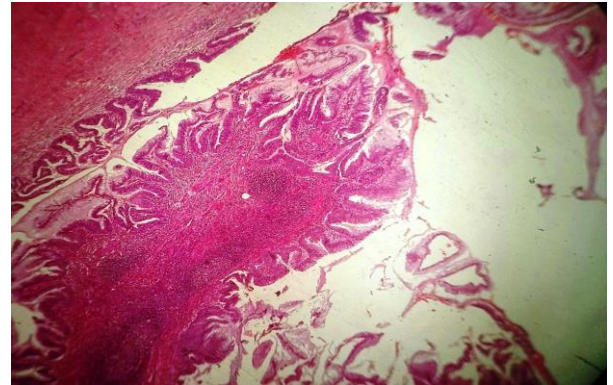


Fig. 4: Microphotograph showing Mucinous Cystadenoma with glands lined by pseudostratified columnar epithelium, individual cells have basally located elongated, crowded, hyperchromatic nuclei with mild atypia and scattered goblet cells with mucin in cavity (H & E, 10X)

Table 3: Histopathological findings for 230 appendicectomies

Histopathological Diagnosis	No. of Cases	%
Acute appendicitis	107	46.5%
Chronic/ Resolving/ Recurrent appendicitis	64	27.8%
Acute suppurative appendicitis	15	6.5%
Eosinophilic appendicitis	08	3.5%
Gangrenous appendicitis	05	2.2%
Perforated appendicitis	03	1.3%
Enterobius vermicularis	03	1.3%
Carcinoid	03	1.3%
Mucinous cystadenoma	01	0.4%
Negative appendicectomy	21	9.2%
Total	230	100%

Table 4: Distribution of appendicectomy specimens

Specimen	Cases	%
Non neoplastic lesions	205	89.1%
Neplastic lesions	04	1.8%
Normal appendix	21	9.1%

Conclusion

Appendicitis has a peak incidence in second and third decades of life. An accurate macroscopic assessment is difficult intra-operatively which emphasize the importance to send all appendicectomy specimens for routine histopathological examination. Results obtained from all pre-operative investigations are non-specific and final diagnosis is made only after histopathology. Even if there is some unusual/co-existing pathology, the final confirmation is always done by histopathology.

In the present study, the histopathological examination provided clue for the diagnosis of many important incidental lesions. These diagnoses had a very impactful role in the overall patient's management.

Hence, it can be concluded that the advantage of routine histopathological examination definitely supersedes the expenditure of procedure. Hence it is highly recommended that all appendectomy specimens should be sent for histopathological examination without fail, so that any unusual/coexisting pathology is never missed.

References

1. Marudanayagam R, Williams GT, Rees BI; Review of the pathological results of 2660 appendectomy specimens *Gastro.*, 2006;41(8):745-749.
2. Oguntola AS, Adeoti ML, Oyemolade TA. Appendicitis: Trends in incidence, age, sex and seasonal variations in South-western Nigeria. *Ann Afr Med* 2010;9:213-7.
3. Turner JR. The Gastrointestinal tract. In: Kumar, Abbas, Fausto(eds). *Robins and Cotran Pathologic basis of disease*. 8th edn. Saunders: Philadelphia;2010.pp870-1.
4. Fergusson JAE, Hitos K, Simpson E. Utility of white cell count and ultrasound in the diagnosis of acute appendicitis. *ANZ J Surg* 2002;72:781-5.
5. O'Connell PR. The vermiform appendix. In: Russell RC, Williams NS, Bulstrode CJ. editors. *Bailey and Love's Short Practice of Surgery*. 26th ed. London: Arnold Hodder;2010.p.1203-18.
6. Duzgun AP, Moran M, Uzun S, Ozmen MM, Ozer VM, Seckin S et al. Unusual findings in appendectomy specimens: Evaluation of 2458 cases and review of the literature. *Indian J Surg* 2004;66:221-6.
7. Zulfikar I, Khanzada TW, Sushel C, Samad A; Review of the pathologic diagnoses of appendectomy specimens. *Annals of King Edward Medical University*,2009;15(4):168-170.
8. Blair NP, Bugis SP, Turner LJ, Macleod MM; Review of pathological diagnosis of 2216 appendectomy specimens. *Am J Surg.*,1993;165(5):618-620.
9. Edino ST, Mohammed AZ, Ochicha O, Anumah M; Appendicitis in Kano, Nigeria: A 5year review of pattern, morbidity and mortality. *Annals of African Medicine*, 2004;3(1):38-41.
10. Majid S, Imran AA Khan SA; Morphological variations in appendectomy specimens. *Pak J Pathol.*,2005;16(2):58-60.
11. KP Aravindan, Deepthy Vijayaraghavan, Marie Therese Manipadam. Significance of eosinophil-edema lesion. *Indian J Pathol Microbiol* 2010;53:258-61.
12. Aravindan KP. Eosinophils in acute appendicitis: Possible significance. *Indian J Pathol Microbiol* 1997;40:491-8.
13. Aydin O. Incidental parasitic infestations in surgically removed appendices: A retrospective analysis. *Diagn Pathol* 2007;2:16.
14. In't Hof KH, Van Der Wal HC, Kazemier G., Lange JF; Carcinoid tumor of the appendix. Analyses of 1485 consecutive emergency appendectomies *J Gastrointest Surg* 2008;12(8):1436-1438.
15. Matthyssens LE, Ziol M, Barrat C, Champault GG; Routine Surgical Pathology in General Surgery. *Br J Surg* 2006;93:362-368.
16. Sieren LM, Collins JN, Weireter LJ, Britt RC, Reed SF, Novosel TJ, Britt LD. The incidence of benign and malignant neoplasia presenting as acute appendicitis. *Am Surg* 2010;76:808-811.
17. Cortina R, Mc Cormick J, Kolm P, Perry RR. Management and prognosis of adenocarcinoma of the appendix. *Dis Colon Rectum* 1995;38:848-52.
18. Nabipour F. Histopathological feature of acute appendicitis in Kerman-Iran from 1997 to 2003. *Am J Env Sci* 2005;1:130-2.