

Myxoid Neurothekeoma: Report of a rare tumour at unusual site

Shubhangi Vinayak Agale^{1,*}, Shubhangi Narayan Jibhate², Akshay Tiwari³, Sushma Bharti⁴

¹Associate Professor, ²Assistant Professor, ^{3,4}Resident, Dept. of Pathology, Grant Govt. Medical College, Mumbai

***Corresponding Author:**

Email: shubhagale@hotmail.com

Abstract

Introduction: Neurothekeoma is a rare benign soft tissue tumor of uncertain histogenesis which affects adolescents and young adults. It is rare to find these tumors occurring in children. Neurothekeoma usually presents with a small, solitary, and slow-growing nodule or papule on the upper body.

Case Report: We describe a case of a 9-year-old girl having large (5x4x1) painful swelling over back of 2 months duration. After total resection of the tumor, histological examination and immunostaining confirmed the diagnosis of myxoid neurothekeoma. The clinicopathological features of this rare tumor and its important differential diagnoses are discussed.

Conclusion: Neurothekeoma is a rare tumour in children and its' myxoid variant is even rarer. This benign tumour has to be differentiated from other malignant tumors as it has good prognosis.

Keywords: Nerve sheath tumour, Myxoid, Neurothekeoma

Manuscript Received: 2nd February, 2017

Manuscript Accept: 21st June, 2017

Introduction

Soft tissue tumors are uncommon in the pediatric age group and differ from adult incidences in different aspects, including frequency, anatomical site and prognosis.⁽¹⁾

Benign peripheral nerve sheath tumours are more common in adults than children and in children they are usually associated with neurofibromatosis.

Neurothekeoma also known as "nerve sheath myxoma" is a rare benign soft tissue tumour of uncertain histogenesis.⁽¹⁻⁹⁾ It commonly affects adolescents and young adults and has female predilection.⁽²⁾ This tumor is rarely seen in children as haemangioma is most common soft tissue tumour in this age group. The tumor commonly involves head and neck region and upper extremities⁽²⁻⁵⁾ but recently mediastinal neurothecoma has been described by Sayan et al.⁽⁹⁾

The lower extremities and trunk are the unusual locations for this tumors.⁽³⁾ Neurothecoma usually involves dermis, but mucosal and submucosal involvement has been described.⁽²⁾

We report a case of a myxoid neurothekeoma at an unusual site in 9 year old child.

Case Presentation

A 9 year old female child presented with painful swelling over back since 2 months. The child was otherwise healthy with normal developmental milestones. She had received immunization required for her age.

Physical examination revealed a tender midline swelling of size 5x4x1cm in the lumbar region which was red, firm without ulceration of overlying skin. Her complete blood count revealed Haemoglobin - 12.7gm/dl, WBC count 14700/cumm, Platelets-172000/cumm. Completely excised lesion was sent for histopathological examination

Pathological findings: Gross Examination: Received multiple flat tissue bits, smallest measuring 1x1x1cm and largest measuring 5x4x1cm, grey white congested. Cut surface was grey white, myxoid, soft to firm. Microscopically the tumour was comprised of variable sized fascicles with abundant myxoid substance with stellate cells and circular swirls of spindle cells at the periphery. The spindle cells had eosinophilic cytoplasm and spindle to wavy nuclei. There was no cellular pleomorphism or nuclear atypia. The mitotic activity and necrosis was absent. Histopathological diagnosis of myxoid neurothekeoma was favoured and immunohistochemistry was carried out to confirm the diagnosis.

Immunohistochemistry: S100 was positive in spindle shaped tumor cells.

Table 1: Reported cases of Myxoid Neurothekeoma below 10 years of age

S. No	Report	Year of report	Age in years	Sex	Site	Clinical presentation Tumor size	Type of neurothekeoma
1	Present	2016	9 year	F	Back	Painful swelling, 5x4 cm	Myxoid
2	Aktar et al ⁽¹⁾	2013	3 year	M	Left thumb	Non tender nodule, 10x8 mm	Myxoid
3	Al-Buainain H	2009	5 month	M	Left thumb	Non tender, 0.5x0.5 cm	Myxoid

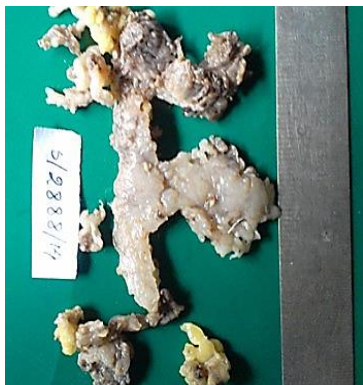

Fig. 1: Multiple tissue bits with gelatinous appearance

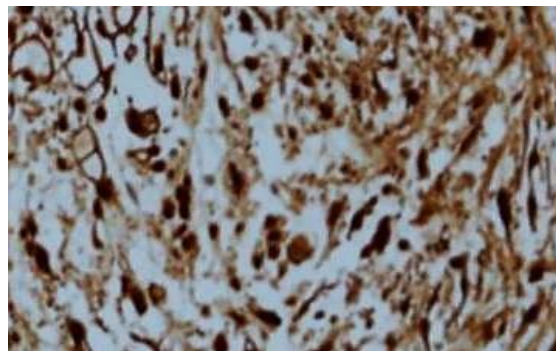


Fig. 3: Tumor cells expressing S-100 positivity

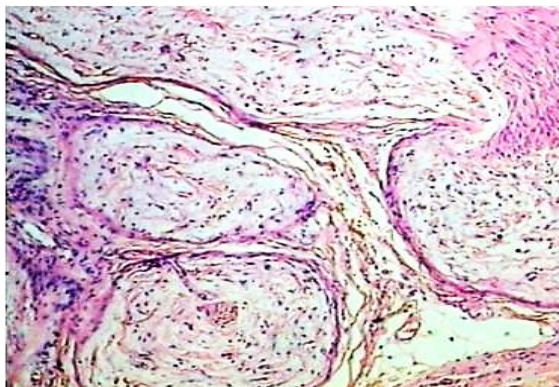


Fig. 2a: Lobulated tumor with myxoid stroma and peripheral sparse spindle cells [H&E, X100]

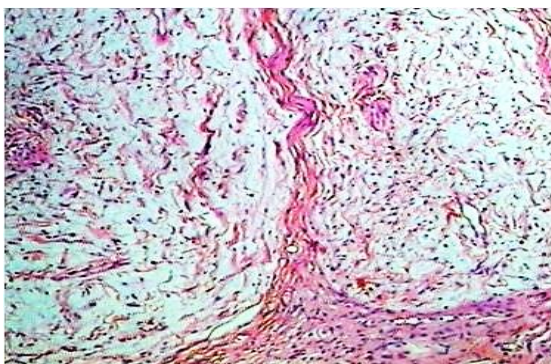


Fig. 2b: Spindle to stellate cells embedded in abundant myxoid stroma.[H&E, X400]

Discussion

Neurothekeoma is a rare benign nerve sheath tumor. It was first described by Harkin and Reed in 1969 as nerve sheath myxoma. The term neurothekeoma was suggested by Gallager and Helwing in 1980.⁽³⁾

Clinically neurothekeoma commonly present as a small solitary erythematous/ skin-coloured nodule on the face and upper limbs, measuring <3cm in greatest dimension.⁽¹⁻³⁾

Rarely, it involves lower extremity and trunk. The other anatomical sites have been reported, such as oral cavity, cauda equina, shoulder and neck.⁽²⁻⁴⁾

They are usually slow growing asymptomatic lesion or may be painful. In adults upper extremity is commonly involved and head neck is involved in 24% of cases, while in children head and neck comprised 45.5% of cases.⁽⁴⁾ It is a tumor of the adolescent and young adults, with a female predilection,⁽¹⁾ and is rare in children. Neurothekeoma is extremely uncommon below the age of 10 years with few reported cases.

Neurothekomas are classified into three types: classical (myxoid or hypocellular), cellular and mixed types based on their histological appearance and immunohistochemistry findings.⁽³⁻¹⁰⁾ The different histological subtypes are categorized in relation to their cellularity, mucin content and growth pattern.⁽³⁻⁵⁾ According to Fetsch et al, tumors with ≤10% myxoid matrix were named as cellular neurothekeomas and those with > 10% but ≤50% myxoid matrix were classified as mixed-type neurothekeomas. The tumors with > 50% myxoid matrix were called myxoid neurothekeomas.⁽¹⁰⁻¹¹⁾ These tumors were considered to

be derived from nerve cells or Schwann cells as the tumor cells are usually positive for markers of nerve-origin cells, such as S100 protein, GFAP, EMA and negative for macrophage markers including Ki-M1p and CD68.^(2,3,5,10)

Cellular type of neurothekeoma was first described in 1986,⁽¹⁰⁾ is poorly circumscribed, more cellular, contain scarce mucin and atypia. The mitotic features are more common as compared to other types of neurothekeomas. Immunohistochemistry shows positivity for neuron-specific enolase, Leu-7 and NK1C3. It does not stain with S100, collagen type IV, or nerve growth factor receptor.⁽²⁻⁵⁾

Myxoid type are characterized by proliferation of spindle cells in extremely myxoid matrix: they stain positively for S100, collagen type IV and nerve growth factor receptor and are negative for EMA.⁽⁵⁾ The mixed type of neurothekeoma shows areas of varied cellularity with focal myxoid areas and unreliable immunohistochemical markers.⁽³⁾

Differential diagnosis of neurothekeoma in children includes fibrous tumors, histiocytic tumors, and neural tumors.⁽⁶⁾ Neurothekeomas must be distinguished from certain malignant tumors such as malignant fibrohistiocytic tumors, neurotropic melanomas and low grade fibromyxoid sarcomas.^(7,8)

The differential diagnosis of myxoid neurothekeoma includes dermal myxoid, neurofibroma and superficial angiomyxoma.

The dermal myxoma, which is usually hypocellular and contains abundant stromal mucin. Superficial angiomyxoma is characterized by lack of circumscription, epithelial elements and inconspicuous blood vessels.

The closest differential diagnosis in our case was myxoid neurofibroma, but in this the myxoid matrix is seen only in limited area and is mixed with bundles of collagen. Neurofibroma distinctly has "shredded carrot" appearance which is absent in myxoid neurothekeoma.

While in neurothekeoma, there is characteristic well circumscribed fascicular masses with prominent myxoid matrix. The myxoid matrix is seen in all areas without collagen bundles.⁽⁷⁾ Immunohistochemically S-100 is positive in myxoid neurothekeoma and this is helpful to differentiate it from cellular variant of neurothekeoma.⁽¹⁻⁵⁾

In our case the unusual findings were age (9 year old child) uncommon site, a large tumor size. The literature search revealed very few cases of myxoid neurothekeoma below 10 years of age. [Table 1]

The treatment of choice for neurothekeoma is excision with clear margins. As it is a benign tumor it has good prognosis. Recurrence of tumor in some cases was thought to be secondary to incomplete removal of the original lesion.⁽⁸⁾ There are no reports in the literature of metastases, but the characteristics of atypical findings as large size (up to 6 cm), extension into muscle or fat, vascular invasion, infiltrative

borders, high mitotic index and distinct pleomorphism can make them behave aggressively.⁽³⁾

Conclusion

Neurothekeoma is a rare tumor in children and its myxoid variant is even rarer. Myxoid variant has distinct histological and immunohistochemical features which enable pathologist to differentiate it from other tumors.

References

1. Akhtar K, Zaheer S, Ray P, Sherwani K. Myxoid Neurothekeoma: A Rare Soft Tissue Tumor of Hand in a Male Toddler. *Nigerian Journal of Surgery* 2013;19:32-4.
2. Köse D, Uğraş S, Harmankaya I, Ciftçi I, Köksal Y. Neurothekeoma in childhood: a benign tumor mimicking malignant disease. *Turk J Pediatr.* 2014;56:208-11.
3. Koumanis D, Glickman L. Facial neurothekeoma in a 10-year-old child. *Can J Plast Surg.* 2007;15:175-7.
4. Papadopoulos EJ, Cohen PR, Hebert AA. Neurothekeoma – report of a case in an infant and review of the literature. *J Am Acad Dermatol* 2004;50:129-34.
5. Singh S, Sangwan M, Verma R, Ralli M. Myxoid Neurothekeoma: A Case Report. *IJHSR.*2014;4:204-6.
6. Hurwitz S. Cutaneous tumors in childhood. In: *Clinical pediatric dermatology: A textbook of skin disorders of childhood and adolescence.* 2nd ed. Philadelphia: Saunders; 1993. p. 198-241.
7. Fathaddin A, Fatani R. Palmar nerve sheath myxoma: A case report. *Oman Med J* 2012;27:64-6.
8. Al-Buainain H, Pal K, Shafie H, Mitra D, Shawarby M. Myxoid neurothekeoma: a rare soft tissue tumour of hand in a 5 month old infant. *Indian J Dermatol* 2009;54:59-61.
9. Sayan M, Celik A, Ertunc O, Uluoglu O, Tastepe AI. Mediastinal neurothekeoma: a rare tumor. *Asian Cardiovascular and Thoracic Annals.* 2015;23:593-5.
10. Yun SJ, Park HS, Lee JB, Kim SJ, Lee SC, Won YH. Myxoid cellular neurothekeoma: A new entity of S100-negative, CD68-positive myxoid neurothekeoma. *Ann Dermatol* 2014;26:510-3.
11. Fetsch JF, Laskin WB, Hallman JR, Lupton GP, Miettinen M. Neurothekeoma: an analysis of 178 tumors with detailed immunohistochemical data and long-term patient follow-up information. *Am J Surg Pathol* 2007;31:1103-14.