

Role of glial fibrillary acidic protein (GFAP) marker in central nervous system lesions

Geeta W. Mukhiya^{1,*}, Gulshan K. Mukhiya², KK Bansal³

¹Assistant Professor, Dept. of Pathology, ²Associate Professor, Dept. of Medicine, Geetanjali Medical College & Hospital, Udaipur, Rajasthan, ³Professor, Dept. of Neurosurgery, Narayana Hrudayalaya Hospital, Jaipur, Rajasthan

***Corresponding Author:**

Email: ucupasana124@gmail.com

Abstract

Introduction: The subject of tumours of the nervous system is often looked upon with apprehension by medical practitioners as central nervous system tumours constitute 1-2% of all the neoplasms. Gliomas constitute 38.7% of CNS tumours in which high grade gliomas are 59.5% of patients with systemic malignancies develop brain metastasis during their disease.

Glial fibrillary protein is the most frequently used marker in diagnostic neuro-oncology. Positive reaction to GFAP has been demonstrated in astrocytomas, ependymoma and astrocytic cells of mixed gliomas, subependymal giant cell astrocytoma, pleomorphic xanthoastrocytoma, astroblastoma and gliosarcoma.

Aim of the study: In the present study the main aim is to differentiate glial tumours from other lesions by morphology and confirmation by using Glial Fibrillary Acidic Protein (GFAP) immunostaining.

Results: In the present study glial tumors formed the largest group of cases (44 cases; 41.9%) diagnosed on cytology. They were further divided into low grade and high grade glioma / astrocytoma (33 cases, 31.4%), oligodendroglioma (1 case, 0.95%) and ependymoma (7 cases, 6.6%) based on cytological features. Subsequently, as shown in table IX, the cytohistopathological correlation for glioma / astrocytoma was 91.6%. There were 10 cases which turned out to be oligodendroglioma (4 cases, 11.1%), ependymoma (4 cases, 11.1%) and ganglioglioma (2 cases, 6.0%).

Keywords: GFAP, Glial Fibrillary Protein, Astrocytomas, Ependymoma

Manuscript Received: 7th March, 2017

Manuscript Accept: 22nd May, 2017

Introduction

Central nervous system tumours account for less than 2% of all malignancies. Tumours of the central nervous system (CNS) constitute a remarkably diverse group of both neoplastic and non-neoplastic conditions that can occur at virtually any site and in patients of any age. They can be primary neoplasms in all degree of differentiation, derived from any of the many normal cellular constituents; non-neoplastic tumour masses arising from normal constituents (hamartomas); neoplasms derived from embryo logically misplaced tissues; or secondary neoplasms metastatic from a variety of primary sites.⁽¹⁻²⁾

Therapeutic knowledge and management of brain tumours is based on an accurate knowledge of their size, location and histologic type, which is correctly assessed by CT and MRI scan. Stereotactic needle biopsies now a days play an important role in the diagnostic work up of cases of CNS tumours.⁽³⁾ Simple and reliable tool for rapid intra-operative diagnosis of CNS tumours is squash smear technique as it is the cytological features and smears pattern which disclose important complementary diagnostic information for histopathologic examination. Various authors have studied the diagnostic accuracy of intra-operative cytology, reporting cytohistological correlation in the range of 87.5% to 96%.⁽⁴⁾ However, some authors have also reported inherent problems such as recognition of highly differentiated astroglial neoplasm and differential diagnosis between poorly

differentiating brain neoplasm and metastasis to CNS.⁽⁵⁻⁷⁾

Immunohistochemical determination is regarded as essential tool for the more accurate identification of diagnostically difficult brain tumours. Its most widely used application is the determination of tumour type by presence of tissue specific lineage marker, showing great promise in helping to predict prognosis and response to therapy even at a very early point of tumour development, independent of stage and grade.⁽⁸⁾

The GFAP was first isolated by Eng and Bignami from plaques of multiple sclerosis in 1971. GFAP (MW 48,000 to 52,000) is a specific marker for immature, reactive and neoplastic astrocytes and ependymal cells.⁽⁹⁾ The presence of GFAP indicates astrocytic or ependymal differentiation. It has important diagnostic applications and expression of GFAP is used to distinguish astrocytic neoplasm from epithelial or mesenchymal tumours that may on occasion mimic a glioma. GFAP detection is also useful in the investigation of tumours histogenesis and differentiation both in vivo and in vitro. This antigen is present in neoplasm of astrocytic origin but is absent in neoplasm of mesenchymal derivation.⁽¹⁰⁾ Thus the present study was designed to study cytohistological correlation of all CNS lesions and to confirm cases of gliomas by GFAP stain.

Aims and Objectives

- To study central nervous system (CNS) lesions by

- intra-operative cytology and histology.
- To differentiate glial tumours from other lesions by morphology and confirmation by using Glial Fibrillary Acidic Protein (GFAP) immunostaining.
- To assess relative efficacy of cytology, histology and immunochemistry in diagnosing glial tumours.

Materials and Method

The present study was conducted over a period of 2 years, in Department of Pathology, HIMS, Dehradun and comprised of total 105 cases of CNS tumours including metastatic tumours to the CNS. The pattern of expression of GFAP was studied in these cases. Histopathological diagnosis was established on routine H and E staining of the sections. Special IHC markers (GFAP) were used to differentiate high-grade gliomas from metastatic tumours. Sections of the human brain were run with each batch of IHC stains to act as a positive control for GFAP. A negative control was obtained by substituting the primary antibody with an antibody of unrelated specificity.⁽¹¹⁾

Observations and Results

Over a period of 2 years, we examined total 105 cases of CNS tumours including glial tumours and metastatic tumours to the CNS. In our study, glial tumours were 44(41.9%), wherein the average age for the glial tumour was between 31-40 years (22.7%). Among glial tumours, 68.1% were male and 38.8% were females, whereas in metastatic tumours male to female ratio was 2:1 showing male preponderance. Out of these maximum number of glial tumours were seen in cerebral hemisphere 33(75%).

Radiological findings based on contrast-enhanced computer tomography (CT) revealed that the maximum cases of glial tumours were none enhancing as compared to metastasis, which were enhancing and hypodense.

In the present study, 37 out of 44 glial tumours were positive for Glial fibrillary acidic protein (GFAP) wherein 7 were negative. Fig. 1 shows the histological grading of glial tumours which were positive on Immunohistochemistry.

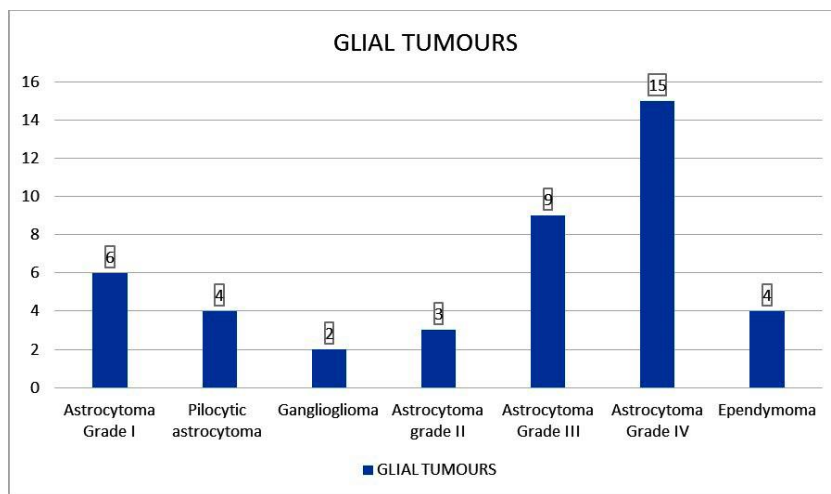


Fig. 1: Histological grading of glial tumours

Discussion

H and E staining is important for the diagnostic neuropathology wherein number of markers for IHC are developed. The most specific and sensitive IHC markers for tumours are GFAP for astrocytoma. Glial fibrillary acidic protein is the routinely used antigenic marker for mature astroglial cells and for altered astrocytes. Immunoperoxidase stains for GFAP is relevant in documenting astrocytic differentiation in tumors growing outside CNS parenchyma.^(9,11)

In the present study glial tumors formed the largest group of cases (44 cases; 41.9%) diagnosed on cytology. They were further divided into low grade and high grade glioma / astrocytoma (33 cases, 31.4%), oligodendroglioma (1 case, 0.95%) and ependymoma (7 cases, 6.6%) based on cytological features. Subsequently, as shown in table IX, the cytohistopathological correlation for glioma / astrocytoma was 91.6%. There were 10 cases which turned out to be oligodendroglioma (4 cases, 11.1%), ependymoma (4 cases, 11.1%) and ganglioglioma (2 cases, 6.0%).

This was due to the fact that the smears of oligodendroglioma showed large nuclei and clustering around blood vessels which gave a false impression of high grade astrocytoma. Similar findings were reported by Roessler et al who found that oligodendroglioma were most often misdiagnosed as astrocytoma (9.0% of cases) due to lack of uniform appearing nuclei and simulation of cytoplasmic processes.⁽¹²⁾

The glial tumors being the largest group, were further studied in detail and attempt was made to grade the tumor on cytological feature and then to correlate them with histological features GFAP stain was applied on histologically proven glial tumors and results were confirmed and compared further in Table 1.

Table 1: Comparison of glial tumours based on GFAP Immunohistochemistry

Study	Total cases	GFAP positive	GFAP negative	Percentage of positive GFAP
Ng and Lo ⁽¹³⁾	37 gliomas	37	-	100
Cosgrove et al ⁽¹⁴⁾	29 gliomas	29	-	100
Oh and Prayson ⁽¹⁵⁾	23 gliomas	23	-	100
	22 metastasis	3	19	13.6
Goswami et al ⁽¹⁶⁾	35 gliomas	35	-	100
	10 metastasis	-	10	0
Goyal et al ⁽¹¹⁾	74 gliomas	60	14	81
	6 metastasis	0	6	0
Present study	44 gliomas	37	7	84.1
	5 metastatic	0	5	0

Conclusion

High grade gliomas are routinely seen surgical neuropathology and it is important to differentiate them from metastatic tumours. From the present study it concluded a very high degree of cytohistological correlation. With better and precise radio imaging and stereotactic biopsies, the percentage of cytohistological correlation can improve and increase. Some cases will always require histopathological study and / or Immunohistochemical marker studies for definite diagnosis.

References

1. Qureshi IA, Jamal S, Mamoon N. Usefulness of crush smears in intraoperative consultation of neurosurgical biopsies. *J Coll Physicians Surg Pak.* 2006;16(9):590-3.
2. Burger P C, Scheithauer BW. *Surgical pathology of Nervous system and its coverings.* 4th ed. Philadelphia: Churchill Livingstone; 2002. p. 161.
3. Mouriquand C, Berrabid al, Breyton M. Stereotactic cytology of brain tumors: review of and eight years experience. *Acta cytologica* 1987;31:756-64.
4. Cappabianca P, Spaziant R, Caputi F, Pettinato G, Caro MD, Carrabs G et al. Accuracy of the analysis of multiple small fragments of glial tumors obtained by stereotactic biopsy. *Acta cytologica* 1991;35:505-11.
5. Beuvon F, Varlet P, Fallet-Bianco C, Daumas-Duport C. The smear technique for the extemporeous examination: diagnostic contribution to neurosurgical pathology. *Ann Pathol.* 2000;20:499-506.
6. Torres LF, Collaco LM. Smear technique for the intraoperative examination of nervous system lesions. *Acta Cytologica* 1993;37:34-39.
7. Willems GMS, Alva-Willems JM. Accuracy of cytologic diagnosis of central nervous system neoplasms in stereotactic biopsies. *Acta cytologica* 1984;28:243-149.
8. Eng LF, Rubinstein LJ. Contribution of immunohistochemistry to diagnostic problems of human cerebral tumors. *J Histochem Cytochem.* 1978;26(7):513-22.
9. Eng LF, Vanderhaeghen JJ, Bignami A, et al: An acidic protein isolated from fibrous astrocytes. *Brain Res* 1971;28:351-4.
10. McComb RD, Burger PC. Pathological analysis of primary brain tumors. *Neurol clin,* 1985;3(4):711-28.
11. Goyal R, Mathur S K, Gupta S, Goyal R, Kumar S, Batra A et al. Immunohistochemical expression of glial fibrillary acidic protein and CAM 5.2 in glial tumors and their role in differentiating glial tumours from metastatic tumors of

central nervous system. *Journal of neurosciences in rural practice,* 2015;6(4):499-503.

12. Roessler K, Dietrich W, Kitz K. High diagnostic accuracy of cytologic smears of central nervous system tumors: a 15 year experience based on 4172 patients. *Acta Cytol* 2002;46:667-674.
13. Ng HK, Lo ST. Cytokeratin immunoreactivity in gliomas. *Histopathology* 1989;14:359-68.
14. Cosgrove MM, Rich KA, Kunin SA, Sherrod AE, Martin SE. Keratin intermediate filament expression in astrocytic neoplasms: Analysis by immunocytochemistry, western blot, and northern hybridization. *Mod Pathol* 1993;6:342-7.
15. Oh D, Prayson RA. Evaluation of epithelial and keratin markers in glioblastoma multiforme: An immunohistochemical study. *Arch Pathol Lab Med* 1999;123:917-20.
16. Goswami C, Chatterjee U, Sen S, Chatterjee S, Sarkar S. Expression of cytokeratins in gliomas. *Indian J Pathol Microbiol* 2007;50:478-81.