

Utility of C-Kit Expression by Immunohistochemistry as a Prognostic and Theranostic Marker in Colorectal Carcinoma

G. Barathi^{1,*}, Leena D. Joseph², S. Rajendiran³, Suresh Varadarajan⁴

¹Assistant Professor, ^{2,3}Professor, Dept. of Pathology, ⁴Associate Professor, Dept. of Community Medicine, Sriramachandra Medical College & Research Institute, Chennai

***Corresponding Author:**

Email: gbarathi@gmail.com

Abstract

Objectives: Targeted therapy is now available for various carcinomas with growth factor receptor mutations. C-Kit, a tyrosine kinase receptor is overexpressed in many epithelial malignancies. The aim of this study is to determine the role of c-Kit (CD117) expression by Immunohistochemistry (IHC) in colorectal carcinoma (CRC) and to correlate the same with tumor grade, stage, nodal status and metastasis.

Methods: This is a retrospective study conducted on paraffin blocks of histopathology proven CRC. Monoclonal antibody detected against c-kit antigen was observed in the cytoplasm and epithelial membrane of the tumour cells and c-Kit expression was given a score based on staining intensity and percentage of cells showing positivity. A statistical analysis using chi square test was performed to find any difference between the various tumor grade, stage, nodal status and metastasis with respect to their c-kit expression by IHC.

Results: c-Kit was negative in 55% of the cases and out of 45% positive cases 3+ positivity was noted in 5% of the cases only. 2+ positivity was seen in 9% and 1+ in 31%. Statistical data showed a p-value of 0.96, 0.70, 0.48 and 0.68 for grade, stage, nodal status and metastasis of the tumor with respect to c-kit expression respectively.

Conclusion: C-kit expression by IHC has only a limited role and is statistically not significant as a prognostic or theranostic marker in CRC. Molecular analysis of the tyrosine kinase receptor mutation is needed to determine its aberrant expression.

Keywords: c-Kit, Colon cancer, Targeted therapy

Manuscript Received: 16th February, 2017

Manuscript Accept: 15th May, 2017

Introduction

The low incidence of large bowel cancers in Indian population compared to rest of the world can be attributed to high intake of starch and the presence of fibre and natural antioxidants such as curcumin in Indian cooking.⁽¹⁻³⁾ A significant increase in the incidence of colon cancer has been reported for both men and women over two decades due to change in the food habits and lifestyle.⁽³⁾ Researches on Immigrant Indian population also show similar findings.⁽⁴⁻⁵⁾

The main treatment option for Carcinoma colon is surgery. Other treatment modalities like Chemotherapy and radiotherapy are given depending upon the stage of the disease and margin status of the resected specimen. Molecular markers are now playing a vital role in predicting the prognosis and also in the targeted therapy. We all know that HER2-neu expression in breast cancer has revolutionized the use of prognostic-therapeutic immunohistochemistry (IHC) in the practical management of patients.⁽⁶⁾ Expression of theranostic markers like EGFR (Epidermal Growth Factor Receptor), VEGF (Vascular Endothelial Growth Factor), PDGFR (Platelet Derived Growth Factor Receptor), COX -2 (Cyclo-Oxygenase) on colonic carcinoma are tried by various research groups.⁽⁷⁻⁸⁾ Currently they also have a very valuable task of predicting the response to specific therapy against an erring molecule but with their own limitations.

Numerous other markers and proliferation pathways have recently been elucidated in many human cancers. One such marker is c-Kit (CD117), a proto-

oncogene, that encodes a transmembrane growth factor tyrosine kinase receptor (TKR) that shares a structural similarity with the Platelet Derived Growth Factor (PDGF) and Colony Stimulating Factor-1 Receptor (CSFR). This is a 145 kDa transmembrane glycoprotein, which belongs to tyrosine kinase (TK) subclass III family, the extracellular portion of kit binds a ligand known as stem cell factor (SCF) and the intracellular domain contain the enzymatic kinase activity.⁽⁹⁾

Over expression or mutation of c-Kit had been reported in a variety of tumours depending on the involvement of extracellular, transmembrane or intracellular domain of the c-Kit proto-oncogene. Well established association is documented with gastrointestinal stromal tumors (GIST), testicular seminoma, mast cell disease, melanoma, chronic myeloid leukemia (CML), carcinoma lung, carcinoma breast, renal cell carcinoma and rarely in other cancers.⁽¹⁰⁻¹⁴⁾

To our knowledge the expression of c-kit in carcinoma of colon was not tested in Indian patients. After thorough review of literature and also earlier research studies on c-Kit expression on renal, breast and gastric carcinomas in our institute we decided to test c-Kit expression in our colon cancer patients by Immunohistochemistry and to apply this knowledge in predicting the prognosis and if possible its role as theranostic (predictive) marker for anti tyrosine kinase receptor antibodies (Imatinib mesylate) in appropriate patients.⁽¹⁵⁾

Materials and Method

This is a retrospective study conducted on estimated sample size of 100 formalin fixed paraffin embedded tissue blocks of histopathology proven colon cancer specimens received in the Department of Pathology at Sri Ramachandra University from 2009 to 2011. The block containing sections from tumor tissue, dysplastic epithelium and adjacent normal mucosa was selected for IHC along with controls (IHC positive GIST). Permission of the institutional ethics committee was obtained prior to the commencement of the study (REF:CSP/11/APR/15/17).

Gross findings were noted from the request files and clinical data was obtained from the medical record section and hospital information network services. Hematoxylin and Eosin stained sections were used to grade the colon cancer by architectural and cytological features. In our Institute we follow a reporting format based on CAP (College of American Pathologists) protocol, recommended by American Joint Committee on Cancer (AJCC) and International Union against Cancer (UICC). A low grade is assigned to tumor having $\geq 50\%$ gland formation (well and moderately differentiated) and high grade to tumor having $<50\%$ gland formation (Poorly and undifferentiated). Pathological staging (pTNM) was also determined as per the guidelines. Other histopathological features observed were adjacent dysplasia, adenomas, intratumoral and peritumoral inflammatory response.

Immunohistochemistry staining for c-Kit was performed on all the 100 blocks. Polyclonal antibody detected against c-kit antigen was looked for in the cytoplasm and/or membrane of the tumour cells by two pathologists. A semi quantitative scoring system based on staining intensity and percentage of tumor cells showing positivity was followed. Negative staining was given a score 0. If Positive, a score of 1+ were given if weak and seen in 25% of the tumour; 2+ if moderate and present in 26-50% of the tumour cells; and 3+ if intense staining and seen in $>50\%$ of the tumour cells as per c-Kit pharmDx™ Interpretation manual provided by the company (Dako). IHC positive GIST was used as positive control and negative control (by omitting the step of primary antibody addition) which determines the immunostaining specificity for c-kit (Fig. 1).



Fig. 1a: c-Kit + GIST (positive control) X 100

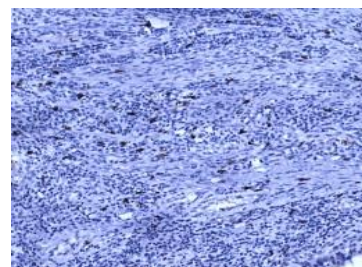


Fig. 1b: c-Kit + in the interstitial cells of Cajal which acted as an internal control in all the sections X 40

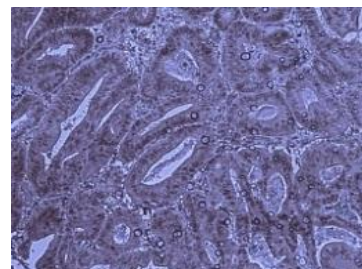


Fig. 1c: Normal epithelium showing 2+ cytoplasmic staining for c-Kit X 100

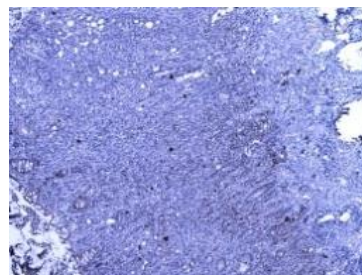


Fig. 1d: Dysplastic epithelium with foci of 2+ staining for c-Kit X 40

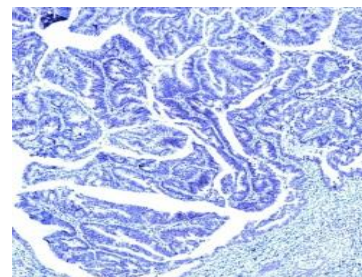


Fig. 1e: Adenocarcinoma negative for c-Kit IHC X 40

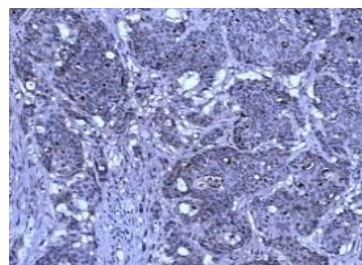


Fig. 1f: Tumor cells showing 1+ staining for c-Kit in the cytoplasm X 100

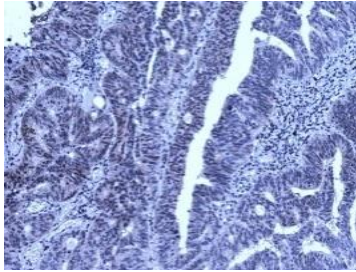


Fig. 1g: Tumor cells showing 2+ staining for c-Kit in the cytoplasm X 100

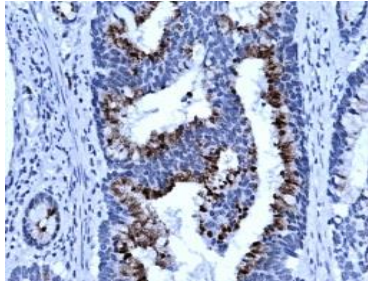


Fig. 1h: 3+ positive c-Kit expressions by IHC noted focally in the tumor cells X 200

R version 2.14.1 software was used for statistical analysis. Qualitative data were presented as frequencies and percentages. Pearson Chi-square(χ^2) test and student t-test (age vs. c-Kit) was performed and $P < 0.05$ was considered a statistically significant value for c-Kit expression with respect to all the analyzed parameters.

Results

In our study the age of the patients ranged from 19 to 84 years. 2/3 of the total was more than 50 years old (67%). Highest incidence was noted in the age group 61 to 70 years (28%) followed by the age group 51 to 60 years (24%). Male to Female ratio of 1.7:1 was observed. Age distribution in both the sexes was the same. Recto-sigmoid was the most common site involved (66%) and least occurrence of the tumour was noted in the descending colon (4%). Size of the tumours was ranging from 1.5 to 16 cm in maximum dimension. 64% of the tumour size ranged between 5 and 10cm. In this study low grade tumours predominated (64%) in both the sexes and the high grade tumours were more common in males. Stages I & II were categorized as low stage and stages III & IV as high stage. High stage tumours were common in males than females and those above 60 years of age. Summary of various clinicopathological profile of this study group is given in Table 1.

Analysis of C-Kit expression with various parameters: C-Kit expression in normal epithelium was considered nonspecific due to weak cytoplasmic positivity and the intensity score of 3+ positive was noted just in 1 case, 2+ positive in 3 cases, 1+ positive in 22 cases, and c-Kit was negative in 74% of the cases

(Fig. 2). Analysis of dysplastic epithelium also showed inconclusive results. 3+ positive was noted in 2 cases, 2+ positive in 3 cases, 1+ positive in 10 cases, and 85% of the cases were negative (Fig. 3).

In carcinomas c-Kit was negative in 55% of the cases and out of 45% positive cases 3+ staining was noted in 5% of the cases only (Fig. 4). 2+ was seen in 9% and 1+ in 31%. Statistical analysis using Chi-square test showed a p-value of 0.7. Tumour grade, stage, nodal status and distant metastasis in relation to IHC positivity was analyzed for correlation (Table 2). 3+ positive staining was observed in all tumor grades with a maximum number seen in grade 2 CRC (3 out of 5). Likewise 4 cases of pT3 and 2 cases of pN2 also showed 3+ staining. There were only 3 cases in our study that had metastasized to distant site and none showed 3+ staining. We also tried to evaluate c-Kit expression in relation to age by t-Test ($p=0.28$) and sex by chi-square ($p=0.79$) (Table 3). C-Kit expression when compared to lymphocytic response showed a p-value of 0.5. Statistical values of all the analyzed parameter is given in Table 4.

Table 1: Summary of clinicopathological observations

Parameters	% (n = 100)
Age	
> 30 years	90%
< 30 years	10%
Gender	
Male	63%
Female	37%
Site involved	
Ascending colon	19%
Transverse colon	11%
Descending colon	04%
Sigmoid colon	25%
Rectum	41%
Size of Tumor (in centimeter)	
Less than 5 cm's	30%
5 to 10 cm's	64%
More than 10 cm's	06%
Histological Grade	
Well differentiated	21%
Moderately differentiated	69%
Poorly differentiated	10%
pTNM staging	
Primary Tumor (pT)	
pT1	00%
pT2	27%
pT3	70%
pT4	03%
Nodal status (pN)	
PNx	07%
pN0	45%
pN1	25%

pN2	23%
Distant Metastasis (pM)	

Not applicable (Mx)	97%
pM1	03%

Table 2: Analysis of c-Kit expression with respect to Grade and Stage

c- Kit Expression	Grade					pTNM								
	G 1	G 2	G 3	G 4	Total	pT2	pT3	pT4	N0	N1	N2	Nx	pM1	Mx
Negative	12	35	8	0	55	14	40	1	23	17	13	2	2	53
1+	9	20	2	0	31	7	24	0	15	8	4	4	1	30
2+	0	6	1	2	9	5	2	2	5	0	4	0	0	9
3+	1	3	1	0	5	1	4	0	2	0	2	1	0	5
Total positivity	10	29	4	2	45	13	30	2	22	8	10	5	1	44

As the sample size was 100 the absolute numbers in the above table is also the % of c-kit expression.

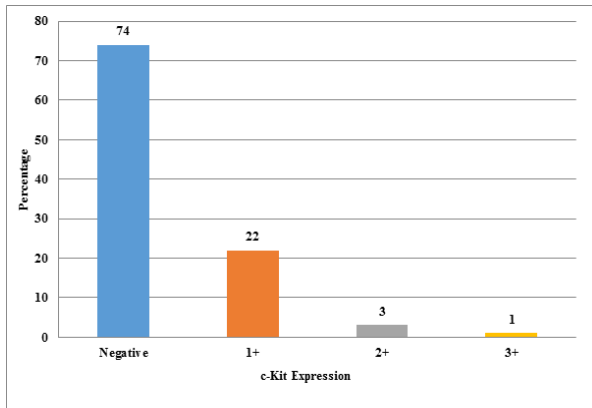


Fig. 2: c-Kit Expression in Normal Epithelium

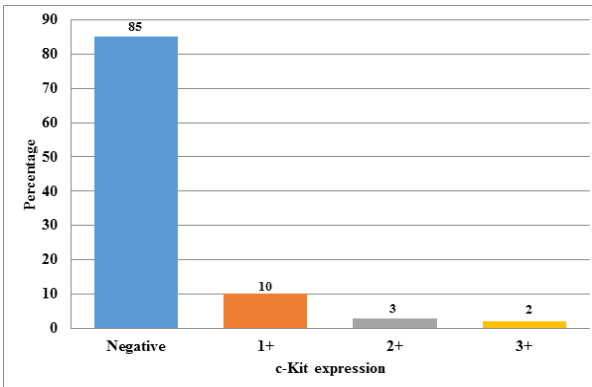


Fig. 3: c-Kit expression in Dysplastic epithelium

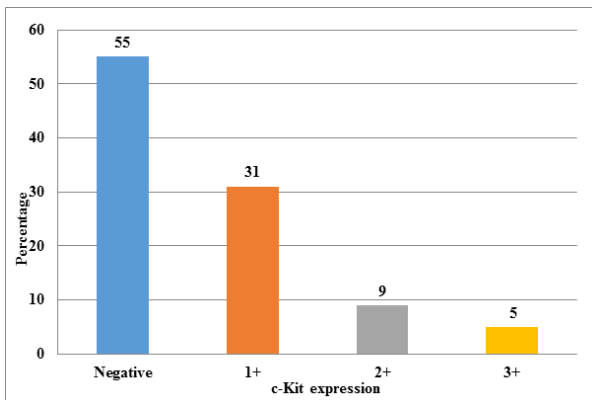


Fig. 4: c-Kit expression in Carcinoma

Table 3: C-Kit expression with respect to gender

Gender	c- Kit Expression		
	Positive	Negative	Total
Female	16	21	37
Male	29	34	63
Total	45	55	100

Table 4: Statistical results of c-Kit expression

Parameters	P value
Histological Grade	0.9613
Primary tumor (pT)	0.7004
Regional lymph node metastasis (pN)	0.4831
Distant Metastasis (pM)	0.6800
Age ^a	0.2842
Gender	0.7867
Lymphocytic response (Tumor Immunity)	0.4921

^a The above p values were calculated using Chi-square test except in case of age for which student t test method was applied.

Discussion

Targeted therapy is now available for various tumors. The c-Kit tyrosine kinase inhibitor (TKI) - Imatinib mesylate (STI571) is widely used in CML, GIST and other malignancies. Recent studies have mentioned c-Kit expression in relation to colorectal carcinoma and colonic adenomas as well as in colon cancer cell lines.⁽¹⁵⁾ The main aims of all these studies were to detect any significance in c-Kit expression of CRC to establish a therapeutic role of Imatinib. The incidence of c-kit expression by IHC in these studies widely varied from 3% to 60%. Most of the findings of our study were in concordance with other studies.

Demographically all the parameters of CRC we analyzed were correlating with international literature. We also observed the fact that there is a minimal increase in the incidence of younger population compared to the previous data by Mumbai registry.⁽¹⁶⁾ There was no definitive predilection of site for large tumours. Smaller tumours were commonly observed

probably due to early diagnosis because of increasing awareness and utilization of medical services.

We consider performance of c-Kit expression by IHC itself as our strength because in a resource restricted country like India, testing a predictive marker is expensive. A study of this kind was not tried earlier in Indian population. We had done this study with institutional support mainly for the benefit of our patients. When we analyzed the English literature there is a marked variation in the result of c-Kit by IHC alone. Many researchers have included protein expression by Westernblot and c-Kit m-RNA by Polymerase chain reaction (PCR) in their study. We consider non-performance of ancillary tests as our weakness because others have concluded that c-Kit is rarely detected by IHC and readily expressed at protein and m-RNA level.

A study by Toyota et al in 1993 demonstrated c-Kit expression at mRNA and protein level but not by IHC.⁽¹⁷⁾ Their data suggested that c-Kit and KL (Kit Ligand) may play an important role as an autocrine loop in the proliferation of some colon carcinoma cells. This has led many researchers to work on this field. Reed et al observed that only 1.6% of the cases were positive for c-Kit and it was noted that this low

positivity was shown only by poorly differentiated carcinomas arising at the anorectal junction.⁽¹⁸⁾ Normal colonic mucosa and adenomas were negative for c-Kit.

Similar results were obtained by various research groups. We have compared the c-Kit expression of these studies with that of the current study and presented here (Table 5). Our study was in concordance with literature review except for the study by Mostafa et al from Egypt. All the study unanimously raises the question of usefulness of testing c-kit expression by IHC because it was only rarely detected in CRC. Everyone concluded that further molecular studies may be required for a definitive opinion.

We know c-Kit proto-oncogene belongs to a group of tyrosine kinase growth factor receptor family involved in signal transduction mechanism maintaining normal proliferation, growth survival, and anti-apoptosis of the normal cells. Their expression in normal breast, renal and gastric tissues is well documented.⁽¹⁸⁻²⁰⁾ Down regulation of this expression was seen in carcinoma of the breast. In gastric carcinoma it is associated with increased metastatic potential of the tumor by inducing factors helpful in tumor progression (epithelial-mesenchymal transition).⁽²¹⁾

Table 5: CRC c-Kit expression by IHC – A comparison with other related literature

Sl. No.	Author Name	Year of study	c-Kit IHC Antibody	Sample Size	c-Kit Positive	c-Kit Negative	c-Kit expression (%)
1	This study	2012	Polyclonal	100	45	55	45.00%
2	Reed et al ⁽²²⁾	2002	Polyclonal	126	02	124	01.59%
3	Yorke et al ⁽²³⁾	2003	Polyclonal	62	02	60	03.23%
4	Akintola-Ogunremi et al ⁽²⁴⁾	2003	Polyclonal	25	0	25	00.00%
5	Sammarco et al ⁽²⁵⁾	2004	Polyclonal	20	05	15	25.00%
6	Singer et al ⁽²⁶⁾	2004	Polyclonal	75	04	71	05.33%
7	Bellone et al ⁽²⁷⁾	2006	Polyclonal	94	10	84	10.64%
8	Ana Preto et al ⁽²⁸⁾	2007	Polyclonal	109	16	103	14.67%
9	Friederichs et al ⁽²⁹⁾	2010	Polyclonal	263	45	218	17.11%
10	Mostafa M El Serafi et al ⁽³⁰⁾	2010	Polyclonal	90	51	39	56.67%

This comparison is based on review of articles published on c-Kit expression of colorectal carcinoma. Article reference number is given in the brackets.

The controversy in c-kit IHC expression made many researchers to adopt an additional mutational analysis using PCR, western blot and cancer cell line studies for further evaluation. TKR has 3 domains. Extracellular domain is partly encoded by exon 9 and intracellular enzymatic kinase domain is encoded by exon 13 and 17. Exon 11 encodes juxtamembrane domain which is most commonly mutated in GIST. A subset of GIST was documented to have mutation in exon 13 and 17. A transmembrane domain mutation is noted in few cases of small cell carcinoma of lung. Why we highlight it here is this variation in gene encoding different regions of the same TKR may be the reason for varied c-Kit expression by IHC. Harboring of c-Kit mutation at different domains is proved in solid tumors.

Aim of all research in this field is to try a targeted therapy in patients who express c-Kit. Many studies suggest that there was a strong correlation between the signal transduction pathways of TKR and variation in treatment response of the patients. They provide evidence stating that personalized risk factor assessment should be done for

CRC patients after surgery and categorize them as those who benefit by tyrosine kinase inhibitor based on their c-Kit expression.

Attoub et al and Singer et al had done mutational analysis and in vitro c-Kit expression of CRC cell lines and raises concern about the efficacy of the TKI in vivo. They also found co-expression of SCF and other receptors in CRC and other tumors and believed that targeting single TKR may not produce sufficient response by tumor cells because of lack of specificity. Novel therapy of TKI increased the disease free survival of patients with CML and GIST but not in CRC clinical trials.

Conclusion

C-Kit expression by IHC in CRC remains an enigma. Though there were documented correlation between c-Kit expression and CRC by molecular techniques no study could pinpoint the aberrant mutation that is expressed by IHC. Further evaluation and more clinical trials are required for a definitive therapeutic implication. Hence a serious relook into the modality of testing for c-Kit should be considered in CRC for an optimal theranosis.

References

1. Curado MP, Edwards B, Shin HR, et al. Cancer Incidence in Five Continents, Volume IX. IARC Scientific Publication, No 160. IARC, Lyon 2007.
2. National Cancer Registry Programme. Accessed at: http://www.icmr.nic.in/ncrp/cancer_reg.htm on November 4, 2010.
3. Vaishali B. Patel, Sabeena Misra, Bhaumik B. Patel, et al. Cancer: Chemopreventive Role of Curcumin and Resveratrol. *Nutr Cancer* 2010;62(7):958-67.
4. Rastogi T, Devesa S, Mangtani P, et al. Cancer incidence rates among South Asians in four geographic regions: India, Singapore, UK and US. *Int J Epidemiol* 2008;37:147-60.
5. Ali R, Barnes I, Kan SW, Beral V. Cancer incidence in British Indians and British whites in Leicester, 2001-2006. *Br J Cancer* 2010;103:143-8.
6. Walter P Carney, Kim Leitzel, Suhail Ali, et al. HER2 therapy, HER-2/neu diagnostics in breast cancer. *Breast Cancer Research* 2007; 9(3):207.
7. Gert De Hertogh, MD, PhD; Karen Paula Geboes, MD, PhD. Practical and Molecular Evaluation of Colorectal Cancer. *Arch Pathol Lab Med* 2010; Vol 134: 853-863.
8. R. Brown and Raymond N. Dubois. COX-2: A Molecular Target for Colorectal Cancer Prevention. *Journal of Clinical Oncology* 2005 April; Vol 23: 2840-2855.
9. Harissios Vliagoftis, Alexandra S. Worobec, Dean D. Metcalfe. The protooncogene c-Kit and c-Kit ligand in human disease. *J Allergy Clin Immunol* 1997; 100: 435-40.
10. Lux ML, Rubin BP, Biase TL, et al. KIT extracellular and kinase domain mutations in gastrointestinal stromal tumors. *Am J Pathol* 2000; 156:791-795.
11. Kemmer K, Corless CL, Fletcher JA, et al. KIT mutations are common in testicular seminomas. *Am J Pathol* 2004; 164:305-313.
12. Nakata Y, Kimura A, Katoh O, et al. C-kit point mutation of extracellular domain in patients with myeloproliferative disorders. *Brit J Haematol* 1995; 91: 661-663.
13. Micke P, Basrai M, Faldum A, et al. Characterization of c-kit expression in small cell lung cancer: prognostic and therapeutic implications. *Clin Cancer Res* 2003; 9(1):188-94.
14. Charpin C, Giusiano S, Charfi S, et al. Quantitative immunohistochemical expression of c Kit in breast carcinomas is predictive of patients' outcome. *Br J Cancer* 2009;101(1):48-54.
15. Attoub S, Rivat C, Rodrigues S, et al: The c-kit tyrosine kinase inhibitor STI571 for colorectal cancer therapy. *Cancer Res* 2002; 62:4879-4883.
16. Population based cancer registry, Mumbai, www.icmr.nic.in/ncrp/report
17. Toyota M, Hinoda Y, Takaoka A, et al. Expression of c-kit and kit ligand in human colon carcinoma cells. *Tumour Biol* 1993; 14:295-302.
18. Raihanatou Diallo, Achim Rody, Kenneth R. Shroyer et al. C-Kit expression in ductal carcinoma in situ of the breast: co expression with Her-2/neu. *Human Pathology* 2006; 37: 205-211
19. Zhen -Hua Lin, Eun Mee Han, Young-Sik Kim, et al. A distinct expression pattern and point mutation of c-Kit in papillary renal cell carcinomas. *Modern pathology* 2004; 17: 611-616.
20. Snigdha Poddar, Lawrence D' Cruze, Devaraj Halagowder. Expression of proto oncogene c-Kit and cancer associated fibroblasts are associated with metastatic potential of human gastric cancer. *Innovative journal of medical and health science* 2015;5:2: 53-60.
21. Nadia Peparini, Roberto Caronna, Guglielmo Tellan et al. Expression of receptors tyrosine kinase c-kit and EGF-R in colorectal adenocarcinomas: is there a relationship with epithelial-mesenchymal transition during tumor progression? *Langenbeck's Archives of Surgery* 2009; 1131-1132.
22. Reed J, Ouban A, Schickor FK, et al. Immunohistochemical staining for c-kit (CD117) is a rare event in human colorectal carcinoma. *Clin Colorectal Cancer* 2002; 2:119-122.
23. Rebecca Yorke, Minnie Chirala, Mamoun Younes. c-Kit Proto-Oncogene Product Is Rarely Detected in Colorectal Adenocarcinoma. *Journal of Clinical Oncology* 2003;21: 3885-3889.
24. Akintola-Ogunremi O, Pfeifer JD, Tan BR, et al. Analysis of protein expression and gene mutation of c-kit in colorectal neuroendocrine carcinomas. *Am J Surg Pathol* 2003; 27(12):1551-8.
25. Sammarco I, Capurso G, Coppola L, et al. Expression of the proto-oncogene c-KIT in normal and tumor tissues from colorectal carcinoma patients. *Int J Colorectal Dis.* 2004; 19(6):545-53.
26. Christian F Singer, Gernot Hudelist1, Wolfgang Lamm, et al. Expression of tyrosine kinases in human malignancies as potential targets for kinase-specific inhibitors. *Endocrine-Related Cancer* 2004; 11: 861-869.
27. Bellone G, Smirne C, Carbone A, et al. KIT/stem cell factor expression in premalignant and malignant lesions of the colon mucosa in relationship to disease progression and outcomes. *Int J Oncol* 2006;29(4):851-859.
28. Ana Preto , Cátia Moutinho, Sérgia Velho, et al. A subset of colorectal carcinomas express c-KIT protein independently of BRAF and/or KRAS activation. *Virchows Archiv* 2007, 450(6) 619-626.
29. Jan Friederichs, Claus W. H. von Weyhern, Robert Rosenberg, et al. Immunohistochemical detection of receptor tyrosine kinases c-kit, EGF-R, and PDGF-R in colorectal adenocarcinomas. *Langenbeck's Archives of Surgery* 2010;395: 373-379.
30. Mostafa M. El-Serafi MD, Abeer A. Bahnassy MD, PhD, Salem M. Eid MD, et al. The prognostic value of c-Kit, K-ras codon 12, and p53 codon 72 mutations in Egyptian patients with stage II colorectal cancer. *Cancer* 2010; 116: 4954-4964.