

Adenocarcinoma of intestinal type arising in mature cystic teratoma of ovary in a young female: An incidental finding

Sunitha S.¹, Arundhathi S.^{2*}, Anil Malleshi Betigeri³

^{1,3}Consultat Pathologist, Columbia Asia Hospital, Hebbal, Bangalore, ²Assistant Professor, Dept. of Pathology, Sanjay Gandhi Institute of Trauma & Orthopedics

***Corresponding Author:**

Email: arundhathi19@yahoo.co.in

Abstract

Mature cystic teratoma (MCT) is commonest germ cell tumor of ovary. In 1-2% of MCTs malignant transformation is known to occur. Most of the malignancies originating from MCTs are squamous cell carcinomas and adenocarcinomas of intestinal type are exceptionally rare. Nine cases have been reported till date and we are presenting this case because of its rarity and unusual presentation. We are presenting a case of 33 year old female with abdominal mass and raised CEA and CA-125. Histopathology and immunohistochemistry confirmed the diagnosis as adenocarcinoma of intestinal type arising in mature cystic teratoma.

Keywords: Mature Cystic Teratoma, Malignant Transformation, Adenocarcinoma.

Introduction

Mature cystic teratomas (MCTs) are common benign tumors of ovary originating from germ cell. Malignant transformation in MCT is extremely rare with an estimated incidence of 1-2% and occurring predominantly in elderly women. Studies have shown that majority of the malignancies originating from MCTs are squamous cell carcinomas and adenocarcinomas of intestinal type are exceptionally rare.⁽¹⁾ Nine cases have been reported till date and we are presenting this case because of its rarity and unusual presentation.

Case Report

A 33 year old female presented with palpable abdominal mass since six months. Computed tomography (CT) showed large abdomino- pelvic predominantly cystic mass arising from left ovary with enhancing solid areas, septations, well defined area of fat density and speck of calcification. Radiologically the impression was of an immature teratoma. Tumor marker analysis showed a rise in carcinoembryonic antigen (CEA) [9.12ng/ml, normal < 3ng/ml] and CA-125 [64.0U/ml, normal- < 35.0U/ml] and normal alpha fetoprotein (AFP) [1.29ng/ml, normal: 0-9ng/ml]. Routine hematological parameters were within normal limits.

The patient was posted for debulking surgery. Debulking surgery was done and sent for histopathological examination. The left ovariectomy specimen measured 21x18cms. Cut section showed a multiloculated cyst filled with mucoid material. Also seen was focal solid area measuring 5x4 cms with necrosis. Pultaceous material with tuft of hair was noted in one of the locules.

Haematoxylin and eosin (H & E) stained sections showed a cyst lined by keratinizing stratified squamous epithelium and intestinal type columnar epithelium with occasional goblet cells. Subepithelium showed smooth

muscle bundles with fibrocollagenous tissue. At places columnar epithelium showed hyperplasia, stratification and papillary architecture (Fig. 1 & Fig. 2). The cells were pleomorphic with prominent nucleoli. Also seen were large mucin pools with signet ring cells (Fig. 3). Areas of necrosis were also noted. Immunohistochemistry (IHC) showed that CK20 (Fig. 4) was strongly positive and CK7 was negative (Fig. 5) in tumor cells. The patient was referred to the oncologist for further treatment but she was lost to follow-up.

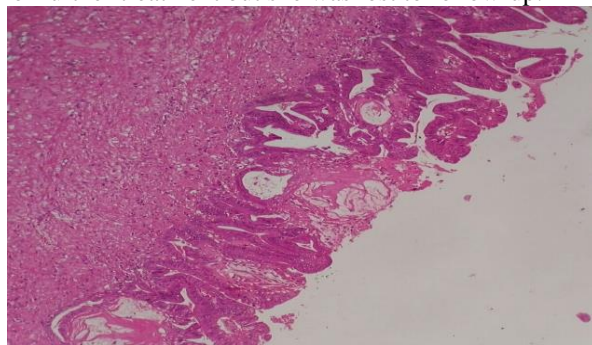


Fig. 1: Mucin secreting hyperplastic and dysplastic columnar epithelium with mucin pools (H & E, 10X)

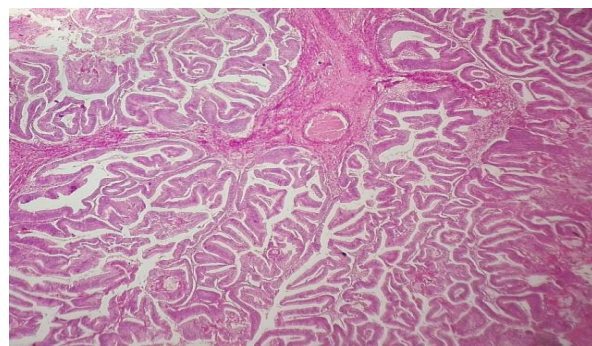


Fig. 2: Tumor with papillary architecture (H & E, 10X)

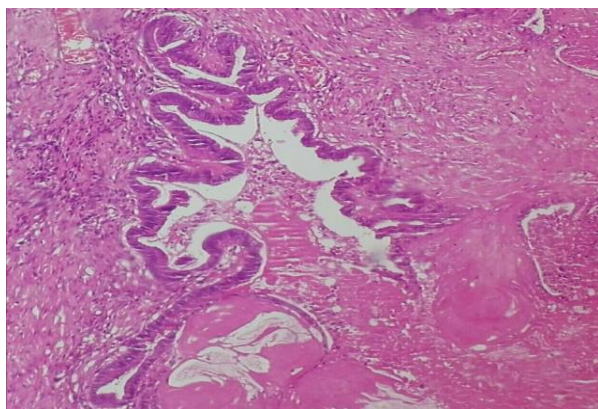


Fig. 3: Invasive foci with mucin pools (H & E, 40X)

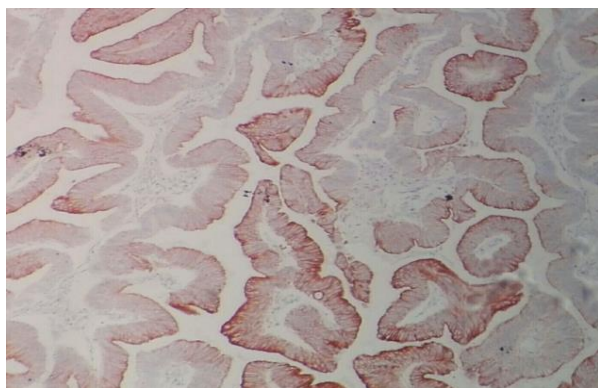


Fig. 4: CK20 strongly positive in tumor bulk

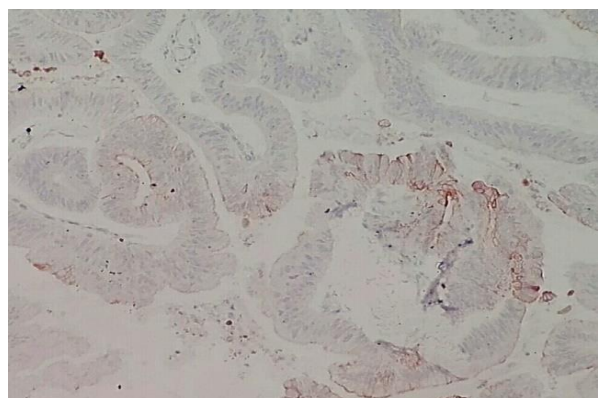


Fig. 5: CK7 negative in tumor bulk

Discussion

Mature cystic teratomas (MCTs) are the frequent germ cell tumors of ovary accounting for 18% of ovarian

neoplasms.⁽¹⁾ In 1-2% of MCTs malignant transformation is known to occur.⁽²⁾ Squamous cell carcinoma is the common malignancy arising from MCTs and adenocarcinomas are rare and account for 7% of malignant tumors.⁽³⁾ Among adenocarcinomas in ovary arising from MCT, gastrointestinal type is extremely rare and literature search revealed only a few cases being reported till date.⁽⁴⁾

There has been many hypothesis proposed about origin of MCT and malignant transformation occurring in them. The widely accepted hypothesis suggests that MCTs occur as a result of failure of first meiotic division.⁽¹⁾ Amanjit et al. suggested that long standing MCT could be a reason for malignant transformation and pathogenesis is unclear and its not known whether malignant transformation occurs separately or co- exists with MCT.⁽⁵⁾

MCTs in females younger than 30 years of age are mostly benign and malignant transformation is common in postmenopausal females.⁽⁶⁾ But, gastrointestinal type of adenocarcinoma originating from MCTs occur at younger age compared to other histological types.⁽¹⁾ Adenocarcinomas though rare is the second common malignancy associated with MCTs and account for 6.8% of malignant transformation.⁽⁷⁾ But, gastrointestinal type of adenocarcinomas associated with MCTs are exceptionally rare and literature search revealed nine cases reported till date.⁽⁸⁾ We report this case because of its rarity.

Immunohistochemistry (IHC) is useful in such tumors. In intestinal type adenocarcinoma arising in MCT, CK20 is consistently strongly positive and CK7 is most of the times negative. This is in contrast with mucinous tumors of ovary which are strongly CK7 positive and CK20 negative. These IHC findings prompt that the least common primary mucinous tumours of ovary have strong CK20 staining and partial or negative CK7 staining and they represent tumors of germ cell origin and not the surface epithelium.⁽⁸⁾ Our IHC findings were consistent with Clark ME et al.⁽⁸⁾

This case is presented because of its rarity and to also stress on the utility of simple IHC markers like CK7 and CK20 to distinguish mucinous neoplasms arising from germ cell epithelium and surface epithelium. This case also emphasizes that adenocarcinoma as a malignant transformation can be seen originating from MCT in young and this has to be considered as one of the differential diagnosis.

Table 1: List of adenocarcinomas arising from MCTs reported so far in literature

Case	Authors, year	Age in years	CA125	CEA	Histology
1	Park et.al.2008	41	45	41.8	Mucinous
2	Kajo et.al. 2013	38	550	32.9	Mucinous
3	Fishman et.al.1998	38	80	40	Adenocarcinoma
4	Park et.al. 2008	71	-	-	Adenocarcinoma
5	Park et.al. 2008	44	-	-	Adenocarcinoma
6	Yamaguchi et.al. 2008	48	1,276	12.3	Clear cell carcinoma

7	Black et.al. 2015	65	-	-	Mucinous
8	Black et.al. 2015	58	-	-	Mucinous
9	Miyasaka A et.al. 2016	59	156	16	Mucinous
10	Present case, 2017	33	9.12	64	Adenocarcinoma

Conclusion

In 1-2% of MCTs malignant transformation is known to occur. Most of the malignancies originating from MCTs are squamous cell carcinomas and adenocarcinomas of intestinal type are exceptionally rare. Nine cases have been reported till date and we are presenting this case because of its rarity and unusual presentation.

References

1. Masaaki Takai, Masanori Kanemura, Hiroshi Kawaguchi, Satoe Fujiwara, Saha Yoo, Yoshimichi Tanaka, et.al. Mucinous adenocarcinoma of the intestinal type arising from mature cystic teratoma of the ovary: a rare case report and review of the literature. *Journal of Ovarian Research* 2012;5:41.
2. Peterson WF: Malignant degeneration of benign cystic teratomas of the ovary; a collective review of the literature. *Obstet Gynecol Surv* 1957,12:793–830.
3. Ueda G, Fujita M, Ogawa H, Sawada M, Inoue M, Tanizawa O: Adenocarcinoma in a benign cystic teratoma of the ovary: report of a case with a long survival period. *Gynecol Oncol* 1993,48:259–263.
4. Min KJ, Jee BC, Lee HS, Kim YB: Intestinal adenocarcinoma arising in a mature cystic teratoma of the ovary: a case report. *Pathol Res Pract* 2006,202:531–535.
5. Bal A, Mohan H, Singh SB, Sehgal A: Malignant transformation in mature cystic teratoma of the ovary: report of five cases and review of the literature. *Arch Gynecol Obstet* 2007,275:179–182.
6. Koonings PP, Campbell K, Mishell DR, Grimes DA: Relative frequency of primary ovarian neoplasms: a 10-year review. *Obstet Gynecol* 1989,74:921–926.
7. Fishman A, Edelstein E, Altaras M, Beyth Y, Bernheim J. Adenocarcinoma arising from the gastrointestinal epithelium in benign cystic teratoma of the ovary. *Gynecol Oncol* 1998;70:418-420.
8. Clark ME, Will MD. Intestinal-Type Adenocarcinoma Arising in a Mature Cystic Teratoma of the Ovary. *Int J Gynecol Pathol*. 2016 Jul;35(4):352-6.