

## Histomorphological study of various patterns in breast lesions, including carcinoma breast

Zeenath Begum<sup>1,\*</sup>, Mandakini B. Tengli<sup>2</sup>, S. Mahantappa<sup>3</sup>, Farheen<sup>4</sup>, Abdul Lateef<sup>5</sup>

<sup>1</sup>Professor, <sup>2</sup>Associate Professor, <sup>3</sup>Professor & HOD, <sup>4</sup>P.G. Student, <sup>5</sup>Technician, Dept. of Pathology, KBNIMS Rajiv Gandhi University

**\*Corresponding Author:**

Email: drzeenta@yahoo.com

### Abstract

#### Aims and Objectives:

- 1) To study the prevalence of breast diseases, and
- 2) To study the histological patterns in inflammatory breast diseases, benign and malignant lesions of breast.

**Materials and Method:** The present study includes 70 cases from January 2012 to June 2016. The specimens were received in different forms such as excision biopsies, modified radical mastectomies and simple mastectomies. Samples were received from KBN Hospital Gulbarga, to department of Pathology KBNIMS Gulbarga. Detailed gross and microscopic examination was done for each specimen.

**Results:** During four and a half year study period, out of 70 cases, 51 were benign lesions (constituting 72.85% of total breast lesions). The mean age for benign diseases of breast was 22.5 years and the age range 10 – 50 years and 19 were malignant lesions. Eight cases (42.10%) were below the age of 40 years, with an age range of 20- 80 years. Most common benign breast disease of breast was fibroadenoma (45.71%) (Most common histologic change is that of intracanalicular pattern), followed by lactating adenoma (histologic change related to the stage of pregnancy). Other major lesions encountered were, benign phyllodes (a leaf-like growth pattern of stroma), fibrocystic disease of breast (fibrosis, cyst formation), sclerosing adenosis (increased number of distorted lobules, associated with stromal fibrosis), granulomatous mastitis (composed of non-caseating granulomas, giant cells, and foamy histiocytes) and duct ectasia (dilated duct and lymphoplasmacytic infiltrate). Malignant breast lesions were 27.15% of all breast lesions. The most common type of malignancy was infiltrating duct carcinoma- not otherwise specified (84.2%), followed by medullary carcinoma (5.26%), invasive lobular carcinoma (5.26%), and intra- ductal carcinoma (5.26%).

**Conclusion:** Although benign breast diseases constituted 72.85% of all breast diseases and were mostly fibroadenomas, however, the incidence of malignancy was 27.15%. All breast lesions should be seriously examined because identification of benign lesions like duct ectasia, sclerosing adenosis and granulomatous mastitis is important as they simulate malignancy.

**Keywords:** Benign Breast Diseases, Fibroadenoma, Fibrocystic Disease, Carcinoma Breast.

### Introduction

Presence of lump in the breast causes anxiety, and apprehension in every woman. This may be attributed to the increasing public awareness of breast cancer which is presently the most common female malignancy worldwide.<sup>(1)</sup>

In India, breast cancer forms the second common malignancy next to cervical cancer and is detected in 20 per 1,00,000 women.<sup>(2)</sup>

A vast majority of breast lesions are benign.<sup>(3)</sup> Benign breast diseases, however, constitute a heterogeneous group of disorders including developmental abnormalities, epithelial and stromal proliferations, inflammatory lesions, and various neoplasms.<sup>(4)</sup>

**Fibroadenoma:** Fibroadenoma of the breast is a relatively frequently occurring tumor. It can occur in women of any age but the peak incidence is during the second and third decades of life. Fibroadenoma is a biphasic tumor, comprising of an epithelial and a stromal component.

The incidence of apocrine metaplasia and sclerosing adenosis in fibroadenoma has been reported to be 14% and 6% respectively.

**Phyllodes tumor:** was distinguished from fibroadenoma using Rosen's criteria, i.e. stromal overgrowth, with leaf-like pattern and increased cellularity, greatest in the subepithelial stroma, and stromal mitoses. (Magnification x400, ± 1.6 mm).<sup>(2)</sup>

Finally, based on the growth pattern, fibroadenomas were classified as peri-canalicular and intra-canalicular.<sup>(5)</sup>

**Lactating adenoma:** Lactating adenoma is a rare breast tumor, most often associated with pregnancy. According to Slavin et al, lactating adenomas are nodules of physiologic, focal, exaggerated lobular proliferation, which become more prominent than the adjacent breast tissue and appear clinically to be a distinct mass.<sup>(6)</sup>

**Fibrocystic disease:** The relationship of cystic disease and breast cancer has been the subject of numerous studies, and there is a consensus that, patients with benign proliferative breast lesions have an increased incidence of breast cancer. It is difficult to decide which of the many histologic features of cystic disease is most important in determining the precancerous potential.<sup>(7)</sup>

**Sclerosing adenosis:** is a proliferative lesion that is commonly found in benign breast lesions. It is a histologically complex entity that consists of enlarged and distorted lobules, containing duplicated and crowded

acini, with predominant myoepithelial component and stromal fibrosis.<sup>(8)</sup>

**Duct ectasia:** is an inflammatory condition of unknown cause, previously called plasma cell mastitis, mastitis obliterans or comedomastitis. Inflammation is entirely surrounding the ducts i.e. periductal mastitis. In the early stage there is dilatation of the ducts, which get filled with eosinophilic amorphous granular proteinaceous material. If the duct ruptures, there is spillage of the material giving inflammatory reaction of lymphocytes, plasma cells, neutrophils and foamy macrophages. The ductal epithelium shows atrophy rather than hyperplasia.<sup>(2)</sup>

**Granulomatous mastitis:** is a rare benign disease of unknown etiology occurring in parous women with an antecedent recent pregnancy. On histopathology, inflammatory infiltrate shows predominantly lobular distribution. The infiltration is composed of non-caseating granulomas, Langhan giant-cells, foamy histiocytes and intense polymorphonuclear cells.<sup>(2)</sup>

**Ductal carcinoma in-situ:** Proliferation of pleomorphic epithelial cells within the thick-walled ducts of the breast. There is no light microscopic evidence of invasion through the basement membrane into the surrounding stroma. Such lesion is known as ductal carcinoma in-situ (DCIS). Several morphologic patterns of DCIS are recognized, the most common of which are comedo, cribriform, papillary, solid and micropapillary. DCIS- Comedo is diagnosed when atleast one duct is filled and expanded by large, markedly atypical cells and has abundant central luminal necrosis.<sup>(9)</sup>

**Invasive ductal carcinoma breast:** also known as infiltrating ductal carcinoma (IDC): is the most common form of breast cancer. These are adenocarcinomas that fail to exhibit sufficient characteristics to warrant their classification in one of the special type.<sup>(10)</sup> IDC starts in breast milk-ducts and invades the surrounding breast stroma.<sup>(11)</sup>

**Medullary breast carcinoma (MBC):** is a rare histological type of breast cancer, accounting for 1% to 7% of all breast cancers. In 1945, Moore and Foote described the definitive characteristics of MBC which include, heavy lymphoplasmacytic infiltration, non-invasive sharp circumscription, growth in sheets (syncytia pattern) hemorrhagic necrosis, poorly-differentiated nuclear grade and a high mitotic rate. Some researchers,

however, have questioned the prognosis and morphologic definition of MBC. Ridolfi et al. [7] reassessed MBC and documented strict criteria for diagnosing typical and atypical MBC. Atypical MBC differs from typical MBC in terms of pathologic features with an infiltrative margin, mild mononuclear infiltration, a low nuclear-grade, and presence of an intraductal component.<sup>(12)</sup>

**Lobular carcinoma:** The morphologic features that distinguish lobular carcinoma from ductal carcinoma are two-fold.

- I. The cells are monotonous and discohesive with prominent intracytoplasmic mucin vacuoles.
- II. The pattern of invasion is frequently in a single-file arrangement with a targetoid growth pattern around terminal ducts and lobules in a concentric fashion.<sup>(13)</sup>

### Aims and Objectives

To delineate the prevalence and characterize the histologic pattern of breast diseases including inflammatory, benign, and malignant lesions of the breast.

### Materials and Method

The present study includes, 70 cases, from January 2012 to June 2016. The specimens were received in different forms such as excision biopsies, modified radical mastectomies and simple mastectomies. Samples were received from KBN Hospital Gulbarga to KBNIMS, department of pathology, Gulbarga. Detailed gross and microscopic examination was done for each specimen.

### Results

During four and a half year study period, 51 cases of benign breast lesions, constituting 72.85% of all breast lesions, were studied. The overall mean age for benign breast diseases, was 22.5 years, with an age range of 10 – 50 years, and for malignancies, out of 19 cases, eight(42.10%) were below the age of 40 years, with an age range of 20- 80 years (Table 1). Most common lesion was fibroadenoma (45.71%) (Table 2).

Table 1

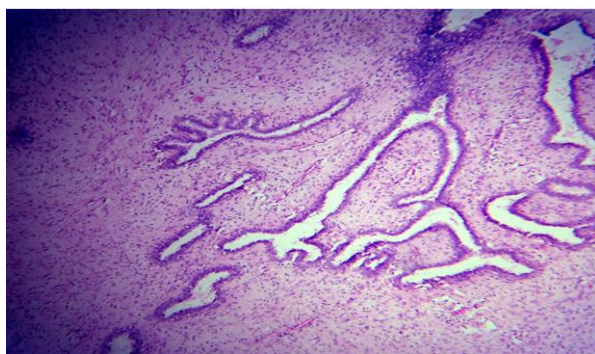
Histopathological diagnosis	No. of cases	Percentage
<b>I. Benign Group</b>		
1. Fibroadenoma	32	45.71%
2. Fibrocystic disease	4	5.7%
3. Sclerosing adenosis	2	2.85%
4. Lactating Adenoma	5	7.14%
5. Chronic granulomatous mastitis	2	2.85%
6. Duct ectasia	1	1.42%
7. Phyllodes	5	7.14%
Total	51	72.85%

<b>II. Malignant group</b>		
1. Intraductal carcinoma breast	1	5.3%
2. Infiltrating duct carcinoma	16	84.2%
3. Invasive Lobular carcinoma	1	5.3%
4. Medullary carcinoma	1	5.3%
Total	19	27.15%

Table 2

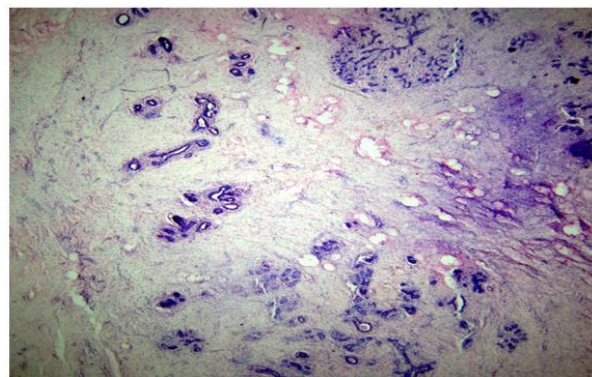
Name of lesions	Age groups						
	10-20 Years	21-30 Years	31-40 Years	41-50 Years	51-60 Years	60-70 Years	70-80 Years
Fibroadenoma	14	9	9	Nil	Nil	Nil	Nil
Lactating adenoma	01	04	Nil	Nil	Nil	Nil	Nil
Phyllodes	01	Nil	03	01	Nil	Nil	Nil
Fibrocystic disease	Nil	03	01	Nil	Nil	Nil	Nil
Sclerosing adenosis	Nil	01	01	Nil	Nil	Nil	Nil
Granulomatous mastitis	Nil	02	Nil	Nil	Nil	Nil	Nil
Duct ectasia	Nil	Nil	01	Nil	Nil	Nil	Nil
Intraductal carcinoma breast	Nil	Nil	01		Nil	Nil	Nil
Infiltrating ductal carcinoma	Nil	01	06	Nil	08	Nil	01
Medullary carcinoma breast	Nil	Nil	Nil	Nil	01	Nil	Nil
Invasive lobular carcinoma	Nil	Nil	Nil	Nil	01	Nil	Nil

**Fibroadenoma (Fig. 1):** Fibroadenomas displayed histological patterns like intra- canalicular (25%), pericanalicular (47%), complex features like apocrine metaplasia (50%), sclerosing adenosis (25%), Sclerosing adenosis with cyst formation (25%) and phyllodes in one case of fibroadenoma (3%).



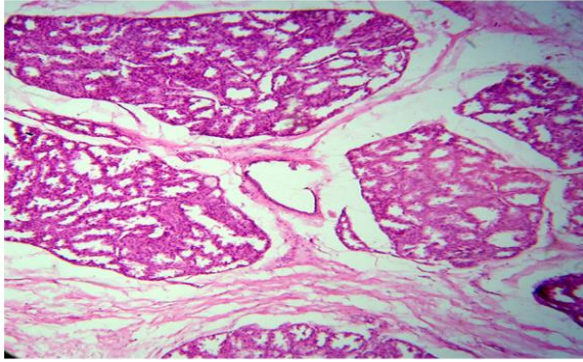
**Fig. 1: Fibroadenoma Breast (H&E stain) (10X Magnification)**

**Sclerosing adenosis without fibroadenoma (Fig. 7):** observed in 2.85% of breast biopsies. Histological features in all cases consisted of distorted lobules, overcrowded acini and stromal fibrosis.

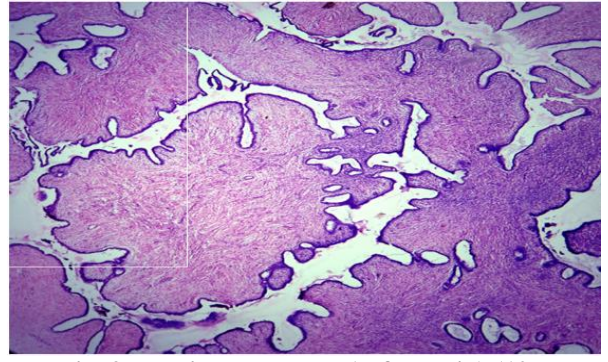


**Fig. 7: Sclerosing Adenosis (H&E stain) (10X Magnification)**

**Lactating adenoma (Fig. 6):** 7.12% of cases were lactating adenomas. Histological features were lobular expansion, containing increased numbers of acini, many of which were enlarged and dilated, consistent with epithelial cell enlargement, cytoplasmic vacuolization and a hob-nail appearance with protrusion of cells into the acinar lumen.

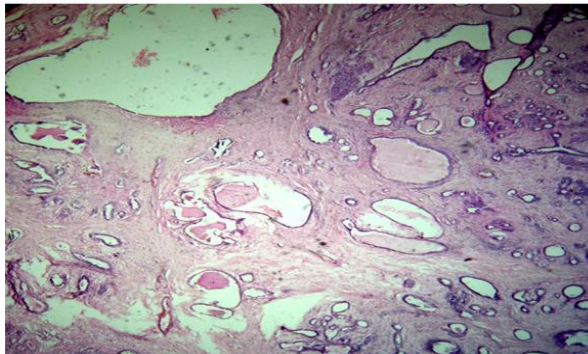


**Fig. 6: Lactating Adenoma (H&E stain) (10X Magnification)**

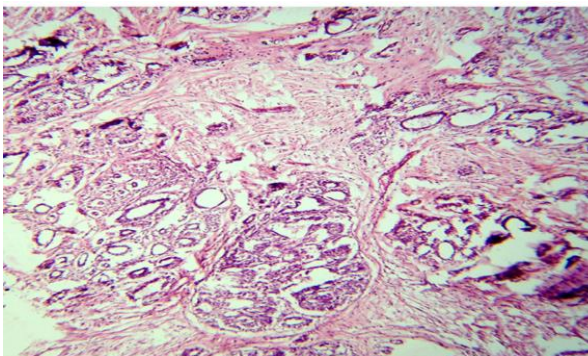


**Fig. 2: Benign Phyllodes (H&E stain) (10X Magnification)**

**Fibrocystic disease of breast (Fig. 3, 4):** out of 70 breast lesions, four were diagnosed as fibrocystic, with one in each group I, II, III and IV.



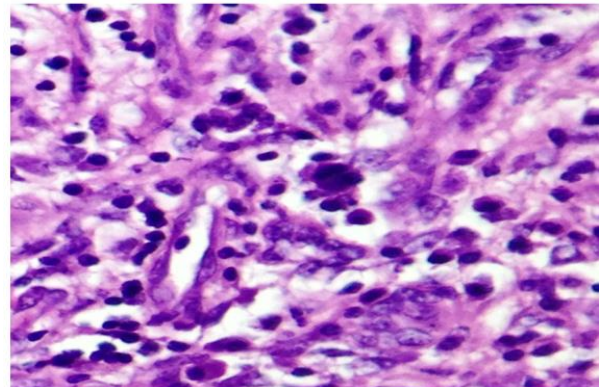
**Fig. 3: Fibrocystic disease of breast (H&E stain) (10X Magnification)**



**Fig. 4: Adenosis in Fibrocystic disease (H&E stain) (10X Magnification)**

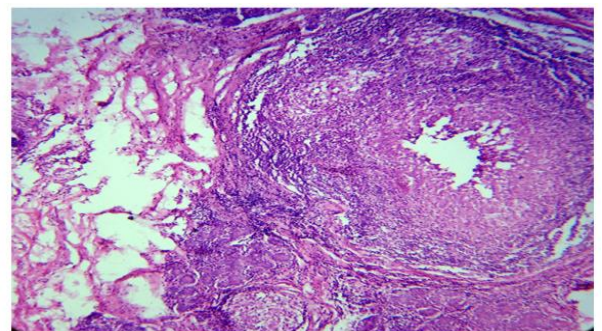
**Phyllodes (Fig. 2):** we reported 5 cases (7.14%) of benign phyllodes, a biphasic tumor with hypercellular, benign mesenchymal component, organized in leaf-like pattern around benign epithelium.

**Mammary duct ectasia (Fig. 10):** we reported mammary duct ectasia in only 1.42% of all breast lesions. Microscopically, dilated ducts and periductal chronic inflammatory cells infiltrate composed of lymphocytes and plasma cells were seen.

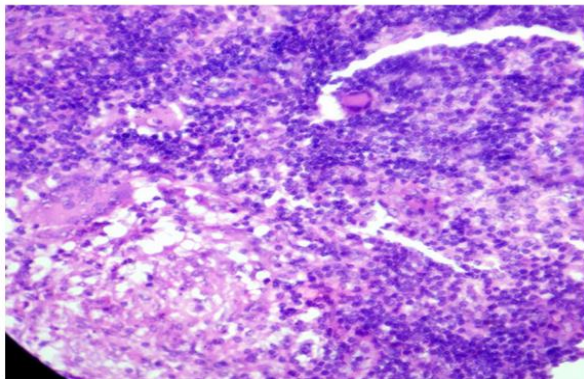


**Fig. 10: Plasma cells in Duct Ectasia (H&E stain) (40X Magnification)**

**Granulomatous mastitis (Fig. 8, 9):** we reported two cases of granulomatous mastitis (2.85%) histopathologically composed of epithelioid cells, lymphocytes and giant cells. Ziehl-Neelsen stains were negative.

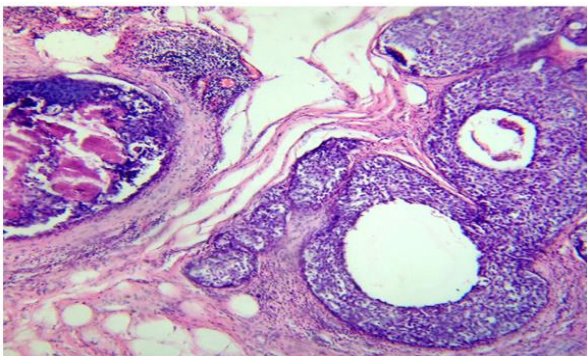


**Fig. 8: Granulomatous mastitis (H&E stain) (10X Magnification)**



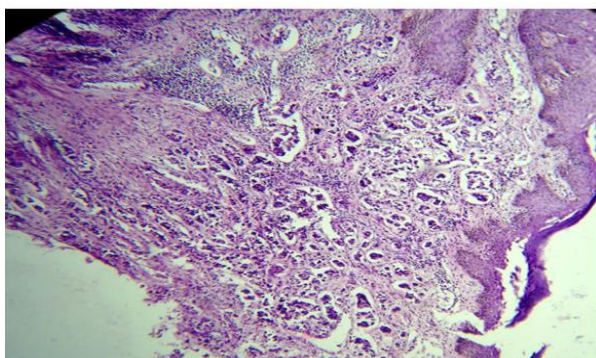
**Fig. 9: Granulomatous mastitis (H&E stain) (40X Magnification)**

**Ductal carcinoma in situ (Fig. 11):** DCIS was detected in only one out of 19 carcinomas (5.32%). The incidence may be because of small sample size. Morphological features were, proliferation of malignant epithelial cells with no evidence of invasion across the basement membrane, with central comedo- necrosis.

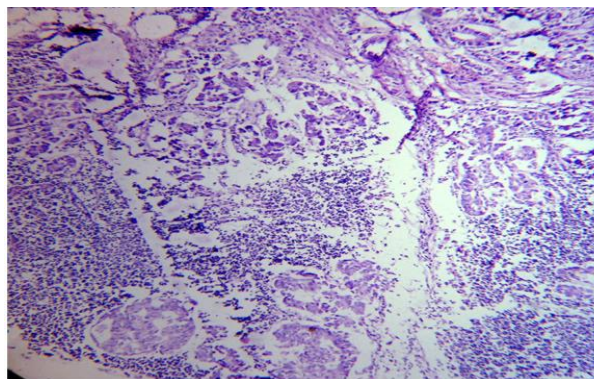


**Fig. 11: Intraductal Carcinoma Breast (H&E stain) (40X Magnification)**

**Infiltrating duct carcinoma breast (IDC) (Fig. 12):** we reported 19(27.15%) cases of carcinoma breast. IDC was the most common (84.2%), having morphology of tumor cells arranged in various patterns like sheets, ducts, single cells and tubules. 40% of the cases showed metastasis to axillary lymph node (**Fig. 15**).



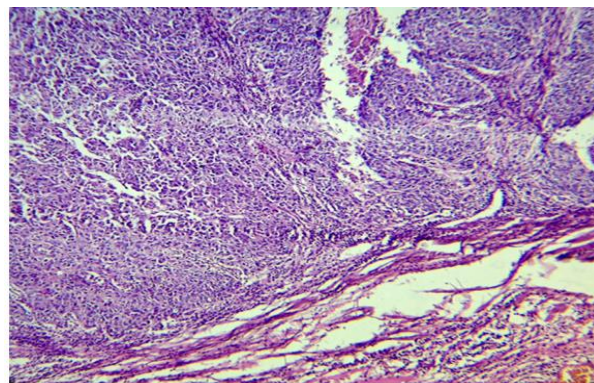
**Fig. 12: Infiltrating ductal Carcinoma Breast (H&E stain) (10X Magnification)**



**Fig. 15: Metastasis to axillary lymph node (IDC) (H&E stain) (10X Magnification)**

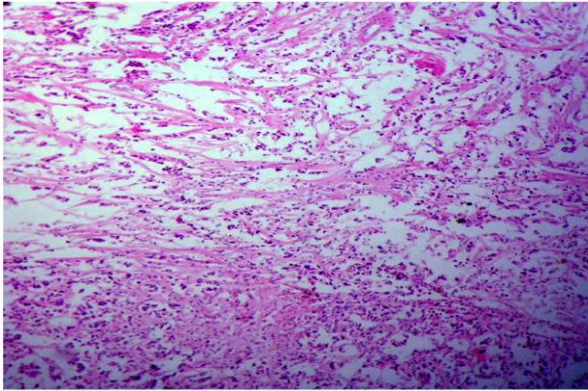
**Medullary carcinoma (Fig. 14):** out of 4 types of malignancy accounting to 19 total cases, one (1.42%), was medullary carcinoma. The following histological features were associated with this carcinoma.

- 1) Prominent lymphocytic infiltration,
- 2) Anastomosing sheets,
- 3) Absence of fibrosis,
- 4) Absence of infiltrative margin, and
- 5) Absence of gland formation.



**Fig. 14: Medullary Carcinoma Breast (H&E stain) (40X Magnification)**

**Invasive lobular carcinoma (Fig. 13):** we reported only one case (5.3%) of invasive lobular carcinoma breast having monotonous and discohesive cells arranged in single- file pattern.



**Fig. 13: Invasive lobular carcinoma breast (H&E stain) (10X Magnification)**

### Discussion

Breast lesions cause health and cosmetic hazards. There is lot of anxiety and fear associated with increased awareness of breast cancer. This has significantly improved the health seeking behavior of patients with breast lumps. This may be the reason for increasing incidence of benign breast lesions observed in this study. Previous reports indicate that the incidence of benign disease is more than that of breast cancer. In separate studies by Enugu, Kano, Calalar, Ugiagbe E.E and Ibadan, benign diseases accounted for 68.8, 73, 73.4, 72.5 and 89.4% of all breast lumps respectively.<sup>(14)</sup> This was also our observation.(Table 3).

Benign breast lesions were systematically classified according to the criteria of Dupont and Page into one of the following general categories: non-proliferative changes (NP), proliferative disease without atypia (PDWA), and proliferative disease with atypia (atypical ductal hyperplasia [ADH], atypical lobular hyperplasia [ALH], or both).<sup>(8)</sup>

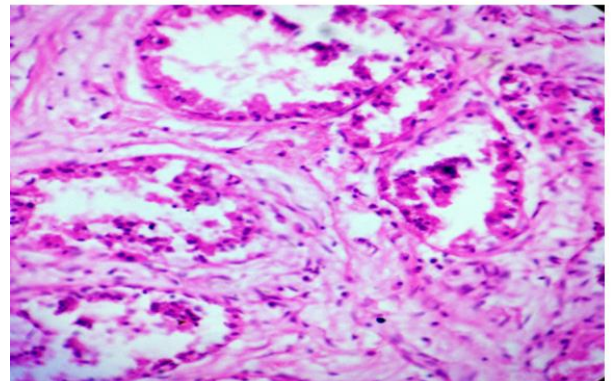
Fibroadenomas displayed histological patterns like intracanalicular (25%) pericanalicular (47%), complex features (8 cases) like apocrine metaplasia (50%) sclerosing adenosis (25%), features of sclerosing adenosis and cyst formation observed in two cases (25%), phyllodes in one case of fibroadenoma (3%); whereas, in a study by Kuijper A, Ellen C M, Mommers, Wall E V D, J Paul discovered apocrine metaplasia (28%) sclerosing adenosis (12.4%) cysts (5.1%), and phyllodes (1.2%).

Sclerosing adenosis, though a common benign breast lesion,<sup>(8)</sup> we discovered in only 2.85% of breast biopsies and in 25% of all fibroadenomas as a complex feature.

Lactating adenomas are small, well-circumscribed, freely mobile masses which may be seen during pregnancy or lactation. Benign breast tumors associated with pregnancy, can be of different types. O' Hara et al, detected eight cases of lactating adenomas, out of 37 cases of benign breast tumours associated with pregnancy. In our study, only 5 (7.12%) cases were lactating adenomas. Lactating adenoma is a rare tumor

and there are differing views on its histogenesis. James et al considered lactating adenoma to be a pure and readily recognizable morphological form, clearly distinguishable from tubular adenoma and fibroadenoma that is always related to current or recent pregnancy. They proposed the name "tumor of pregnancy". The microscopic finding in our cases is in accordance with this view. This is also supported by Slavin et al, who in a study of 30 cases of nodular breast lesions of pregnancy, described 12 lesions that fitted with the description of lactating adenoma.

Fibrocystic disease of breast, the minimal lesion (Group 1), there will be destruction of scattered ductules in normal lobules, associated by lymphocytic infiltrates. The epithelium of segmented lobular units may proceed to atrophy or undergo metaplasia with cyst formation. Cases with predominant atrophic lesions (Group 2) include "fibrous disease" of breast. Cases with predominance of epithelia I metaplasia and cyst formation (Group 3 and 4) correspond to fibrocystic disease. Epithelial metaplasia like apocrine metaplasia, and mucinous metaplasia (small eosinophilic intracytoplasmic secretion) could be seen.<sup>15</sup> The apocrine metaplasia was the only metaplasia seen in our study (Fig. 5).



**Fig. 5: Apocrine change in Fibrocystic disease (H&E stain) (40X Magnification)**

Phyllodes tumors are rare fibroepithelial lesions that account for less than 1% of all breast neoplasms, first described by Johannes Muller in 1838. Microscopically tumors are characterized by epithelial spaces into which projects a hypercellular stroma. The stroma is the neoplastic component and determines the pathological behavior, with reference to the widely accepted definition as proposed by Azzopardi and Salvadori et al. All five cases we reported, were of benign histological type.<sup>(16)</sup>

Mammary duct ectasia was described by Haagensen as a benign condition with the histological changes of major duct dilatation associated with periductal fibrosis or chronic inflammation. We observed same histologic features which is also reported by Webb AJ.<sup>(17)</sup> Chronic inflammation is because of the leakage of duct contents

into the surrounding stroma.<sup>(18)</sup> The incidence of mammary duct ectasia is 4%.<sup>(17)</sup>

Granulomatous mastitis is characterized by the presence of granulomatous inflammation (idiopathic) and is diagnosed by exclusion. These lumps clinically mimic carcinoma. A well -formed granuloma centered at terminal ducts and the lobules noted in the study by Chih- Hsun Lin and Chih-Wei Hsu<sup>(19)</sup> as well as mixed chronic inflammatory process composed of lymphocytes, plasma cells, epithelioid cells, multinucleated giant cells were noted. We observed the similar features in our study.

Among the malignant lesions, the commonest lesion was infiltrating duct carcinoma, having various morphological patterns, comprising 84.2%, similar to the study by Sangeeta K and Ila MV.<sup>(2)</sup>

Ductal carcinoma in- situ (DCIS): DCIS has become a formidable clinical challenge due to its increasing incidence. DCIS accounts for approximately 20% of all breast cancers compared to 5% in our study .For several decades it has been accepted that DCIS constitutes a non-obligate precursor of invasive ductal carcinoma.<sup>(20)</sup> High- grade DCIS is often of solid architecture and does not show polarization of the cells. Usually there may be central (comedo type) necrosis with or without associated microcalcification.<sup>(21)</sup> We observed similar pathological features without calcification.

Foote and Stewart 8, 9 in 1941, described both the in-situ form of the disease, confined to the lobule and terminal ducts and the invasive form of lobular carcinoma. Reported incidence of invasive lobular carcinoma ranges from 0.6-20%.<sup>(13)</sup> In the present study, the proportion of lobular carcinoma is 1.42%.

Medullary carcinoma breast: incidence of this carcinoma in our study is 1.42% compared to 0.7% of study by Park I and Kim J et al.<sup>(12)</sup> A predominantly syncytial growth pattern in more than 75% of the tumor area, circumscription with a pushing margin, moderate to marked lymphoplasmacytic infiltration was the same observation made in this study, typical of medullary carcinoma breast.

## Conclusion

Although benign breast diseases constituted 72.85% of all breast diseases and were mostly fibroadenomas, however, the incidence of malignancy was 27.15%. All breast lesions should be seriously examined. Also identification of benign lesions like duct ectasia, sclerosing adenosis and granulomatous mastitis is important, as they simulate malignant lesions.

Although a diagnosis of breast cancer is distressing at any age, occurrence in young women is fraught with several unique challenges. Multivariate analysis has shown younger age to be an independent predictor of adverse outcome.

This article highlights the distinct incidence and pathological characteristics of wide range of breast diseases.

## References

1. Parkin DM, Bray F, Ferlay J, Pisani P. Global cancer statistics, 2002. *CA Cancer J Clin.* 2005;55:74-108.
2. Sangeeta K, Ila M V, Kanchanmala G G, Shanu S. *J Obstet Gynecol India* Vol. 59, No . 5: September/ October 2009 pg 444-452.

3. Yusuf LM, Odigie VI, Mohammed A. Breast masses in Zaria, Nigeria. *Ann Afr Med.* 2003;2:13-6.
4. Tavassoli FA, Devilee P. France: IARC; 2003. World Health Organization. Histological classification of tumors of the breast pathology and genetics of tumors of the breast and female genital organs.
5. Kuijper A, Ellen C M, Mommers, Wall E V D, J Paul, Diest V. Histopathology of fibroadenoma breast, *AM J Clin Pathol.* 2001;115:736-742.
6. Manipadam MT. Jacob A, Rajnikanth J. Giant Lactating adenoma of the breast. *JSCR.* 2010 9:8.
7. Ackerman, L. V.: *Surgical Pathology*, 4th ed. St. Louis, C. V. Mosby Co., Atypia in breast cancer and cystic disease 1968.
8. Daniel W. Visscher, Aziza Nassar et al. Sclerosing Adenosis and risk of breast cancer. *Breast Cancer Res Treat* (2014) 144:205–212.
9. Shahid Parvez, Hassan Khan. Infiltrating ductal carcinoma breast with central necrosis closely mimicking ductal carcinoma in situ (comedo type): a case series. *Journal of medical case reports* 2007, 1:83.
10. Weigelt B, Geyer F C, Reis-Filho J S. Histological types of breast cancer: How special are they? *Molecular Oncology* 4(2010)192-208.
11. Bhandari V, Gunasekaran G, Naik D, Yadav AK. Infiltrating ductal carcinoma of the breast presenting as breast abscess: A case report. *Natl J Med Res.* 2013;3(4):422-423.
12. Park I Kim J Kim M et al. Comparison of the characteristics of Medullary Breast Carcinoma and Invasive Ductal Carcinoma, *J Breast Cancer* 2013 December; 16(4):417-425.
13. Bane A L, Tjan S, Parkes R K, et al. Invasive Lobular carcinoma : to grade not to grade. *Modern pathology* (2005)18,621-628.
14. Ollu-Eddo A N, Ugaigbe E E. Benign breast lesions in an African population: A 25-year histopathological review of 1864 cases. *Niger Med J* 2011 OCT-DEC; 52(4):211-216.
15. Anastassiades O T, Tsakraklides E, Gogas J. The histology of fibrocystic disease of the female breast: correlation with epithelial proliferative lesion and carcinoma in- situ. *Pathology – Research and practice* 1981 July; 172(1-2):109-129.
16. Parker SJ, Harries SA. Phylloides tumours. *Postgrad Med J* 2001;77:428-435.
17. Browning J Bigrigg A Taylor I. Symptomatic and Incidental mammary duct ectasia. *Journal of the royal society of Medicine.* 1986 Dec; volume 79:715-716.
18. Timothy M, D' Alfonso, Ginter P S, Shin S J. A Review of inflammatory process of the breast with a focus on diagnosis in core biopsy samples. *Journal of Pathology and Translational Medicine* 2015;49:279-287.
19. Chih-Hsun Lin, Chih-Wei Hsu, Tsao T Y, Chou J. Idiopathic granulomatous mastitis associated with risperidone- induced hyperprolactinoma. *Diagnostic pathology* 2012;7:2.
20. Cowell C F, Weigelt B Sakr R A et al. Progression from ductal carcinoma in- situ to invasive breast cancer: Revisited. *Molecular oncology* 7 (2013)859-869.
21. Pinder Sarah E. Ductal carcinoma in- situ (DCIS): Pathological features, differential diagnosis, prognostic factors and specimen evaluation. *Modern Pathology* (2010)23, s8-s13.