

Organic causes of abnormal uterine bleeding-A clinico- pathological study based on PALM category of FIGO classification

Madhu Chaturvedi¹, Sangita Margam^{2*}, Shweta Azad³

¹Associate Professor, ²Assistant Professor, ³Ex-PG Student, Dept. of Pathology, Lokmanya Tilak Memorial Medical College, Sion, Mumbai

***Corresponding Author:**

Email: drsvgoyal@gmail.com

Abstract

Background: Abnormal uterine bleeding (AUB) is one of the most common debilitating menstrual problems and has remained one of the most frequent indications for hysterectomy in developing countries. The problem is common worldwide but causes may vary from one region to another. In about 25% of the patients, the abnormal uterine bleeding is the result of a well-defined organic abnormality.

Materials and Method: It was a five year study conducted at a tertiary care hospital, Mumbai. Total of 804 Women who underwent surgical resections and biopsies with complaints of AUB were included in the study and histopathological spectrum of structural pathology was determined.

Results: Most common age group affected was 36-45 years. Uterine corpus was common site of pathology (80.2%), followed by cervix (17.4%) Isolated pathology was found in 88.9% cases while multiple pathology in 10.1% cases. Benign pathology formed largest group (82.34%), commonest being leiomyoma (71.6%). Malignancy seen in 14.8% cases, most common malignancy being squamous cell carcinoma (72.72%). Menorrhagia was commonest presentation (64.6%), followed by postmenopausal bleeding (20%) & polymenorrhagia (14.6%). In postmenopausal age group, malignancy was (46.3%) more as compared to age <40 years (8.7%). Rare cases presenting as AUB were encountered viz. serous cystadenoma, mature cystic teratoma and serous cystadenocarcinoma of ovary, malignant mixed mullerian tumor of uterus, metastasis to uterine corpus, and small round cell tumor of cervix.

Conclusion: Frequency of benign endometrial pathology as underlying organic cause of AUB is quite high. However, histopathological spectrum in patients with AUB is quite variable with respect to age with increased chances of detecting malignancy in elder females. Therefore Histopathological examination of endometrium should be done generously in women presenting with abnormal uterine bleeding especially after the age of 40 years to rule out malignancy.

Keywords: Abnormal Uterine Bleeding, Structural Pathology, PALM Category, Uterus.

Introduction

Abnormal uterine bleeding (AUB) is a common reason for women of all ages to consult their gynaecologist.^(1,2) It is defined as changes in frequency of menstruation, duration of flow or amount of blood loss.^(3,4) A study based on epidemiology of menstrual disorders in developing countries revealed that the prevalence of AUB in developing countries was about 5-15%.^(5,6) It can be caused by a wide variety of both organic and non-organic causes that include female genital tract pathology, pregnancy related disorders, and systemic illnesses.⁽⁷⁾ This study was carried out to evaluate the prevalence and patterns of structural pathology and histological findings in female genital tract of women with AUB and to correlate these findings with clinical features.

Materials and Method

This is a 5 year study that included surgical resection and biopsy specimen of 804 patients with clinical diagnosis of AUB, at a tertiary care hospital, Mumbai.

Inclusion criteria:

- The samples included were simple hysterectomy, hysterectomy with bilateral/unilateral salpingo-

oophorectomy, polypectomy, endometrial and cervical biopsy.

- All benign, malignant, inflammatory lesions of uterine corpus, cervix, fallopian tube & ovary causing AUB were included.

Exclusion criteria:

- Patients with morphological evaluation of endometrium as proliferative phase, secretory phase & cystic glandular atrophy, on hormonal therapy, bleeding related to pregnancy complications or systemic causes like endocrinopathy, coagulopathy, drug intake were excluded from the study.

The specimen comprised of 670 surgical specimen and 134 biopsies (99 cervical and 35 endometrial biopsies). The specimens were processed in automated tissue processor. The sections were stained with Hemotoxylin and Eosin stain. Histopathological evaluation was done according to WHO fascicle of female genital tract⁽⁸⁾ & Bluestein's text book of pathology of female genital tract.⁽⁹⁾ PALM (Polyp, Adenomyosis, Leiomyoma & Malignancy and hyperplasia) classification was used to study various structural pathology.⁽¹⁰⁾ Data was analysed using the Statistical Package for Social Science (SPSS, version 15) & Microsoft excel.

Results

Of 4844 gynaecological resections and biopsies received, 4188 (86.4%) cases presented with AUB. Of these, 804 (19.2%) revealed structural pathology in female genital tract as cause of AUB. The common site of pathology was uterine corpus (80.2%) followed by uterine cervix (17.4%). Distribution of the cases based

on the site involved and type of pathology is given in Table 1. Majority of cases (89.9%) revealed single pathology in their genital tract, but in 10.1% cases multiple lesions were detected simultaneously in multiple or single organs of female genital tract, most common association being leiomyoma and Adenomyosis.

Table 1: Distribution of the cases based on the site involved and type of pathology

| Isolated Pathologies (89.9%) | | | Frequency | Percent |
|---|---------------------------|-----------------------------------|-----------|---------|
| Pathology of uterine corpus (72.1%) | | | | |
| Isolated Uterine Endometrial (N-66) | Benign | Endometrial Polyp | 34 | 4.2 |
| | | Endometrial Stromal nodule | 2 | 0.2 |
| | Premalignant/ Hyperplasia | Simple hyperplasia without atypia | 8 | 1.0 |
| | | Complex hyperplasia with atypia | 3 | 0.3 |
| | Malignant | Endometrioid Adenocarcinoma | 18 | 2.2 |
| Malignant Mixed Mullerian Tumour | | 1 | 0.1 | |
| Isolated Uterine Myometrial (N- 13) | Benign | Adenomyosis | 53 | 6.6 |
| | | Leiomyoma | 457 | 56.9 |
| | Malignant | Leiomyosarcoma | 3 | 0.4 |
| Metastasis to uterine corpus(1) | | | 1 | 0.1 |
| Pathology of uterine cervix (17.4%) | | | | |
| Isolated Cervix (N-140) | Benign | Cervical Polyp | 18 | 2.2 |
| | | Leiomyoma | 17 | 2.1 |
| | Pre-malignant | CIN-I | 2 | 0.2 |
| | | CIN-II | 1 | 0.1 |
| | | CIN-III | 6 | 0.7 |
| | Malignant | Squamous Cell Carcinoma | 88 | 10.9 |
| | | Adenocarcinoma | 6 | 0.7 |
| | | Small Round Cell Tumour | 1 | 0.1 |
| | Inflammatory | Tuberculosis | 1 | 0.1 |
| Pathology of ovary (0.3%) | | | | |
| Isolated Ovary (N-3) | Benign | Benign Serous Cystadenoma | 1 | 0.1 |
| | | Cystic Teratoma/Dermoid Cyst | 1 | 0.1 |
| | Malignant | Serous Cystadenocarcinoma | 1 | 0.1 |
| Combined Pathology (N-81) 10.1% | | | | |
| Leiomyoma + Adenomyosis | | | 59 | 7.4 |
| Leiomyoma + Endometrial polyp | | | 5 | 0.7 |
| Leiomyoma+ Serous cystadenoma | | | 3 | 0.3 |
| Leiomyoma +Mucinous cystadenoma | | | 1 | 0.1 |
| Leiomyoma + Dermoid cyst/Cystic teratoma | | | 3 | 0.3 |
| Leiomyoma + Endometriosis of Fallopian Tube | | | 1 | 0.1 |
| Leiomyoma + Endometrial Adenocarcinoma | | | 1 | 0.1 |
| Adenomyosis + Endometrial polyp | | | 3 | 0.4 |
| Adenomyoma +Serous cystadenoma | | | 2 | 0.2 |
| Adenomyosis +Mucinous cystadenoma | | | 1 | 0.1 |
| Leiomyoma + Adenomyosis + Mucinous cystadenoma | | | 1 | 0.1 |
| Benign Brenner tumor + Endometrial Adenocarcinoma | | | 1 | 0.1 |
| Total | | | 804 | 100 |

The age of the patient ranged from 19-80 years. Maximum numbers of patients were in the age group of 36-45 years (50%). Out of 804 patients, 356 (44.4%) were premenopausal (18-40 years), 337 (41.9 %) were in perimenopausal age group (41-50 years), whereas only 111 (13.8%) were postmenopausal (PM). The predominant pattern of bleeding was menorrhagia (79.1%) followed by postmenopausal bleeding (20%). Amenorrhoea & hypomenorrhoea were seen infrequently (5 and 2 cases each).

Out of 804 cases, parity was available only in 460 cases. Out of these 376 cases (81.73%) were multiparous (3-4 kids) or grand multiparous (5-6 kids).

Benign structural pathology was seen in (82.34%) cases of AUB while malignancy contributed to (14.80%) cases (Table 2). Premalignant lesions- endometrial hyperplasia & CIN were very infrequent & comprised 1.3 & 1% respectively. A case of leiomyoma and a case of benign Brenner tumour were associated with endometrial adenocarcinoma. Tuberculous endometritis was detected in one patient. Most frequently found benign pathology was leiomyoma 474(71.6%), while other benign lesion causing AUB was very low (less than 10%). Two cases of endometrial stromal nodule were mistaken with leiomyoma, but it showed positivity for CD10 at IHC.

Of all malignant tumours, squamous cell carcinoma of cervix (72.72%) was most common compared to endometrial adenocarcinoma (16.5%) & adenocarcinoma of cervix (5%). Leiomyosarcoma of uterus was seen in 2.5% cases, all 3 were positive for Desmin on IHC. Also seen was one case each of malignant mixed mullerian tumor of uterus, metastasis to uterine corpus, serous cyst adenocarcinoma, and small round cell tumor of cervix. (Fig. 1)

Table 2: Distribution of the cases with benign pathology

| Type of benign pathology (n=662) | Frequency | Percentage |
|----------------------------------|-----------|------------|
| Leiomyoma | 474 | 71.6 |
| Leiomyoma+ Adenomyosis | 59 | 9.0 |
| Adenomyosis | 53 | 8.0 |
| Endometrial Polyp | 34 | 5.1 |
| Cervical Polyp | 18 | 2.7 |
| Endometrial Stromal Nodule | 2 | 0.3 |
| Benign Serous Cystadenoma | 1 | 0.2 |
| Cystic teratoma/ Dermoid Cyst | 1 | 0.2 |
| Other combination | 20 | 3.0 |
| Total | 662 | 100 |

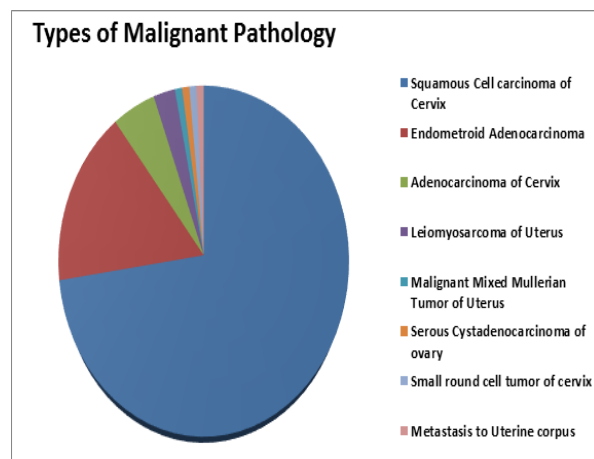


Fig. 1: Distribution of Cases with Malignant Pathology

In patients with leiomyoma, younger patients i.e. 35 years and less had almost equal incidence (68.4%) as that of middle age group i.e. 36-50 years (70%) & elder females i.e. >51 years had much lower incidence (36.9%). Thus the difference in occurrence between less than 50 years of age as compared to >51 years of age, was statistically highly significant. Leiomyomas were most commonly solitary (78.31%) than multiple (21.69%). With a great variation in size (0.2cm- 30 cm). While fibroids in <35 years age was larger (6.3cm), in other age groups it varied from 3.7 to 4.5 cm, and this difference was highly significant statistically. Most common site was intramural (55.9%), followed by submucosal (20.3%) & sub-serosal (12.9%). Majority of leiomyoma (81.59%) had no noticeable secondary change. Most common degenerative change encountered was hyaline degeneration in 14.61% cases. Cystic degeneration, mucoid and myxoid change, calcification, haemorrhage, necrosis and red degeneration were noted in less than 1% cases.

Adenomyosis was commonly seen in middle age groups as compared to extreme age groups. Polymenorrhagia & menorrhagia were seen in (27 & 15% respectively) while postmenopausal bleeding had lower incidence (6.2%). This difference was found to be highly significant.

Endometrial adenocarcinoma most commonly presented with PM bleeding, as compared to menorrhagia & polymenorrhagia, which was statistically highly significant. Fifty years and below age group had <3% while age group >51 years had 9% incidence of endometrial adenocarcinoma. This higher % in higher age group is highly significant. All 20 were type I endometrioid adenocarcinoma, 90% of them being well differentiated.

Squamous cell carcinoma cervix was seen in <7% in age group up to 45 years, 13% in 46-50 years, 30% in >51 years of age. This rising incidence of SCC of cervix in higher age groups was statistically highly significant.

Most common malignant tumor of cervix was SCC (92.63%), with 60.6% being moderately differentiated.

There were total 15 cases of ovarian pathology, majority (12 cases) were associated with other

pathology, mainly being leiomyoma (8/12 cases). Only 3 cases had ovarian pathology as sole underlying cause of AUB.

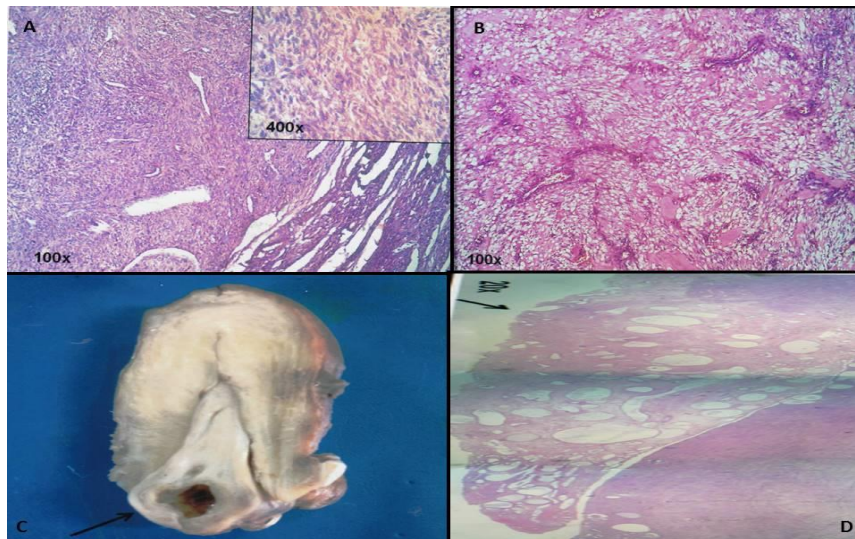


Fig. 2: Benign Pathology of AUB like Leiomyoma with variants. (A) Cellular Leiomyoma, a well circumscribed mass of highly cellular fascicles of benign smooth muscle cells (H&E stain, 100x) with no atypia& atypical mitotic figures (inset) (H&E stain, 400x); (B) Vascular leiomyoma seen as proliferating smooth muscles with interspersed thick and thin walled plexiform vessels (H& E stain, 100x); (C) Polyp was seen as pedunculated lesion arising from endometrial cavity on gross and; (D) microscopically showing cystically dilated crowded endometrial glands lined by inactive endometrium, central fibrous core containing thick walled blood vessels. (H&E stain, 20x)

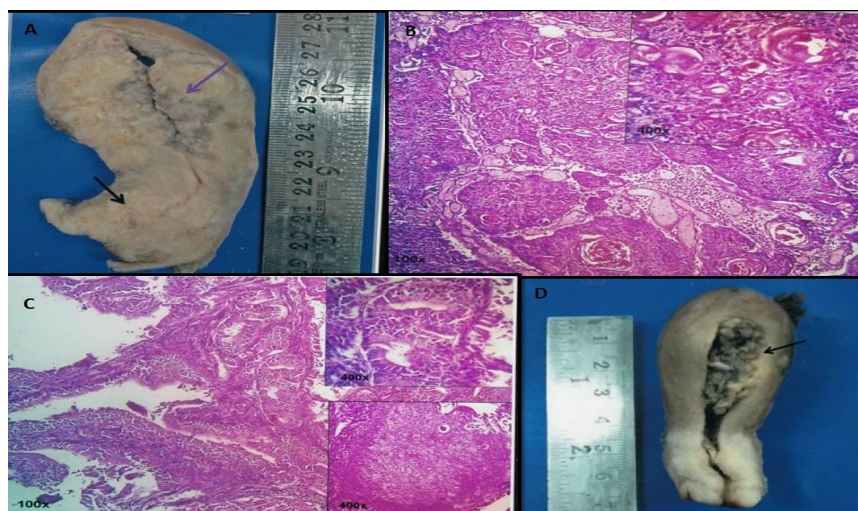


Fig. 3: Squamous cell carcinoma of cervix, with. (A) necrotic growth involving both anterior & posterior lips along with uterine corpus on gross and on histology; (B) showed well differentiated squamous cell carcinoma consisting of islands of mature squamous epithelial cells with abundant eosinophilic cytoplasm and large irregular hyperchromatic nuclei (H&E stain, 100x)along with numerous keratin pearls (inset) (H& E stain, 400x); (C) Endometrial carcinoma was seen as haemorrhagic and necrotic tumor filling endometrial cavity and infiltrating myometrium; (D) villo-glandular pattern, crowded glands lined by large cells with rounding of nuclei and prominent nucleoli (H& E stain, 100x) along with squamous morules(inset)(H& E stain, 400x)

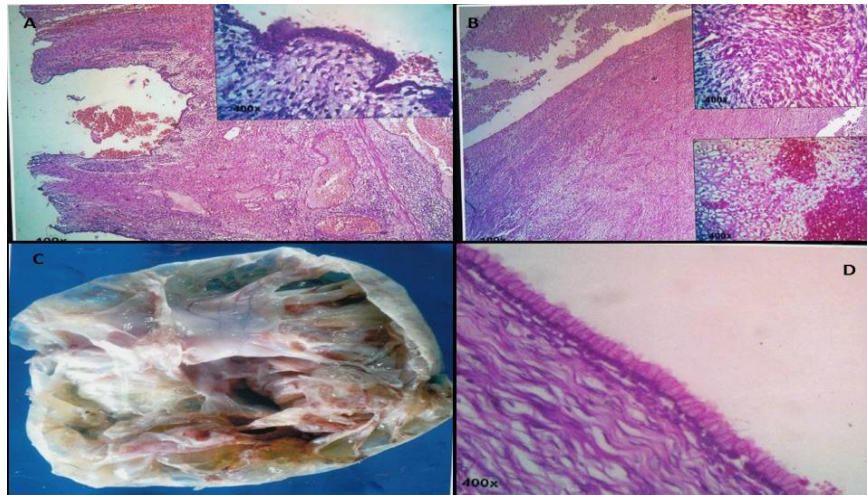


Fig. 4: Malignant mixed Mullerian tumor of uterus with. (A) biphasic pattern both carcinomatous and sarcomatous component (H& E stain, 100x), inset showing malignant glandular lining(H& E stain, 400x)and; (B) sarcomatous component, inset above shows poorly differentiated spindle cells (H&E stain, 100x), while inset below shows heterologous cartilaginous component (H& E stain, 400x); (C) Mucinous cystadenoma of ovary seen as multiloculated thin walled cyst filled with mucinous material without any solid or papillary growth and cyst wall was lined by tall columnar cells and contained mucin material associated with; (D) leiomyoma (H& E stain 400x)

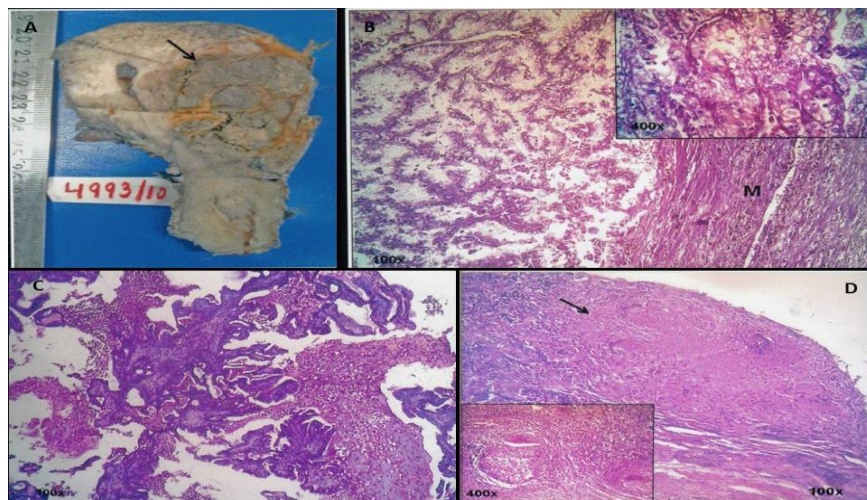


Fig. 5: Rare causes associated with AUB were. (A) Metastasis of Renal cell carcinoma to uterine corpus grossly seen as distorted endometrial cavity with multiple intramural grey white necrotic masses with focal golden yellow colour &; (B) myometrium showed organoid pattern of clear cells (inset, H& E stain, 400x); (C) Cervical Papillary Adenocarcinoma showing papillary growth with fibrous core lined by epithelium with hyperchromatic crowded nuclei(H& E stain, 100x); (C) & (D) Tuberculosis of cervix was seen as multiple caseating granulomas in cervical stroma(H& E stain, 100x), consisting of central caseous necrosis, epithelioid cells and Langhans' giant cells (inset, H& E stain, 400x)

Discussion

Abnormal uterine bleeding (AUB) may be due to organic & non-organic causes. The chief aim of present study was to know the various organic causes of AUB and their clinic- pathological and epidemiological profile. Present study revealed that AUB was the presenting complaint in 86.4% of all gynaecology referrals, thus being major cause of morbidity in females.

Organic causes as underlying cause of AUB was seen in 19.2% of cases. Studies by O Connor et al,⁽¹¹⁾

Wahda Et al⁽¹²⁾ and Talat Mirza et al⁽¹³⁾ reported organic cause of AUB as low as 19% to as high as 60% cases. This implies 1/4th to 3/4th women population suffers due to causes which can be easily detected & alleviated.

Morphological evaluation revealed that majority of cases had pathology in myometrium (63.8%) followed by cervix (17.4%) & in endometrium (8%) cases. In study by Doriaswamy,⁽¹⁴⁾ isolated endometrial pathology was seen in 66% & cervical in 4.2% cases. This variation in incidence may be because they included all causes of

endometrial pathology, which were excluded in this study.

The International Federation of Gynecology and Obstetrics (FIGO) in 2011 approved a new classification system (PALM-COEIN) for causes of abnormal uterine bleeding (AUB) in women of reproductive age based on bleeding pattern as well as etiology. There were 9 main categories arranged according to the acronym PALM - COEIN: Polyp, Adenomyosis, Leiomyoma, Malignancy and hyperplasia, Coagulopathy, Ovulatory dysfunction, Endometrial, Iatrogenic, and Not yet classified.⁽¹⁰⁾ Literature search revealed that majority of the studies on the subject of AUB evaluated only one aspect of female genital tract either endometrium or cervical carcinoma or leiomyoma etc.

This study evaluated all the components of the PALM group that includes discrete (structural) entities that can be measured visually with imaging techniques and/or histopathology.

Polyps were seen in less than 10% of cases (52, 6.4%). Endometrial polyps were more (34, 4.2%) compared to cervical polyps (18, 2.4%).

Adenomyosis age incidence of 36-45 years is comparable with Shreshta et al⁽¹⁵⁾ & Mobarakeh et al.⁽¹⁶⁾ Isolated cases account for 6.6% cases with AUB, but Sanaullah⁽¹⁷⁾ & Mobarakeh⁽¹⁶⁾ had adenomyosis accounting 17% & 21% of AUB cases.

Next category is Leiomyoma which accounted for 57% of cases in present study, Sanaullah (2004)⁽¹⁷⁾ and Dehghani Mobarakeh (2012)⁽¹⁶⁾ et al showed leiomyoma account for 67% & 30% of AUB cases respectively. In studies by Anne Zimmermann (2012)⁽¹⁸⁾ & -A Mohammad (2005),⁽¹⁹⁾ most common age group of leiomyoma was 32-42 years & 25-39 years of age. In this study, it is older age group (46-50 years) affected as compared to other studies.

In our study, for carcinoma cervix most common age group was > 51 years, which was comparable with studies done by Pagnini⁽²⁰⁾ (mean age 52.8 year) and Kogan et al⁽²¹⁾ (mean age 50.3 years). Among the carcinoma of cervix, 92.63% were SCC and 6.32% were adenocarcinoma. According to studies by Vizcaino et al⁽²²⁾ & Hannoun Levi et al,⁽²³⁾ SCC accounts for 85-90% & 91% cases respectively. In present study, Broder's grade II was most common in 60% & grade I in 8.45% cases of SCC. While NG⁽²⁴⁾ showed grade I in 40% and grade II in 37% of cases.

In Endometrial carcinoma, most common age group affected was 51 years & above. Doriaswamy⁽¹⁴⁾ et al & Escoffery⁽²⁵⁾ et al had similar age group affected as 51-60 years. In this study, all endometrial carcinoma were endometrioid adenocarcinoma (type I), 95% of them were grade I. while in study by Charkviani⁽²⁶⁾ et al grade II endometrioid carcinoma were most common (57.8% cases). Various other studies by Saraswati⁽¹⁴⁾ et al, Sanullah⁽¹⁷⁾ et al, Dangal⁽²⁷⁾ et al, Sadia khan⁽²⁸⁾ et al, Lyla Abdullah⁽¹⁹⁾ et al, Baral⁽²⁹⁾ et al, Wahda⁽¹²⁾ et al reported lower incidence of malignancy which ranged

from as low as 0.4% to as high as 21%. This variability in the incidence may be due to varying inclusion criteria, parity & ethnicity of study group.

As women gets older the incidence of malignancy increases, most probably consistent with unopposed estrogenic effects in later years. In the category of malignancy carcinoma cervix was most frequently presented as AUB as compared to endometrial carcinomas. But these studies also included cases of chronic endometritis, atrophic endometrium & pregnancy related causes of AUB.

Three cases (0.3%) of isolated ovarian tumors viz. benign serous cystadenoma, mature cystic teratoma, serous cyst-adenocarcinoma, had AUB as presenting complaint. These tumors usually present as pelvic mass. Thus, this study reports AUB as unusual presentation of these tumors. There were coincidental finding of co-existence of leiomyoma & Adenomyosis with surface epithelial tumor of ovary and mature cystic teratoma. There was a single case of benign brenner tumor co-existing with endometrial carcinoma which can be explained on the basis of hyperoestrogenism.

Muzaffar et al,⁽³⁰⁾ Mahnaz et al & Archana Bhosale⁽³¹⁾ et al also observed menorrhagia as the most common pattern of bleeding similar as our study (64.4%). Latter had studied AUB in perimenopausal women. Postmenopausal bleeding (PMB) (20% of cases) was frequently associated with benign pathology (53.7%), out of which leiomyoma was commonest (35.8%). Malignant neoplasms are generally accepted to be relatively uncommon causes of PMB with carcinoma of cervix being involved in 35.9% patient. This association of PM bleeding with malignancies was found to be statistically significant and although based on different inclusion criteria, the incidence of PM bleeding in malignancy is comparable in various studies.^(12,19,27,32)

Majority of studies are from developing countries, most of them included normal menstrual pattern in their study, which have been excluded in present study. Ours is one of the largest study who had dealt with entire structural pathology of AUB. The variability in incidences of various causes of AUB is due to different inclusion criteria, racial & geographical factors.

Conclusion

This study thus concludes that organic causes form a significant component of AUB, a major health issue of females worldwide. Histopathology plays a pivotal role in accurately identifying the true nature of the lesion. It aids in deciding the appropriate type and extent of surgery as per age and fertility status of the patient.

References

1. Abid Mariam, Hashmi Atif Ali, Malik Babar, Haroon Saroona Et Al. Clinical Pattern And Spectrum Of Endometrial Pathologies In Patients With Abnormal Uterine Bleeding In Pakistan: Need To Adopt A More Conservative Approach To Treatment. BMC Women's Health. 2014;14:132.

2. Brenner P F. Differential Diagnosis of AUB. *Am J Obstet Gynecol.* 1996;175:766-69.
3. Nicholson WK, Ellison SA, Grayson H, Powe NR. Patterns of Ambulatory Care Use of Gynecologic Conditions: A National Study. *Am J Obstet Gynecol.* 2001;184:523-30.
4. Best KA. Abnormal Uterine Bleeding: Etiology, Evaluation, And End Points For The Non- Gynaecologist. *Northeast Florida Medicine.* 2006;57(2):27-30.
5. Bhatta S, Sinha AK. Histopathological Study of Endometrium in Abnormal Uterine Bleeding. *JournOf Pathology Of Nepal.*2012;2:297-300.
6. Harlow SD, Campbell OMR: Epidemiology of Menstrual Disorders in Developing Countries: A Systematic Review. *BJOG* 2004;111:6-16.
7. Alber JR, Hull SK, Wesley RM. Abnormal Uterine Bleeding. Southern Illinois University School OfMedicine, Springfield, Illinois. *Am Fam Physician.* 2004;69:1915-26.
8. Tavassoli FA, Devilee P (Eds). World Health Organization Classification of Tumors. Pathology and genetics of tumors of the breast and female genital organs. IARC Press: Lyon 2003
9. Kurman RJ, Ellenson LH, Ronnett BM (Eds). Blaustein's Pathology of the Female Genital Tract. 6th Edition. New York (NY); Springer;2011.
10. Munro MG, Critchley, Michael S, Broder MS, Fraser IS. FIGO Classification System (PALM-COIN) For Causes of Abnormal Uterine Bleeding In Non-Gravid Women of Reproductive Age. *International Journal of Gynecology and Obstetrics.* 2011;6(2):89-100.
11. O'Connor VM. Heavy Menstrual Loss Part 1. Is It Really Heavy Loss? *Med Today* 2003;4(4):51-9.
12. Al – Neaimy WMT, Ahmed MT, Al-Jawadi SI. Histopathological Interpretation of Abnormal Uterine Bleeding After Age of 40 Year. *The Iraqui Postgrad Medical Journal.* 2010;9(3):274-82.
13. Mirza T, Akram S, Mirza A, Aziz S, Mirza T, Mustanasar T. Histopathological Pattern Of Abnormal Uterine Bleeding In Endometrial Biopsies. *Journal of Basic and Applied Sciences.* 2012;8(1):114-17.
14. Doriaswami S, Johnson T, Rao S, Rajkumar A, Vijayaraghavan J, Panicker VK. Study of Endometrial Pathology in Abnormal Uterine Bleeding. *J Obst Gynecol India.* 2011;61(4):426-30.
15. Shreshta A, Shreshta R, Sedhai LB, Pandit U. Adenomyosis at Hysterectomy: Prevalence, Patient Characteristics, Clinical Profile and Histopathological Findings. *Kathmandu Univ Med J.*2012;10(37):53-6.
16. Mobarakeh MD, Maghsudi A, Rashidi I. Adenomyosis Among The Samples From Hysterectomy Due To Abnormal Uterine Bleeding In Ahwaz, Southern Iran. *Adv Biomed.*2012;1:49.
17. Gazozai S, Bugti QA, Siddiqi A, Ehsan N. Excessive Uterine Hemorrhages- A Histopathological Study. *Gomal Journal OfMedical Sciences.* 2004;2(1):13-15.
18. Zimmerman A, Bernuit D, Gerlinger C, Schhaefers M, Geppert K. Prevalence, Symptoms And Management Of Uterine Fibroid: An International Internet Based Survey Of 21,746 Women. *BMC Womens Health.*2012;12:6.
19. Mohammed A, Shehu AM, Ahmed SA, Mayuri AA, Tiffin U, Alkali G, Et Al. Uterine Leiomyoma: A Five Year Clinicopathological Review In Zaria- Nigeria, Nigerian Journal of Surgical Research 2005;7(1):206-208.
20. Pagni CA, Dalla P, De Laurentis G. Malignancy Grading In Squamous Cell Carcinoma Of Uterine Cervix Treated By Surgery. *Br J Cancer.* 1980;41:415-21.
21. Kogan L, Menczer J, Shejter E, Liphshitz I, Barchana M. Selected Clinical Characteristics Of Israeli Jewish Women With Squamous Cell Carcinoma Pf The Uterine Cervix: A Population Based Study. *Isr Med Asso J.*2011;13(2):84-86.
22. Vizcaino Ap, Moreno V, Bosch FX, Munoz N, Barros-Dios XM, Parkin DM. International Trends In Incidence Of Cervical Cancer: Squamous Cell Carcinoma. *IntJ Cancer* 2000;86(3):429-35.
23. Hannoun– Levi JM, Peiffert D, Hoffstetter S, Luposi E, Bey P, Pernot M. Carcinoma Of The Cervical Stump: Retrospective Analysis Of 77 Cases. *Radiother Oncol.*1997;43(2):147-153.
24. NG ABP, Atkin NB. Histological Cell Type AndDNA Value In The Prognosis Of Squamous Cell Cancer Of Uterine Cervix. *Br J Cancer.*1973;28:322-331.
25. Escoffery CT, Blake GO, Sargent LA. Histopathological Findings InwomenWith Postmenopausal Bleeding In Jamaica. *West Indian Med J.*2002;51:232-235.
26. Charkviani T, Charkviani L, ChitiashviliR, Glonti L. Epidemiology and clinical management of endometrial carcinoma in the republic of georgia in the last 30 years. *Eur J Gynaecol Oncol.*1996;17(4):292-95.
27. Dangal G. A Study of Endometrium of Patients with abnormal uterine bleeding at Chitwan Valley. *Kathmandu University Medical Journal* 2003;1(2):110-12.
28. Khan S, Hameed S, Umber A. Histopathological Pattern Of Endometrium On Diagnostic D&C In Patients With Abnormal Uterine Bleeding. *Madina Teaching Hospital Annals* 2011;17(2):166-170.
29. Baral R, Pudasaini S. Histopathological Pattern of Endometrial Samples in Abnormal Uterine Bleeding. *Journal Of Pathology Of Nepal.*2011;1:13-16.
30. Muzaffar M, Akhar KA, Yasmin S, Mahmood Ur-Rehman, Iqbal W, Khan MA. Menstrual Irregularities With Extensive Blood Loss: A Clinicopathological Correlation. *J Pak Med Asso*2005;55(11):486-89.
31. Bhosale A, Fonseca M. Evaluation And Histopathological Correlation Of Abnormal Uterine Bleeding In Peri-Menopausal Women. *Bombay Hospital Journal.*2010;52(1):69-72.
32. Khare A, Bansal R, Sharma S, Elhence P, Makkar N, Tyagi Y. Morphological Spectrum Of Endometrium In Patients Presenting With Dysfunctional Uterine Bleeding. *People's Journal of Scientific Research.* 2012;5(2):13-16.