

Utility of CK 20 and micro vessel density in diagnosis and prognosis of urothelial neoplasms

Shruthi Hosur Puttappa^{1,*}, Rangaswamy R²

¹Assistant Professor, ²Professor, Dept. of Pathology, Karnataka Medical Council, Bangalore

***Corresponding Author:**

Email: 1111.shruthi@gmail.com

Abstract

Background: Urothelial carcinoma is the 7th most common cancer worldwide. More than 50% of patients with non-invasive tumors have recurrences and 10-15% of these will progress to invasive cancer. Hence there is a need to assess the biological behavior of tumors with newer modalities.

CK 20 is generally expressed only in the umbrella cells of the non-neoplastic urothelium, whereas their abnormal expression predicts malignant potential in low grade TCC. Micro vessel Density (MVD) as elsewhere is a predictive prognostic marker in TCC also. Hence CK 20 and MVD together can aid the clinician in defining specific targeted therapies.

Objectives: To assess the clinical utility of CK 20 and MVD in urothelial neoplasms as diagnostic and prognostic factors.

Methods: Study was conducted on 30 TURBT specimens diagnosed as malignant urothelial neoplasms according to WHO/ISUP 2004 classification. Immunohistochemical staining for CK 20 and CD 34 were done and interpreted.

RESULTS: Out of 30 Urothelial neoplasms 2 were Papillary Urothelial Neoplasms of Low Malignant Potential (PUNLMP), 10 were Low Grade Papillary Urothelial Neoplasm(LGPUN), 13 were High Grade Papillary Urothelial Neoplasm (HGPUN), and 5 were Invasive urothelial Neoplasm(IUN).

Abnormal expression of CK 20 was seen in 100% (2/2) of PUNLMP, 80% (8/10) of LGPUN, 46% (6/13) of HGPUN and 40% (2/5) IUN (P = 0.048).

Average MVD was 6.75 in PUNLMP, 19.36 in LGPUN, 28.18 in HGPUN and 44 in IUN (P=0.019).

Conclusion: CK 20 and MVD are useful in predicting benign versus malignant behavior and defining treatment strategies.

Keywords: Urothelial neoplasms, CK 20, Micro vessel Density.

Introduction

Bladder cancer is a significant public health problem worldwide. It is the fourth most common cancer in men and the eight in women in the world,^(1,2) accounting for 7% of all cancers. The typical cost per bladder cancer patient from diagnosis to death was estimated to be the highest among all cancers. Such high costs are due, in part, to the high possibility for recurrence and progression that is characteristic of urinary bladder cancer.⁽³⁻¹⁵⁾ At the time of initial presentation, approximately 70% of transitional cell carcinomas (TCC) are diagnosed as superficial. Of these, approximately half will not have breached the epithelial basement membrane and hence are defined as non-invasive carcinomas (TNM category T_a). In practice, all tumors, whether invasive or not, are labeled carcinomas. The reason for this is that approximately 50% of the non-invasive tumors will recur within 3 years and 3% will evolve to muscle invasive disease.⁽¹⁶⁾

Grading of urothelial tumors is an important prognostic factor. The first grading system for bladder tumors was proposed by Borders in 1922. In 1998 World Health Organisation, International Society of Urological Pathology and Canadian Academy of pathology gave the classification of urothelial tumors called WHO/ISUP Consensus Classification and classified urothelial papillary tumors into Papilloma, papillary urothelial neoplasm of low malignant potential, Low grade carcinoma and high grade

carcinoma.⁽¹⁷⁾ Immunohistochemistry plays an important role in the diagnosis and the differential diagnosis of urothelial carcinoma in special situations like its grading and staging for defining treatment modules.⁽¹⁸⁾

In the normal stratified transitional epithelium (urothelium) of the bladder, there are well defined morphological, topographical and antigenic changes associated with the maturation of urothelial cells during migration from the basal to the terminally differentiated superficial cell layer. Superficial cells are characterized by a highly specialized asymmetric unit membrane on the luminal surface. Loss of this membrane is one of the earliest morphological indicators of urothelial neoplastic transformation and implies dysregulation of the normal differentiation pathway.^(16,19-21)

Prognostic factors in patients with superficial papillary urothelial cancer of the bladder have been the topic of research in the recent years. Clinical and morphological parameters have shown inefficient and have possibly increased the sensitivity and specificity leading to different clinical management. Immunohistochemical markers have been used along with histologic grade, progression, clinical staging and recurrence of tumors to give a precise diagnosis in such cases.⁽²²⁾

Cytokeratins are proteins of keratin-intermediate filaments found in the intracytoplasmic cytoskeleton of epithelial tissue. The term "Cytokeratin" was used in the late 1970s. There are two types of Cytokeratins: the

acidic type I Cytokeratins and the basic or neutral type II Cytokeratins. Expression of these Cytokeratins is usually organ or tissue specific. As an example, CK7 is typically expressed in the ductal epithelium of the genitourinary (GU) tract and CK20 most commonly in the gastrointestinal (GI) tract.⁽²³⁻²⁵⁾

Keartin 20 is the most recently identified type I keratin protein, which shows a limited pattern of expression in normal tissues. The expression of CK 20 in urothelium was restricted to superficial umbrella cells even in the cases of severe inflammation. Only malignancy induced alteration in CK 20 expression pattern. The pattern of CK 20 immunohistochemical staining has additional value along with morphological features in the diagnosis of urothelial dysplasia, since only malignant cells will show CK 20 immunostaining.⁽²⁶⁾ It has also been considered that CK 20 expression can predict malignant potential in low grade transitional cell tumors and therefore CK 20 can be useful in defining treatment strategies in cases with these tumors.⁽²⁷⁾

Angiogenesis is the development of new vessels from pre-existing vessel and is involved in the growth, maintenance and metastases of most solid tumors. It is required to meet the metabolic requirements for tumor progression and in the development of metastases in a variety of malignancies.⁽²⁸⁾ As early in 1972, Brem et al. proposed a microscopic angiogenesis grading system to assess the angiogenic status of the tumor vasculature. Based on the analysis of the vascular density, the number of endothelial cell (EC) nuclei and endothelial cytology, an angiogenic score was determined and used to establish an angiogenic rank order of different human brain tumors.

In 1991, Weidner et al. developed a new method to assess microvascular density (MVD) within tumors. The first step in Weidner's approach is the identification by light microscopy of the area of highest new vessel density, the so called hot spot, by scanning the whole tumoral section at low power, then, individual microvessels are counted at a higher power. By using this approach, Weidner et al. (1991) showed that intratumoral MVD in breast tumors with poor prognosis and metastasis is twice as high in patients with breast tumors with good prognosis and without metastasis, and confirmed this correlation also in prostate carcinoma (Weidner et al., 1993).⁽²⁹⁾

Our study aimed to assess the clinical utility of CK 20 and MVD in urothelial neoplasms as diagnostic and prognostic factors.

Materials and Methods

This retrospective study was conducted in the department of pathology, Kempegowda institute of Medical sciences, Bangalore over a period of 5 years(2010 to 2015).30 cases of malignant urothelial neoplasms were considered for the study and were classified according to the WHO/ISUP 2004

classification. All were formalin fixed, paraffin – embedded tissue blocks were retrieved and sections of 4 micron thick were taken for Hemotoxylin and eosin stain, CK 20 and CD 34 immunostaining. All tumors were stained for CK 20 using Streptavidin-biotin method and the DAKO monoclonal antibody was applied to the tissue sections. The immunostained slides were assessed by the same pathologist, and the cases were classified according to the pattern of CK 20 expression. If the expression was restricted to superficial (umbrella) cells, it was considered as normal expression. Other patterns of CK 20 i.e., diffuse full-thickness positivity or negativity for CK 20 expression, were considered abnormal.

All cases were stained with DAKO antihuman monoclonal antibody CD 34 to recognize the endothelial cells of the blood vessels. Tumor angiogenesis were estimated by calculating standard microvessel density. MVD were assessed by CD 34 stained slides, each slide was first scanned on low magnification (X10) to identify the four areas with highest density of microvessels(hot spots); each spots then was evaluated at high power magnification (X40) and the number of stained vessels per high power field were determined. The final MVD score was obtained from these four fields average.⁽²⁸⁾

Results were analyzed using SPSS software and P value calculated.

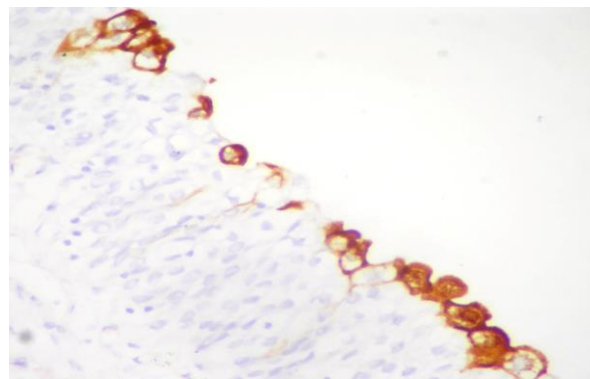


Fig. 1: Normal urothelium showing CK 20 positive umbrella cells

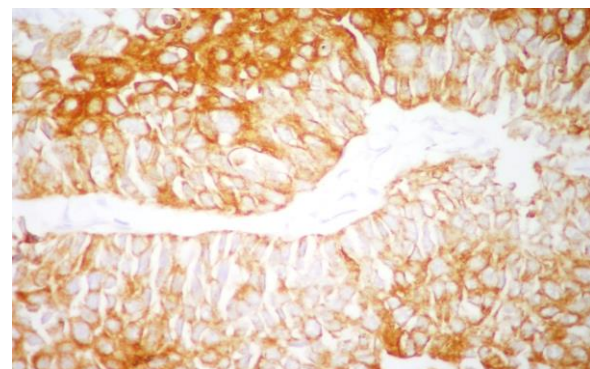


Fig. 2: CK 20 positive case with diffuse staining of the urothelium

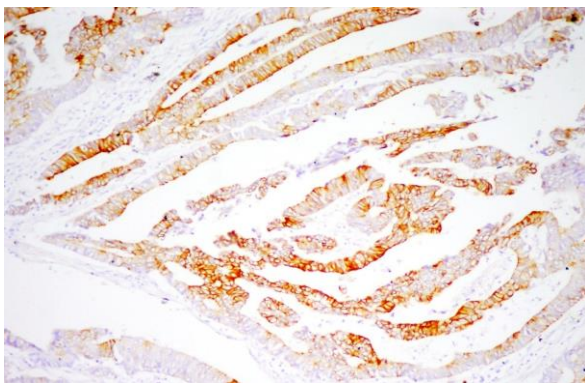


Fig. 3: Positive control for CK 20, normal colonic mucosa

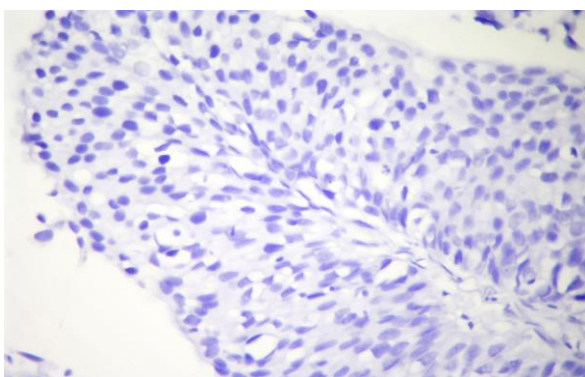


Fig. 4: CK 20 Negative urothelium

Results

Out of 30 Urothelial neoplasms 2 were Papillary Urothelial Neoplasms of Low Malignant Potential (PUNLMP), 10 were Low Grade Papillary Urothelial Neoplasm(LGPUN), 13 were High Grade Papillary Urothelial Neoplasm (HGPUN), and 5 were Invasive urothelial Neoplasm(IUN). Most of the cases presented with Hematuria(86%) and carried the risk factor of smoking (67%). Male to Female ratio was 3.28: 1. 83% of the cases were newly diagnosed, and 63% were single site cases.

Table 1: Results for CK 20 and MVD according to WHO/ISUP classification

Tumor Grade	No of Cases	CK 20 Positive	CK 20 Negative	Positive %	MVD Average PER HPF
PUNLMP	2	2	0	100	6.75
LGPUN	10	8	2	80	19.06
HGPUN	13	5	8	46	28.15
Invasive	5	2	3	40	42.4
Total	30	17	13		

In our study out of 30 cases 17(56.66%) were positive for CK 20 and 13(43.33%) were negative for CK 20. Average MVD per HPF in PUNLMP was 6.75, in LGPUN was 19.06, in HGPUN was 28.15 and in Invasive tumors was 42.4.

Table 2: CK 20 staining results

Tumor Grade	CK 20 Negative cases	CK 20 Positive cases		
		Weak(<2/3 rd of epithelium)	Moderate(>2/3 rd of the epithelium)	Strong(Diffuse positivity)
PUNLMP	0	1	0	1
LGPUN	2	2	3	3
HGPUN	8	1	3	1
Invasive	3	0	2	0
Total	13	4	8	5

CK 20 staining showed varying intensity in different grades of tumors. 4 of the tumors were weakly staining, 8 showed moderate staining intensity and 5 of the tumors showed strong positivity for CK 20.

Table 3: Correlation of MVD with CK 20 staining intensity of urothelial tumors

Staining intensity of CK	CK 20 positive tumors	Average MVD per HPF
Weak	4	11.25
Moderate	8	25.10
Strong	5	25.67

Tumors with weak CK 20 positivity showed 11.25 as average MVD where as in Moderate and strong CK 20 positive cases showed similar Average MVD of 25.10 and 25.67 respectively.

Unpaired T test was showed P was 0.019 for MVD and 0.048 for CK 20 and thus found to be significant in both the cases. On follow up for one year the following was the data obtained. 3 out of 10 LGPUN cases with high MVD and CK 20 positivity came back with recurrence and 2 HGPUN cases with high MVD and

one positive and one negative for CK 20 came back with recurrence. So the recurrence rate was 30% in LGPUN and 15.38% in HGPUN.

Table 4: Follow up with recurrence rate in Urothelial tumors

Initial Grade	CK 20	MVD	Recurrence
LGPUN	+	42.25	HGPUN
LGPUN	+	15.25	LGPUN
LGPUN	+	24.75	LGPUN
HGPUN	+	37.25	TCC
HGPUN	-	27.25	TCC

On follow up for one year only data was available for 12 cases. Rest of the cases no information was available. Out of the 12 cases 7 cases were negative for CK 20 and had no recurrence. 4 cases were CK 20 positive and had 36.68 average MVD came back with recurrence. One case was CK 20 negative and 27.25 as average MVD reported with recurrence. There were 18 drop outs in the study.

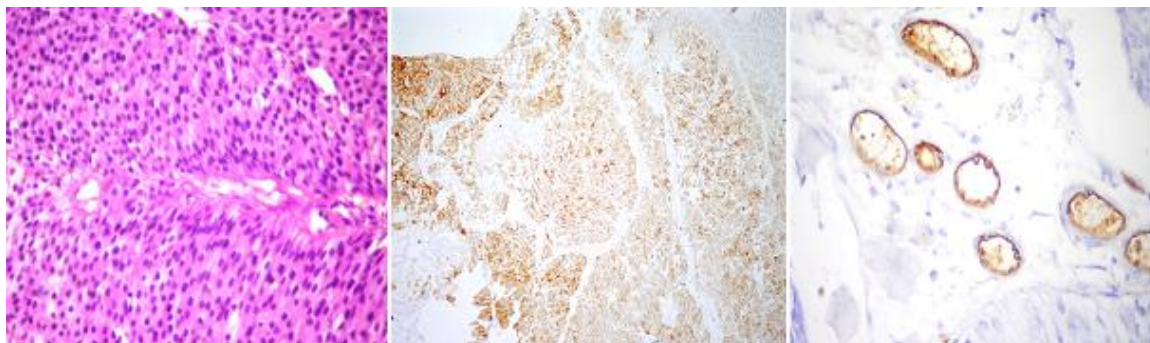


Fig. 5: PUNLMP H & E staining, CK 20 & MVD (CD 34)

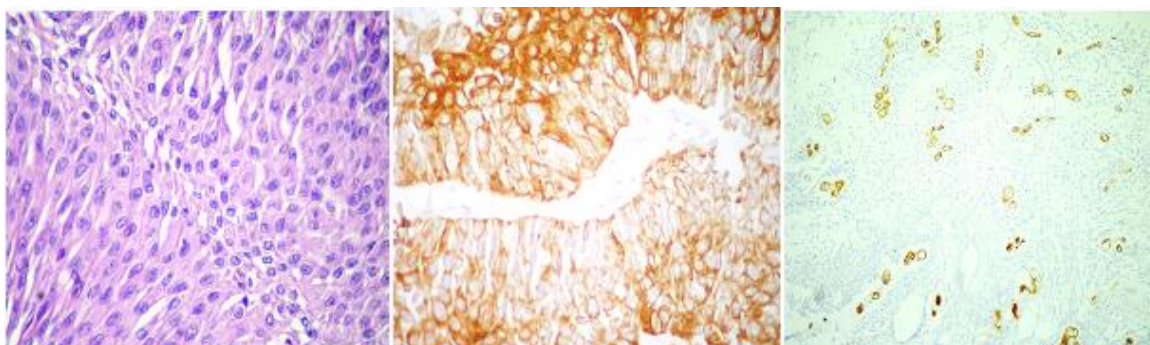


Fig. 6: LGPUN H & E staining, CK 20 & MVD (CD 34)

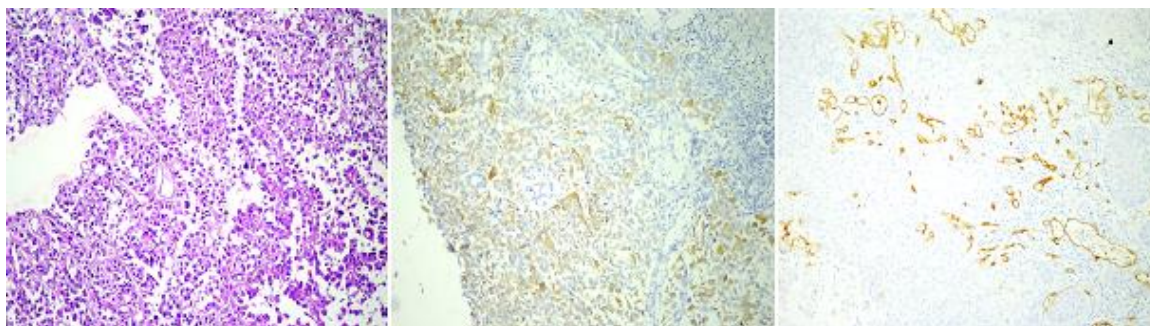


Fig. 7: HGPUN H & E staining, CK 20 and MVD (CD 34)

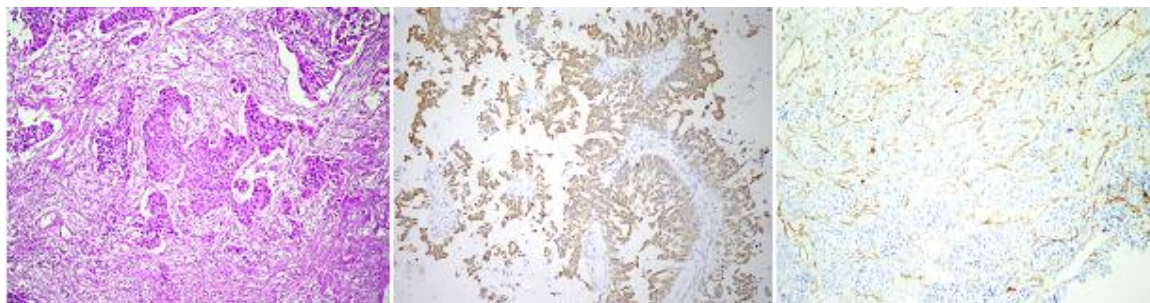


Fig. 8: IUN H & E staining, CK 20 & MVD (CD 34)

Discussion

Low grade papillary urothelial neoplasms of the urinary bladder are known for their high rate of recurrence and low potential for invasion. Patients with low grade urothelial neoplasms treated by transurethral resection typically then monitored by regular cystoscopy, which is expensive and has high risk of mortality and morbidity, related primarily to the risk of anesthesia. A less invasive and expensive alternative to cystoscopy is desirable and variety of alternatives have been investigated. Urine cytology has been used for follow up in patients with bladder carcinoma. Cytology is effective in monitoring recurrence of high grade urothelial neoplasms, but is ineffective in low grade papillary urothelial tumors because the tumors cells lack many of the cytologic features of malignancy.^(27,30-34)

We compared our study with others to evaluate the significance of CK 20 expression in Urothelial neoplasms. Total number of cases positive for CK 20 were 56.66% and Tumors negative for CK 20 were 43.33%. Among the positive tumors 76.47% of the tumors showed moderate to strong intensity and only 23.52% were weakly stained with CK 20. Among the low grade tumors our study had 80% of them showing CK 20 positivity which was comparable to other studies like P Harnden et al⁽¹⁶⁾ in 1995 showed 81.81% CK 20 low grade tumors, A Alsheikh et al⁽²⁷⁾ showed 65.2% CK 20 positivity. Recent studies like S Abdel et al⁽³⁵⁾ showed 94.73% low grade tumors showing CK 20 positivity and S Mumtaz et al⁽¹⁷⁾ with 82.6% positivity.

We also correlated the intensity of CK 20 staining with average MVD in different grades of tumors. In our

study the Average MVD in tumors with weak expression of CK 20 was 11.25. Tumors with moderate and strong intensity of staining for CK 20 showed 25.10 and 25.67 respectively. In the recurrent group of CK 20 positive tumors the MVD was significantly high.

It is evident from the results of our study and other studies that Ck 20 expression may therefore be useful in the identification of low grade and early tumors of urothelial origin, before the morphological feature progress to high grade. It has been proposed that the most recently identified CK polypeptide, CK 20, may be a useful diagnostic marker for distinguishing certain types of carcinoma, particularly when presented as metastases, due to its very restricted distribution in normal tissues. The predictive capability of CK 20 may be further refined by examination of the pattern of expression in adjacent flat mucosa. This may enable a prognosis to be made in cases in which CK 20 expression is diffuse throughout the papillae and hence non-informative.⁽¹⁶⁾

MVD would be a good indicator of therapeutic efficacy, but it has not been as useful for efficacy as it has for prognosis. Jonathan C et al⁽³⁶⁾ in 2003 studied that 23% of superficial tumors with high MVD progressed to muscle invasive disease. In 2004 Canoglu et al⁽³⁷⁾ proved in their study that significantly higher MVD was noted in invasive tumors than superficial tumors. High MVD was correlating with the risk of clinical progression in both superficial and invasive bladder carcinomas. In our study there was a direct correlation between tumor grade and recurrence rate with High grade tumors having 28.15 average MVD as compared to 19.06 average MVD in low grade tumors.

Quantification of angiogenesis by measurement of MVD has shown that in many tumor types, a high level of angiogenic activity is associated with aggressive tumor behavior. In urological malignancies, CK 20 along with MVD can be extensively investigated as a prognostic tool. Although this study examines a small sample of Superficial bladder cancer cases, a prospective trial of this method would better determine its clinical use. Furthermore, despite the highly significant difference shown, there is considerable overlap in MVD between the two groups. It is likely that neoangiogenesis may become an intergral part of a more consistent tumor staging system and routine prognostic evaluation.

	P. Harnden et al⁽¹⁶⁾ 1995	A Alsheikh et al⁽²⁷⁾ 2001	S Abdel et al⁽³⁵⁾ 2014	S Mumtaz et al⁽¹⁷⁾ 2014	Our study 2014
CK 20 abnormal expression in low grade tumors	81.81%	65.2%	94.73%	82.6%	80%
Recurrence	42%	50%	-	-	30%

Conclusion

Flat urothelial lesion with atypia accounts to a spectrum of morphological changes ranging from reactive atypia to urothelial dysplasia or CIS. The most important predictive parameter for the biological behavior of the bladder cancer, apart from depth of invasion, is the histological grade of the tumor. Categorizing these lesions is important because of different clinical outcome and therapy. Currently, differential diagnosis relies on histopathological evaluation of samples and the experience of the pathologist. Combined use of immunohistochemical markers like CK 20 and MVD may allow discrimination between low grade and high grade neoplastic lesions. CK 20 not only helps in identifying the low grade tumors but also in predicting the risk of recurrence. MVD as elsewhere predicts the malignant behaviour of the tumors. The drawback of the study has been the small sample size, a study with more samples would prove the significance of CK 20 and MVD together are good and better prognostic markers.

Hence CK 20 and MVD together can help the clinician to identify the patients at risk and define specific targeted therapy and thus decrease the mortality and morbidity **Diagnosis is not the end, but the beginning of practice.....**

References

- Noora Ali Jawad, Dr Hussam Hasson Ali, Mohammed Subhi Kamal. Her2/Neu and Ki -67 Immunohistochemical Expression in transitional cell carcinoma of the urinary Bladder. IOSR journal of dental and medical sciences 2016;15(2):6-12.
- Lopez-Beltran A, Montironi R, Vidal A, Scarpelli M and Cheng L. Urothelial dysplasia of the bladder: diagnostic features and clinical significance. Analytical and quantitative cytology and histology 2013;35:121-129.
- Siegel R, Naishadham D, Jemal A: Cancer statistics, 2012. CA Cancer Journal for Clinicians 2012;62:10-29.
- Lopez-Beltran A, Cheng L, Andersson L, Brausi M, de Matteis A, Montironi R, Sesterhenn I, van der Kwast KT, Maze-rolles C: Preneoplastic non-papillary lesions and conditions of the urinary bladder: An update based on the Ancona International Consultation. Virchows Archives 2002;440:3-11.
- Epstein JL, Amin MB, Reuter VR, Mostofi FK: The World Health Organization/International Society of Urologic Pathology consensus classification of urothelial (transitional cell) neoplasms of the urinary bladder. Bladder consensus conference committee. American Journal of Surgical Pathology 1998;22:1435-1438.
- Cheng L, Cheville JC, Neumann RM, Bostwick DG: Flat in-traepithelial lesions of the urinary bladder. Cancer 2000;88:625-631.
- Mazzucchelli R, Cheng L, Lopez-Beltran A, Scarpelli M, Montironi R: Classification and grading of noninvasive and invasive neoplasms of the urothelium. Analytical and Quantitative Cytology and Histology 2012;34:111-119.
- Lopez-Beltran A: Rare lesions and tumors of the urinary bladder: Selected issues. Tumori 2012;98:274-277.
- Montironi R, Cheng L, Scarpelli M, Mazzucchelli R, Lopez-Beltran A: How much do you know about benign, pre-neoplastic, non-invasive and invasive neoplastic lesions of the urinary bladder classified according to the 2004 WHO.
- Scheme. Diagnostic Pathology 2011;6:31.
- Lopez-Beltran A: Bladder treatment: Immunotherapy and chemotherapy. Urologic Clinics of North America 1999;26:535-554.
- Lopez-Beltran A, Algaba F, Berney DM, Boccon-Gibod L, Camparo P, Griffiths D, Mikuz G, Montironi R, Varma M, Egevad L: Handling and reporting of transurethral resection specimens of the bladder in Europe: A web-based survey by the European Network of Urothelium (ENUP). Histopathology 2011;58:579-585.
- Lopez-Beltran A, Montironi R: Non-invasive urothelial neo-plasms: According to the most recent WHO classification. European Urology 2004;46:170-176.
- Lopez-Beltran A: Bladder cancer: Clinical and pathological profile. Scandian Journal of Urology and Nephrology 2008;218:95-109.
- Cheng L, Zhang S, Davidson DD, MacLennan GT, Koch MO, Montironi R, Lopez-Beltran A: Molecular determinants of tumor recurrence in the urinary bladder. Future Oncology 2009; 5:843-857.
- Cheng L, Davidson DD, MacLennan GT, Williamson SR, Zhang S, Koch MO, Montironi R, Lopez-Beltran A: The origins of urothelial carcinoma. Expert Review of Anticancer Therapy 2010;10:865-880.
- P. Harnden et al. Cytokeratin 20 expression by non-invasive transition cell carcinomas: potential for distinguishing recurrent from non-recurrent disease. Histopathology 1995;27:169-174.
- Shazia Mumtaz, Atif Ali Hashmi, Sheema H Hasan, Muhammad Muzzammil Edhi and Mehmood Khan

- Diagnostic utility of p53 and CK 20 immunohistochemical expression grading urothelial malignancies. *International archives of Medicine* 2014;7:1-8.
19. Mahul B Amin, Kiril Trpkov, Antonio Lopez, David Grignon and Members of the ISUP Immunohistochemistry in Diagnostic Urologic Pathology Group. Best practices recommendations in the application of immunohistochemistry in the bladder lesions. *American Journal of Surgical Pathology* 2014;38:1-15.
 20. Cutler SJ, Heney NM, Friedell GH. Longitudinal study of patients with bladder cancer: factors associated with disease recurrence and progression. In Bonney WW. Prout GR J reds. *Bladder cancer. AUA Monographs.* Baltimore: William and Wilkins, 1982;1:35.
 21. Hall RR, Parmar MKB, Richards AB, Smith PH. Proposal for changes in cystoscopic follow up of patients with bladder cancer and adjuvant intravesical chemotherapy. *British Medical Journal.* 1994;308:257-260.
 22. Jost SP, Gosling JA, Dixon JS. The morphology of normal human bladder urothelium. *Journal of Anatomy* 1989;167:103-115.
 23. Newman J, Hicks RM. Detection of neoplastic and paraneoplastic urothelia by combined scanning and transmission electron microscopy of urinary surface of human and rat bladders. *Histopathology.* 1977;1:125-135.
 24. D. C. Ogata, C. A. P. R. Marcondes, F. F. Tuon, W. F. S. Busato J´unior, G. Cavalli, and L. E. A. Czeckzo, "Superficial papillary urothelial neoplasms of the bladder (PTA EPT1): correlation of expression of p53, KI-67 and CK20 with histologic grade, recurrence and tumor progression," *Revista do Colegio Brasileiro de Cirurgioes* 2012;39(5):394-400.
 25. Maather Baqer Hussein, Shoroq Mohammad Addas. Immunohistochemical CYTOKERATIN 20 over expression in urinary bladder carcinoma. *Karbala Journal of Medecine* 2011;4:1077-1083.
 26. El Mawla NG, el-Bolkainy MN, Khaled HM. Bladder cancer in Africa: update. and Seminar, *Oncology* 2001;28:174-178.
 27. Moll R, Lowe A, Laufer J, Franke WW. Cytokeratin 20 in human carcinomas. A new histodiagnostic marker detected by monoclonal antibodies. *American Journal of Pathology* 1992;140:427-47.
 28. Mohammad Hossein Ghaini, Shaghayegh Sadat Esmailnejad, Ali Davati. CYTOKERATIN 20 in transitional Cell Carcinoma of bladder and its relation with prognostic factors. *Iranian journal of Pathology* 2012;7(3):145-150.
 29. A. Alsheikh, Z Mohamedali, E. Jones, J. Masterson, C.B. Gilks. Comparison of the WHO/ISUP classification and CYTOKERATIN 20 expression in predicting the behaviour of low grade papillary urothelial tumors. *Modern Pathology* 2001;14(4):267-272.
 30. Ala S. Jumma, Liwaa H. Mahdi, Hayder M. Al-Aridy, Dhafer S. Alabbasi. Microvessel Density in relation to prognostic parameters in transitional cell carcinoma of urinary bladder. *Kufa Medical Journal* 2011;14(1):81-85.
 31. Beatrice Nico, Vincenzo Benagiano, Domenica Mangieri, Nicola Maruotti, Angelo Vacca and Domenico Ribatti. Evaluation of microvascular density in tumors: pro and cons. *Histology and histopathology* 2008;23:601-607.
 32. Koss LG. Tumors of the urinary bladder. In: *Atlas of Tumor Pathology, Second Series, Fascicle 11.* Washington, DC: Armed Forces Institute of Pathology; 1975 (Suppl. 1985).
 33. Lee R, Droller MJ. The natural history of bladder cancer: implications for therapy. *Urologic Clinics of North America* 2000;27:1-13.
 34. Murphy WM. Current status of urinary cytology in the evaluation of bladder neoplasms. *Human Pathology* 1990;21:886-96.
 35. Koss LG, Deitch D, Ramanathan R, Sherman AB. Diagnostic value of cytology of voided urine. *Acta Cytologica* 1985;29:810-6.
 36. Sayed Abdel Raheem, Abdel Naby Saied, Rabeel Al Shaer, Osama Mustafa, Ali Hassan Ali. The role of CK 20 ,p53 and p63 in differentiation of some urothelial lesions of urinary bladder, immunohistochemical Study. *Open journal of pathology*, 2014;4:181-193.
 37. Jonathan C Goddard, Christopher D Sutton, Peter N Furness, Kenneth J O'Byrne and Roger C Kockelbergh. Microvessel density at the presentation predicts subsequent muscle invasion in superficial bladder cancer. *Clinical cancer research* 2003;9:2583-2586.
 38. Canoglu A, Gogus C, Beduk Y, Orhan D, Tulunay Oand Baltaci S. Microvessel density as a prognostic marker in bladder carcinoma: correlation with tumor grade, stage and prognosis. *International urology and nephrology* 2004;36(3):401-405.