

Papillary squamo transitional cell carcinoma of the uterine cervix: A histomorphological and immunohistochemical study of 10 cases

Shanmuga Priya S^{1,*}, Leena Dennis Joseph², Rajendiran S.³, CN Sai Shalini⁴

¹Associate Professor, ESI Medical College & PGIMS, Chennai, ^{2,3}Professor, ⁴Associate Professor, Sri Ramachandra Medical College & Research Institute, Chennai

***Corresponding Author:**

Email: nikhil166@gmail.com

Abstract

Background: Papillary squamo transitional cell carcinoma (PSCC) is a distinct subcategory of squamous cell carcinoma of uterine cervix with a propensity to late metastasis and late recurrence. It is related to HPV 16 and 18 with high expression of p16. Histologically, it can be misinterpreted as transitional cell carcinoma and other papillary lesions of cervix like papilloma, verrucous carcinoma and cervical intraepithelial neoplasia grade 3 with papillary features.

Aims: To study retrospectively the diagnostic utility of p16 in cervical dysplasia and papillary squamous cell carcinoma at our institution.

Materials and Methods: We retrospectively reviewed all cervical lesions between 2008 and 2012. Ten cases of papillary squamous cell carcinoma were included in our study and further evaluated immunohistochemically by p16 and assessed.

Results: Out of 882 cases of cervical lesions, 107 were malignant squamous cell carcinoma and 62 cases were Cervical intraepithelial neoplasia (CIN). Ten cases out of 107 malignant lesion were diagnosed as papillary squamotransitional cell carcinoma and immunostained with p16 and evaluated. Statistical significant differences between groups were found using semi-quantitative scoring system. The patient ranged in age from 31 yrs to 62 yrs.

Conclusion: PSCC of the uterine cervix are a clinicopathological distinct group that are potentially malignant. p16 was expressed in 71.1% of dysplasia and 100% of papillary squamous cell carcinoma.

Keywords: Papillary squamotransitional cell carcinoma, Cervix, Histopathology, p16

Introduction

Cervical carcinoma is the third most common cancers in women worldwide and second most common cancer in developing world with about 530000 new cases each year resulting in 275000 deaths globally.⁽¹⁾ Cervical carcinoma are caused by persistent infection with high risk human papillomavirus (HR-HPV) that cause cervical intraepithelial neoplasia and squamous cell carcinoma. Cervical carcinoma can be prevented with adequate screening and appropriate management of women with histopathologically diagnosed precancerous conditions of cervix. The current guidelines for cervical carcinoma screening were created as joint recommendations of the American cancer society (ACS), the American society for colposcopy and cervical Pathology (ASCCP) and the American society for clinical Pathology(ASCP) in 2012 and later promoted by American Congress of Obstetricians and Gynecologists(ACOG).⁽²⁾ Microscopically various types of cervical carcinomas are identified and papillary squamous cell carcinoma (PSCC) of cervix is a distinct clinico-pathological subtype of cervical carcinoma with a propensity for late metastasis and late recurrence. It has a different behavior and hence separated from transitional cell carcinoma and other papillary lesions of the cervix. Tumors are etiologically related to human papilloma virus 16 & 18 with high expression of p16. A number of biomarkers including p16, Ki-67 and ProExC immunostain are useful to improve the accuracy of

cervical biopsy interpretation. p16 is a cyclin – dependent kinase inhibitor and surrogate marker for HPV-E7 mediated degradation of retinoblastoma protein (pRb).⁽³⁾ We analyse the histomorphological and immunohistochemical features of 10 cases of PSCC of uterine cervix and identify any viral and histopathological correlation along with review of relevant literature.

Materials and Methods

Reports of all the cervical lesions between 2008-2012 were retrieved from the archives of the Pathology Department. Ten cases of papillary squamous cell carcinoma of uterine cervix diagnosed on a cervical biopsy specimen on routine H & E stained sections were identified and included in the study. The clinical details were retrieved from case files.

The histomorphological features like papillae formation, fibrovascular cores, cell types, presence of atypia/mitosis, stromal invasion and infiltration were noted and evaluated in each case. Five-micron thick paraffin sections were cut and immunostained for p16 using manual polymer detection system with heat induced epitope retrieval and studied their expression in cervical intraepithelial lesions and full blown malignancy. Immunohistochemical staining for p16^{INK4A} protein was performed using the p16 CINTec Histology kit (Mur and Mur) using mouse monoclonal antibody pre-diluted in PBS on both control and test sections according to the manufacturer's instructions.

p16 expression was associated with distinct nuclear and cytoplasmic staining of the epithelial cells and was assessed in each case using a semi-quantitative immunohistochemical score (0-8 points) depending on the intensity as follows:

0-no staining

1+ weak staining

2+moderate staining

3+ strong staining

And the proportion

0-no staining

1+ < 1% positive

2+ 1%-10% positive

3+ 11%-33% positive

4+ 33%-66%

5+ >66% positive⁽⁴⁾

The case was considered positive when nuclear or nuclear and cytoplasmic diffuse block staining in atleast 5% of cells displayed 1+ intensity from basal cell layer of the epithelium was observed⁽⁴⁾

Non-specific focal nuclear staining, cytoplasmic only wispy, scattered single cells and complete lack of staining were considered negative.

Results

Eight hundred and eighty two cases of cervical lesions were diagnosed during the 5-year period from 2008-2012. Of these inflammatory pathology accounts to 480 cases, followed by benign endocervical polyps (233 cases), malignant squamous cell carcinoma (107 cases) and cervical intraepithelial neoplasia (62 cases). Out of 107 malignant cases ten were diagnosed as papillary squamous cell carcinoma and immunostained with p16 (Table 1, Fig. 1). The mean age of the study population was 52 years with a range between 31 and 62 years (Fig. 4). The presenting symptoms included

post-coital bleeding, menorrhagia, post-menopausal bleeding and abnormal Papanicolaou smear, weight loss, fever and pelvic pain. None of the patients had a history of prior, recurrent or subsequent transitional cell carcinoma of urinary tract. On examination bulky friable polypoidal mass was seen involving the cervix. All the 10 cases showed the presence of papillae with a core lined by multilayered atypical epithelial cells of three types. The intermediate cells had a moderate amount of eosinophilic cytoplasm, hyperchromatic to vesicular nuclei with prominent nucleoli. The clear cells were composed of abundant clear cytoplasm, vesicular nucleus with prominent nucleoli. The basaloid cells had scanty cytoplasm, large hyperchromatic nucleus with high nuclear-cytoplasmic ratio. Multinucleated giant cells were also seen in few cases. Mitosis ranged from 1-2 per hpf (Fig. 5, Fig. 7). Semi-quantitative scoring of dysplasia for p16 positivity showed score 7 in 42.9% of cases, score 6 and 5 in 14.3% of cases respectively and negative in 28.6% of cases. The mean dysplasia score is 6.4 with standard deviation of 0.89. Scoring of squamous cell carcinoma for p16 positivity showed score 8 in 40% of cases, score 7 in 20% of cases, score 6 in 30% of cases and score 5 in 10% of cases with a mean carcinoma score being 7 (standard deviation of 1.16) (Table 2) (Fig. 2, Fig. 3, Fig. 10)

Table 1: Distribution of types of cervical lesions

Cervical lesions	No. of cases	%
Inflammatory pathology	480	54
Benign endocervical polyps	233	26
Malignant lesions	107	12
Cervical intraepithelial neoplasia	62	7

Table 2: Immunohistochemical analysis of p16INK4A expression from 10 cervical biopsies containing normal tissues, dysplasia and invasive papillary squamous cell cervical carcinoma evaluated using immunohistological score

	N	P16 immunostaining							
		0	2	3	4	5	6	7	8
Normal	10	10	0	0	0	0	0	0	0
Dysplasia	7	2(28.6%)	0	0	0	1(14.3%)	1(14.3%)	3(42.9%)	0
carcinoma	10	0	0	0	0	1(10%)	3(30%)	2(20%)	4(40%)

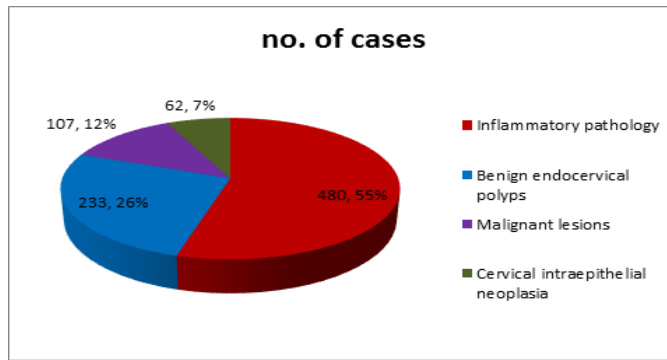


Fig. 1: Distribution of all types of cervical lesions

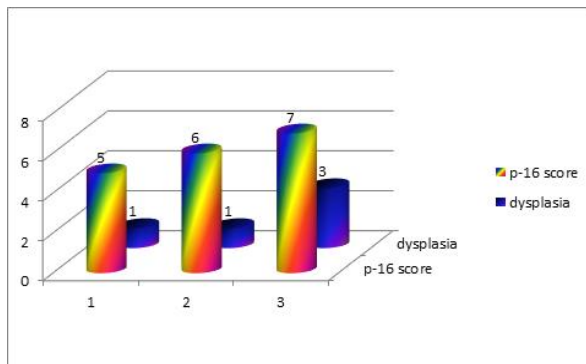


Fig. 2: Distribution of p-16 score in dysplasia

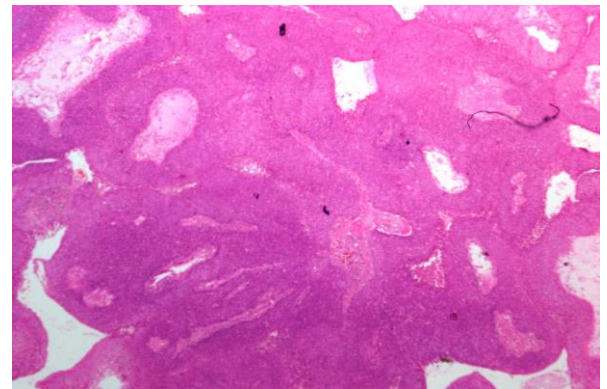


Fig. 5: Microphotograph of papillary SCC (hematoxylin and eosin, x100)

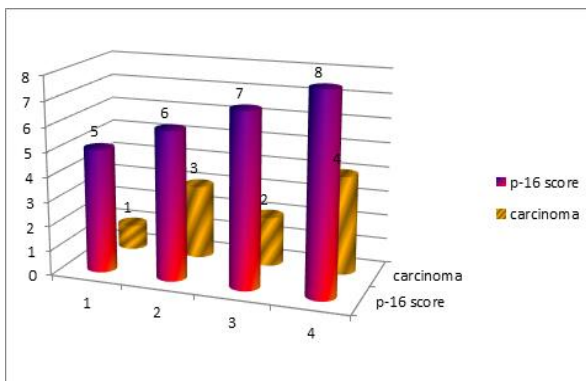


Fig. 3: Distribution of p-16 score in carcinoma

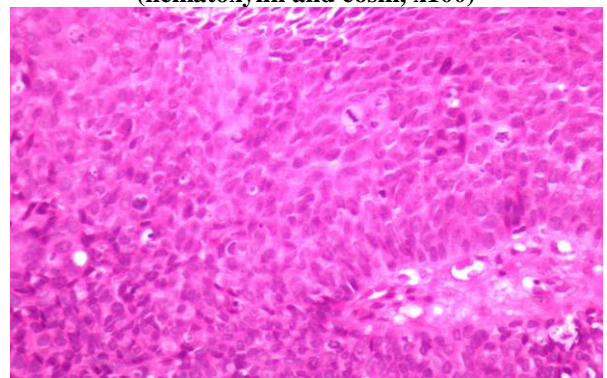


Fig. 6: Microphotograph of papillary SCC (hematoxylin and eosin, x200)

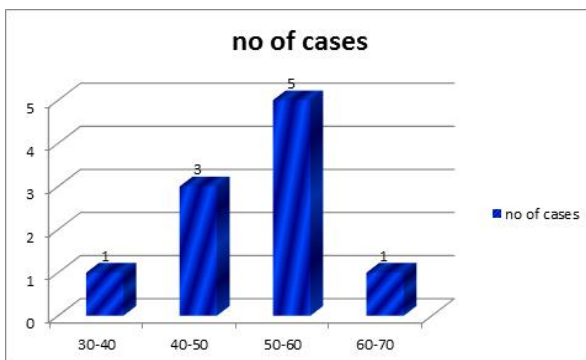


Fig. 4: Age-wise distribution of papillary squamous cell carcinoma

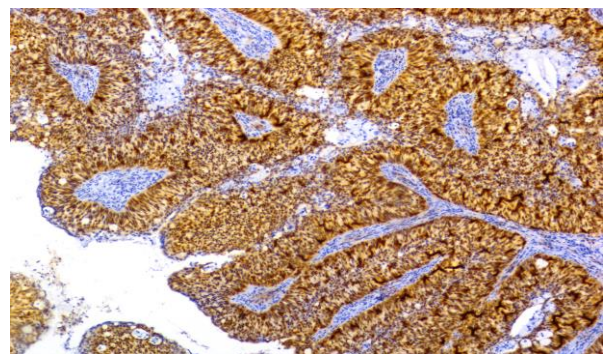


Fig. 7: Microphotograph of papillary SCC (P-16, x100)

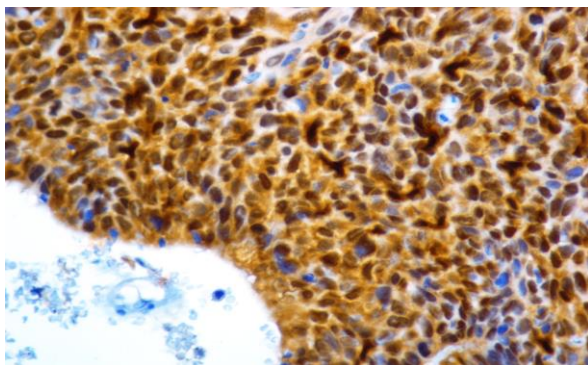


Fig. 8: Microphotograph of papillary SCC (P-16, x200)

Normal cervical epithelium showed consistently low immunohistochemical score from 0-2. Dysplastic epithelium showed high score and the score increased with increasing CIN grade (Fig. 9) (Fig. 10). The semi-quantitative scoring system for p16 expression was easy to perform and gave a variable positive staining in neoplastic lesions. However a small but definite minority of specimen with lower grade of dysplasia had low or negative p16 scores with mild to moderate intensity. The immunohistological score did not allow an absolute cut off point for p16 expression in relation to dysplasia or cancer to be identified. Using non-parametric statistical tests for trend across ordered groups statistical significant differences between groups were found using semi-quantitative scoring system. p16 expression in epithelium was characterized by variable weak to strong diffuse nuclear and cytoplasmic staining. Distinctive positive staining was observed only in dysplastic cells. Normal stromal and normal squamous epithelial cells were consistently negative (Fig. 6, Fig. 8).

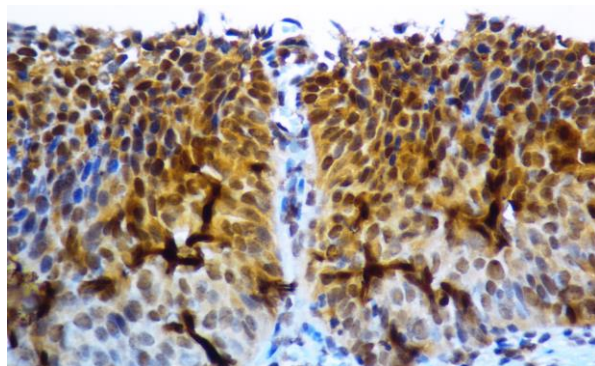


Fig. 9: Microphotograph of CIN-3 (P-16, x200)

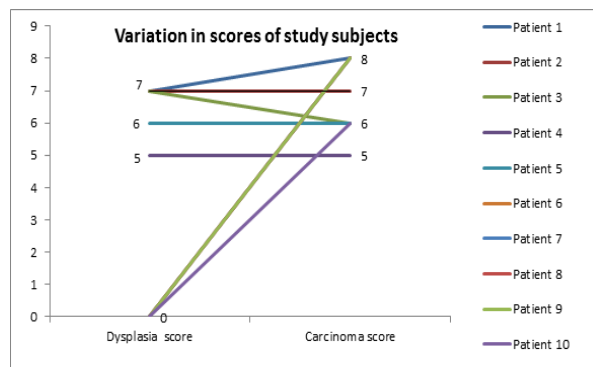


Fig. 10: Chart depicting variation in dysplasia and carcinoma score

Discussion

Cervical carcinoma is associated with HPV infection and represents 53.4% of total number of HPV associated cancer in women.⁽²⁾ HPV negative cervical carcinoma are rare but can occur owing to the limitations in the current detection method or due to loss of HPV DNA with progression of carcinoma.⁽¹⁾ Papillary carcinoma of uterine cervix with transitional or squamous differentiation are rare tumors that often resemble transitional cell carcinoma of urinary tract.^(5,22,23) These tumors were initially identified by Marsh in 1952.⁽⁶⁾ In his study three cases turned out to be malignant. In Samuel Buckholz/OY/Caterpillar1958, Kazal reported 20 cases of squamous cell papilloma of cervix of which two showed transformation to squamous cell carcinoma. These tumors were characterized as papillary squamous cell carcinoma by Randall et al in 1986.⁽⁷⁾ It remains unclear whether papillary carcinoma of cervix represent two clinicopathologically distinct group of tumors (squamous and transitional) or if they reflect morphologic continuum within a single clinically homogeneous entity. The Armed Forces Institute of Pathology fascicle uses the terms squamous and transitional interchangeably to refer to these papillary carcinoma of cervix.^(5,8) Immunostaining with p16 is a surrogate marker to detect HPV infection, can be used to detect precancerous and cervical neoplasms and to minimize unnecessary surveillance and invasive work-up for women with low risk cervical carcinomas. p16 is never observed in normal cervical epithelium. Thus p16 expression appears to be a specific and sensitive biomarker of cervical neoplasia confirming the results of previous smaller series. Increased expression of p16 in setting of CIN probably occurs mainly as a result of inactivation of RB by high risk HPVs. Increased high p16 expression scores were seen in cervical specimens showing higher grades of dysplasia or invasive carcinoma, lesions known to be closely associated with high risk HPV infection.^(1,7,9,10) Women with dysplasia if left untreated can progress to develop invasive cancer. This emphasizes the need for predictive biomarkers that can identify women with cervical

dysplasia who may be at risk of developing carcinoma. The combined assay for p16 and Ki-67 markers are more sensitive in detecting CIN3.⁽²⁾ The combination of mRNA expression levels of HPV biomarkers could be used in diagnosing high grade cervical lesions in cytology and may be particularly useful in helping to triage patients with ASCUS cytology or with positive HPV test and negative Pap test.^(2,10) The present study suggests that Papillary squamous cell carcinoma of cervix is a distinct clinico-pathological entity which is supported by previous detailed report of PSCC described by Randall et al (9 cases) all of which had squamous differentiation.⁽⁷⁾ Cases reported by Koenig and Ng had cells with transitional morphology but was proved to be of squamous origin by immunohistochemistry with aggressive behavior.⁽¹¹⁾ Drew analysed 20 cases and stained for uroplakin III, p63 and p16. 8 were positive for p16 and p63 and negative for uroplakin and concluded that papillary squamotransitional cell carcinoma lack transitional cell differentiation and show features similar to conventional squamous cell carcinoma.⁽¹²⁾ Odida studied 20 cases in older women with distinct subtype.⁽¹³⁾ Mirhashemi studied on 12 cases and 50% of these showed presence of HPV DNA and thus differentiates the clinical behavior of PSCC with other SCC of cervix.⁽¹⁴⁾ Brinck et al studied 3 cases with HPV positivity.^(15,24,25) Nafussi studied 2 cases in post-menopausal women at an advanced stage despite superficial location.⁽⁹⁾ Thus these findings support the hypothesis that SCC of cervix are heterogeneous group of tumors. Therefore high degree of suspicion on the part of clinician and awareness of this entity by pathologist are required to arrive at an accurate diagnosis.⁽¹⁹⁾ In our study dysplastic features were seen or pre-invasive cervical lesion was diagnosed in 7 cases. This limits the ability to study the role of p16 expression as a predictive marker for the development of invasive carcinoma.

While the association between increasing levels of p16 expression and higher grades of cervical dysplasia was striking in our study, a small minority of cases with dysplasia was negative for p16. Naturally it would be of value to know whether cases such as these would have regressed spontaneously or whether p16 expression is a predictive marker for progression in cervix. Long term follow-up is not yet available in our study cohort. We used semi-quantitative immunohistological scoring system which gave a more detailed picture of spread of expression scores when compared to the simple positive versus negative scores and can be recommended for further studies. Schorge et al studied the importance of p16 in cervical carcinoma and exhibited a higher mean expression score for in-situ (7.4, $p < 0.0001$) and invasive carcinoma (6.6, $p < 0.0001$) versus control.⁽¹⁶⁾ A cut-off p16 expression score of 5 had a sensitivity of 94.5% and specificity of 100%. In our study the mean dysplasia score is 6.4 and that of carcinoma score is 7.

Moreover, since transcription of E7 oncogene is required for p16 up regulation, it has been suggested that carcinomas overexpressing p16 represent those tumors in which HPV has been involved in the carcinogenic process.^(4,20)

Conclusion

The mortality rates from cervical carcinoma are mainly due to lack of early identification by proper screening. Routine screening should include regular Pap smear, HPV mRNA assay, p16, Ki-67 and ProExC test (immunocytochemical assay) for early detection and to minimize unnecessary surveillance. These biomarkers are efficient in not only detecting HR-HPV, LR-HPV precancerous lesions but also considered in the HPV-negative group.^(10,17,18,21)

In our study, small number papillary squamous cell carcinomas of cervix are evaluated for p16 expression and it is seen in 71.1% of dysplasia and 100% in PSCC cases.

Acknowledgement

The authors are grateful to the technical staff of Sri Ramachandra Medical College for processing and staining the samples and to the statistician for statistical analysis.

References

1. Mc Graw SL, Ferrante JM. Update on prevention and screening of cervical cancer. *World J Clin Oncol* 2014;4:744-752.
2. Schlichte MJ, Guidry J. Current cervical carcinoma screening guidelines. *J. Clin Med* 2015;4:918-932.
3. Lim S, Lee M, Cho I, Hong R and Lim SC. Efficacy of p16 and Ki-67 immunostaining in the detection of squamous intraepithelial lesions in a high risk HPV group. *Oncology letters* 2016;11:1447-1452.
4. Lesnikova I, Lidang M, Hamilton-Dutoit S, Koch J. p16 as a diagnostic marker of cervical neoplasia: a tissue microarray study of 796 archival specimens. *Diagn Pathol* 2009;4:22.
5. Koenig C, Turnicky RP, Kankam CF, Tavassoli FA. Papillary squamotransitional cell carcinoma of the cervix. A report of 32 cases. *Am J Surg Pathol* 1997;21:915-921.
6. Marsh MR. Papilloma of the cervix. *Am. J. Obstet Gynecol* 1952;64:281-91.
7. Randall ME, Andersen WA, Mills SE, Kim JC. Papillary squamous cell carcinoma of the uterine cervix: A clinicopathologic study of nine cases. *Int J Gynecol Pathol* 1986;5:1-10.
8. Kurman RJ, Norris HJ, Wilkerson E, Washington DC. Armed Forces Institute of Pathology 1992. Atlas of tumor Pathology. Tumors of cervix, vagina and vulva. 75-76.
9. Nafussi AI, Yusif AI. Papillary squamotransitional cell carcinoma of the uterine cervix-an advanced stage disease despite superficial location: report of two cases and review of the literature. *Eur J Gynaecol Oncol* 1998;19:455-457.
10. Ozaki S, Zen Y, Inare M. Biomarker expression in cervical intraepithelial neoplasia: Potential progression predictive factors for low-grade lesions. *Hum Pathol* 2011;42:1007-1012.

11. Ngwk. Thin layer (liquid based) cytology findings of papillary squamotransitional cell carcinoma of cervix. Review of cases of 4 year period with emphasis on potential diagnostic pitfalls. *Acta cytol* 2003;47: 141-147.
12. Drew PA, Hong B, Massoll NA, Ripley DL. Characterization of papillary squamotransitional cell carcinoma of cervix. *J Low Gent tract Dis* 2005;9:149-53.
13. Odida M. Papillary squamous cell carcinoma of the cervix in Uganda: A report of 20 cases. *Gynecol Oncol* 1996;63:388-391.
14. Mirhashemi R, Ganjei- Azar P, Nadji M, Lambrou N, Atamdede F, Averette HE. Papillary squamous cell carcinoma of uterine cervix: an immunophenotypic appraisal of 12 cases. *Gynecol Oncol* 2003;90:657-61.
15. Brinck U, Jakob C, Bau O, Fuzesi L. Papillary squamous cell carcinoma of the uterine cervix: report of three cases and a review of its classification. *Int J Gynecol Pathol* 2000;19:231-5.
16. Schorge JO, Lea JS, Elias KJ, Rajanbabu RB, Coleman RL, Miller DS et al. p16 as a molecular biomarker of cervical adenocarcinoma. *Am. J. Obstet Gynecol* 2004;190:668-673.
17. Asotic A, Taric S, Asotic J. Correlation of cervical smear and pathohistological findings. *Med. Arh.* 2014;68:106-109.
18. Austin RM, Onisko A, Druzdzel. MJ. The Pittsburgh cervical cancer screening model-a risk assessment tool. *Arch Pathol Lab Med* 2010;134:744-750.
19. Anand M, Deshmukh SD, Gulati HK. Papillary squamotransitional cell carcinoma of the uterine cervix: a histomorphological and immunohistochemical study of nine cases. *Ind J Med Paed Oncol* 2013;34:66-71.
20. Bosch FX, Lorincz A, Munoz N, Meijer CJLM, Shah KV. The causal relation between human papillomavirus and cervical cancer. *J Clin Pathol* 2002;55:244-265.
21. Fichtali K, Khadija C, Rajae B, Aboufalah A et al. Papillary squamous cell carcinoma of uterine cervix with negative HPV: report of a case and literature review. *J of Gynecol Surg* 2012;28:172-175.
22. Ollayos CW, Lichy J, Duncan BW, Ali IS. Papillary squamous cell carcinoma of the uterine cervix: report of a case with HPV 16 DNA and brief review. *Gynecol Oncol* 1996;63:388-91.
23. Kokka F, Verma M, Singh N, Faruqi A et al. Papillary squamotransitional cell carcinoma of the uterine cervix: report of three cases and review of literature. *Pathology* 2006;38:584-6.
24. Reid R, Stanhope R, Herschman BR, Booth E, Phibbs GD, Smith JP. Genital and cervical cancer. Evidence of an association between subclinical papillomavirus infection and cervical malignancy. *Cancer* 1982;50:377-387.
25. Griffiti NR, Bevan IS, Lewis FA, Wells M, Young LS. Demonstration of multiple HPV types in normal cervix and cervical squamous cell carcinoma using polymerase chain reaction on paraffin wax embedded material. *J Clin Pathol* 1990;43:52-56.