

A cytohistopathological study to evaluate the diagnostic role of Fine-needle aspiration cytology (FNAC) in salivary gland lesions

Rashmi Jain^{1,*}, Ankit Jain²

¹Lab Head, Consultant Pathologist, SRL Diagnostics Ltd., Bhopal, Madhya Pradesh, ²Resident, Dept. of Anatomy, Gandhi Medical College, Bhopal, Madhya Pradesh

***Corresponding Author:**

Email: dr.rashmi71286@gmail.com

Abstract

Background & Objectives: FNAC is used as a preoperative diagnostic tool to differentiate between benign and malignant salivary glands (SGs) tumors. The aim of this study was to evaluate the sensitivity, specificity and diagnostic accuracy of the FNAC for SGs lesions.

Methods: FNAC was carried out in 144 patients with various SGs lesions and classified. Out of 144 cases, only 59 cases were available for histopathological examination. FNAC diagnosis was compared with the final histological diagnosis; and then sensitivity, specificity and diagnostic accuracy of the FNAC for SGs lesions were calculated.

Results: Parotid gland was involved in 54.86% cases, whereas submandibular and minor SGs were involved in 40.27% and 4.86% cases respectively. Non-neoplastic lesions were found in 50.7% cases, whereas benign and malignant lesions were found in 36.8% and 12.5% cases respectively. Submandibular gland was commonly (52.05%) involved in non-neoplastic lesions whereas in benign and malignant lesions, parotid gland was involved 64.15% and 77.78% cases respectively. Chronic sialadenitis (58.9%), pleomorphic adenoma (90.56%) and mucoepidermoid carcinoma (55.55%) were most common lesions among non-neoplastic, benign and malignant lesions respectively. Sensitivity, specificity and diagnostic accuracy of FNAC for neoplastic SGs lesions were 87.50%, 97.44 % and 94.54% respectively.

Interpretations & Conclusions: The high sensitivity, specificity and diagnostic accuracy of the FNAC indicates that it may serve as a good pre-operative diagnostic technique for SGs lesions. This study highlights the diagnostic value of FNAC in differentiating benign from malignant lesions which are useful in the planning of further management.

Keywords: Diagnostic accuracy, FNAC, Salivary gland lesions, Sensitivity

Introduction

Salivary glands (SGs) are compound exocrine glands which are mainly composed of a ductal and an acinar portion. They are classified into major and minor SGs which are found throughout the submucosa of oral cavity.⁽¹⁾ SGs lesions are ranged from non-neoplastic lesions like inflammation, cysts etc. to neoplastic benign or malignant lesions. Neoplasm of the SGs is relatively uncommon and represents less than 2% of all tumors of the human.⁽²⁾ SGs tumors are of particular interest to both pathologists and surgeons because they show considerable variations with regard to biological and clinical behavior; and pose a diagnostic challenge due to their complex histopathological features.^(3,4)

FNAC is a minimally invasive, inexpensive and widely accepted routinely diagnostic technique for various palpable swellings of the body like breast lump, lymph nodes etc.^(5,6) Currently, FNAC is a simple, reliable and useful diagnostic technique for the evaluation of SGs lesions.⁽⁷⁾ It is a relatively painless and safe procedure for a rapid and early diagnosis. It provides better preservation of cellular detail and avoids artifacts which are caused by cutting knife of microtome in case of paraffin block sections.⁽⁸⁾ The diagnostic sensitivity and specificity of FNAC varied from 81-100% and 94-100% respectively, whereas diagnostic accuracy varied from 61- 80%.⁽⁹⁾ FNAC of the SGs can distinguish inflammatory lesions from

neoplastic conditions and primary tumors from metastatic tumors. Thus, it gives valuable information to the surgeons for the planning of proper therapeutic management, whether conservative management given for non-neoplastic lesions, local excision or radical surgery done for neoplastic lesions and chemotherapy or radiotherapy given for metastasis disorder.⁽¹⁰⁾

The present study has been undertaken to assess the preoperative cytological findings of salivary glands lesions and correlate these findings with the postoperative histopathological findings, in order to evaluate the sensitivity, specificity and diagnostic accuracy of FNAC.

Materials and Methods

The present study was carried out in the Department of Pathology, Gandhi Medical College, Bhopal (M.P.). 144 patients of various SGs lesions who came to cytology lab of our institute over a period of two years (January 2014 to December 2015) were taken up for the study, after the permission from institutional ethics committee. Detailed history and relevant clinical examination was performed in all cases. Prior to FNAC procedure, Informed consent was taken and then FNAC was done in each case irrespective of the age group and sex. The aspiration of material from the SGs lesions was done by using a 10cc disposable syringe and 23 G needle under aseptic precautions. Repeat aspiration was

done for insufficient aspirate and the character of aspirate was noted. Aspirates were smeared on clean slides and wet fixed in 95% ethanol. In each case, three alcohol fixed smears were prepared, one smear was stained with Haematoxylin & Eosin (H&E) stain and another stained with Papanicolaous stain. One smear was kept unstained for any further required stain. Cytological diagnosis was carried out and SGs lesions were classified under three groups which included non-neoplastic lesions, benign tumor and malignant tumor.⁽¹¹⁾

Out of 144 cases diagnosed by FNAC, only 59 cases of SGs lesions were available for histopathological examination (HPE) following appropriate surgery. All the biopsy specimens were fixed in 10% formal saline and processed for paraffin embedding, sectioning and H&E staining. Histological examination was done and classified.⁽¹¹⁾

Data was analyzed by using Statistical Package for Social Sciences (SPSS) version 15.0 (Chicago, IL). Categorical data were expressed as frequency counts (percentages). Histopathological findings of neoplastic SGs lesions were compared with preoperative cytological findings. The histological diagnosis was considered as the gold standard for the assessment of sensitivity and specificity of FNAC. The cases which were diagnosed as malignant SGs lesions by both cytology and histopathology were considered as true positive (TP), whereas the cases which were diagnosed as malignant SGs lesions by cytology but diagnosed as benign SGs lesions by histopathology were considered as false positive (FP). The cases which were diagnosed as benign SGs lesions by both cytology and histopathology were considered as true negative (TN), whereas the cases which were diagnosed as benign SGs lesions by cytology but diagnosed as malignant SGs lesions by histopathology were considered as false negative (FN). The sensitivity, specificity, positive predictive value (PPV) negative predictive value (NPV), and overall accuracy of FNAC for diagnosis of neoplastic SGs lesions were calculated. The measurement of agreement between two different (cytological and histological) methods was done by calculating Cohen's Kappa (κ) value.

Results

In the present study, SGs lesions were found predominantly (59.03% cases) in males. Overall, male to female ratio was 1.44:1. Age range for all SGs lesions was 2 years to 68 years with maximum incidence in 4th decade. Out of 144 cases of SGs lesions, parotid gland was involved in 79 (54.86%) cases, whereas submandibular and minor SGs were involved in 58 (40.27%) and 7 (4.86%) cases respectively. No case of sublingual gland lesion was observed in the present study. [Table 2] Cytological diagnosis of non-neoplastic SGs lesions were found in 73 (50.7%) cases, whereas benign and malignant

neoplastic SGs lesions were found in 53 (36.8%) and 18 (12.5%) cases respectively. [Table 1]

Among non-neoplastic SGs lesions (n=73), submandibular gland was involved in 38 (52.05%) cases, followed by parotid gland was involved in 32 (42.46%) cases. Only 4 (5.47%) cases were found in minor SGs. [Table 2] In cytological diagnosis of non-neoplastic SGs lesions, 43 (58.9%) cases were diagnosed as chronic sialadenitis whereas suppurative sialadenitis, cystic and tubercular lesions were diagnosed in 16 (21.91%), 9 (12.32%) and 5 (6.84%) cases respectively. [Table 1]

Among benign neoplastic SGs lesions (n=53), 34 (64.15%) cases were involved in parotid gland, whereas submandibular glands and minor SGs were involved in 17 (32.07%) and 2 (3.77%) cases respectively. [Table 2] In cytological diagnosis of benign neoplastic SGs lesions, pleomorphic adenoma was diagnosed in 48 (90.56%) cases, whereas Warthin's tumor and basal cell adenoma was diagnosed in 2 (3.77%) and 3 (5.66%) cases respectively. [Table 1]

Among malignant neoplastic SGs lesions (n=18), parotid gland was involved in 14 (77.78%) cases, whereas submandibular glands and minor SGs were involved in 3 (16.67%) and 1 (5.55%) cases respectively. [Table 2] In cytological diagnosis of malignant neoplastic SGs lesions, 10 (55.55%) cases were diagnosed as mucoepidermoid carcinoma, whereas acinic cell carcinoma and squamous cell carcinoma was diagnosed in 1 (5.55%) and 3 (16.66%) cases respectively. Adenoid cystic carcinoma and salivary duct carcinoma was diagnosed in 2 (11.11%) cases each. [Table 1]

Among the preoperatively diagnosed 73 cases of non-neoplastic SGs lesions by FNAC, HPE was carried out in 4 cases. On HPE, all 4 cases were diagnosed as chronic sialadenitis, which was similar to the diagnosis reported by FNAC. [Table 3]

HPE was done in 40 cases of cytologically diagnosed benign neoplastic SGs lesions. Out of 36 cases of cytologically diagnosed pleomorphic adenoma, 34 cases were confirmed on HPE. Two cases of pleomorphic adenoma were misdiagnosed by FNAC, which were correctly diagnosed as mucoepidermoid carcinoma and adenoid cystic carcinoma by HPE. [Table 3] These two cases were considered as false negative (FN). [Table 4] Cytological diagnosis of two cases of each Warthin's tumor and basal cell adenoma were consistent with histopathological diagnosis. [Table 3] Thus, 38 cases were diagnosed as benign neoplastic SGs lesions by both cytology and histopathology, hence these cases were considered as true negative (TN). [Table 3 & 4]

Among the cytologically diagnosed 18 cases of malignant neoplastic SGs lesions, HPE was done in 15 cases. Out of 10 cases of mucoepidermoid carcinoma diagnosed by FNAC, 9 cases were confirmed on HPE. One case of mucoepidermoid carcinoma was

misdiagnosed by FNAC, which was correctly diagnosed as pleomorphic adenoma by HPE. This one case was considered as false positive (FP). [Table 3 & 4] Cytological diagnosis of one case of adenoid cystic carcinoma and two cases of each salivary duct and squamous cell carcinoma were consistent with histopathological diagnosis. [Table 3] Thus, in malignant neoplastic SGs lesions cytological diagnosis of 14 cases were consistent with histopathological diagnosis. Hence, these cases were considered as true positive (TP). [Table 3 & 4]

Diagnostic sensitivity and specificity of FNAC for diagnosis of neoplastic SGs lesions was found 87.50% and 97.44% respectively. Positive Predictive Value (PPV) was found 93.33% and Negative Predictive Value (NPV) was found 95.00%. Diagnostic accuracy of FNAC for all neoplastic SGs lesions was found 94.54%. Cohen's Kappa (κ) index value was found 0.865, which shows that the strength of agreement between two different (FNAC and HPE) methods were very good. [Table 4]

Discussion

Various studies showed that SGs lesions were occurred more frequently in age of 4th and 5th decade of life.^(12,13,14) In the present study, SGs lesions were observed in all age groups with age range from 2 to 68 years, but the highest incidence was found in 4th decade. Thus our findings were explaining the trend of delayed presentation of SGs lesions, which is similar to the findings of earlier researchers.^(12,13,14) Ersoz C. et al, observed that SGs lesions were affected more in

female.⁽¹⁵⁾ In contrast to above, we observed that SGs lesions were found predominantly in male, which is similar to the finding reported by Cajulis RS. et al⁽⁶⁾ and Gandhi SH. et al.⁽¹²⁾

Considering all SGs lesions, parotid gland was most commonly involved gland in our study. [Table 2] This finding is consistent with study done by earlier researchers.^(6,8,13) In the present study, most common non-neoplastic SGs lesion was chronic sialadenitis and most of the non-neoplastic SGs lesions were found in submandibular gland. [Table 1 & 2] These findings are in concurrence with the findings of Gandhi SH. et al⁽¹²⁾ and Nanda S. et al.⁽¹³⁾ In the present study, pleomorphic adenoma was the most common benign lesion and parotid gland was most frequently involved gland among benign neoplastic SGs lesions. [Table 1 & 2] These findings are similar to the findings reported by Gandhi SH. et al⁽¹²⁾ and Ahrnad S. et al.⁽¹⁶⁾ Among malignant neoplastic SGs lesions, parotid gland was the most commonly affected gland in our study. [Table 2] This finding is in concurrence with the finding of Ahrnad S. et al⁽¹⁶⁾ and Laishram RS. et al,⁽¹⁷⁾ but in contrast to our finding Gandhi SH. et al, found that minor salivary glands were the commonest site for malignant neoplastic SGs lesions.⁽¹²⁾ Akhter et al, found that adenoid cystic carcinoma was the commonest malignant neoplastic SGs lesion.⁽¹⁸⁾ In contrast to above, we found that mucoepidermoid carcinoma was the commonest malignant neoplastic SGs lesion [Table 1], which is consistent with the finding reported by Nanda S. et al⁽¹³⁾ and Khandekar MM. et al.⁽¹⁹⁾

Table 1: FNAC diagnosis of Salivary gland lesions (n=144)

Non – neoplastic lesions		Neoplastic			
		Benign		Malignant	
Diagnosis	No. (%)	Diagnosis	No. (%)	Diagnosis	No. (%)
Chronic sialadenitis	43 (58.9%)	Pleomorphic adenoma	48 (90.56%)	Mucoepidermoid carcinoma	10 (55.55%)
Suppurative sialadenitis	16 (21.91%)	Warthin's tumor	2 (3.77%)	Adenoid cystic carcinoma	2 (11.11%)
Cystic lesion	9 (12.32%)	Basal cell adenoma	3 (5.66%)	Salivary duct carcinoma	2 (11.11%)
Tubercular	5 (6.84%)	-	-	Squamous cell carcinoma	3 (16.66%)
-	-	-	-	Acinic cell carcinoma	1 (5.55%)
Total	73 (100%)	Total	53 (100%)	Total	18 (100%)

Table 2: Distribution of salivary gland lesions according to site involved (n=144)

Site	Total cases		Diagnosis					
	No.	%	Non-neoplastic		Neoplastic			
			No.	%	Benign		Malignant	
	No.	%			No.	%	No.	%
Parotid gland	79	54.86%	31	42.46%	34	64.15%	14	77.78%
Submandibular gland	58	40.27%	38	52.05%	17	32.07%	3	16.67%
Minor salivary gland	7	4.86%	4	5.47%	2	3.77%	1	5.55%
Total	144	100%	73	100%	53	100%	18	100%

Knowledge of the type of tumor, whether it is benign or malignant are required for proper management of the SGs lesions. Ideally, classification of the tumor is done on the basis of histology, which is almost always accurately predicting the type of SGs lesion. But the drawback of histopathology is that an incisional biopsy has a risk of contamination of operative field with tumor cells and may causes difficulty in subsequent surgical management.⁽²⁰⁾ FNAC has many advantages at this point. FNAC has been found to be use not only to segregate the non-neoplastic lesions from neoplastic lesions, but also has a role in specific diagnosis of SGs lesions.⁽²¹⁾

Tessy PJ. et al, found that majority of the non-neoplastic SGs lesions were correctly diagnosed by FNAC.⁽⁵⁾ As most of the non-neoplastic SGs lesions were treated conservatively, only 5.47% [4/73] cases of non-neoplastic SGs lesions were available for histological correlation in this study and all cases were correlated with cytological diagnosis. [Table 3] This finding is in line with the study done by Gandhi SH. et al.⁽¹²⁾

Among benign neoplastic SGs lesions, 75.47% [40/53] cases were available for histological correlation in this study. Out of 36 cases of pleomorphic adenoma diagnosed by FNAC, 94.44% [34/36] cases were found to be correct on histopathology in this study. [Table 3, Fig. 1 & 2] This finding is similar to the study done by Tessy PJ. et al, who found cyto-histopathological correlation in 86.66% cases of pleomorphic adenoma.⁽⁵⁾ All two cases of each Warthin's tumor and basal cell adenoma were correctly diagnosed by FNAC in this study. [Table 3, Fig. 3 & 4]

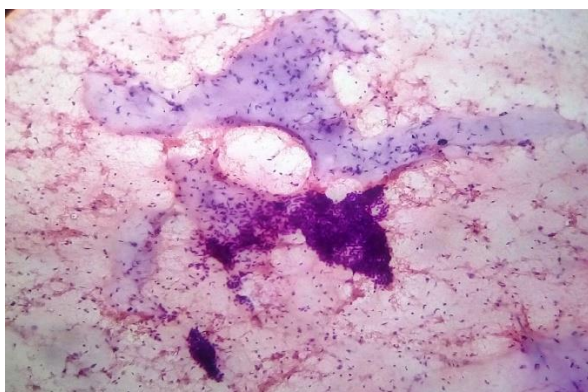


Fig. 1: A aspiration biopsy smear of Pleomorphic adenoma showing cluster of epithelial cells along with characteristic faint bluish chondromyxoid area (100X, H&E)

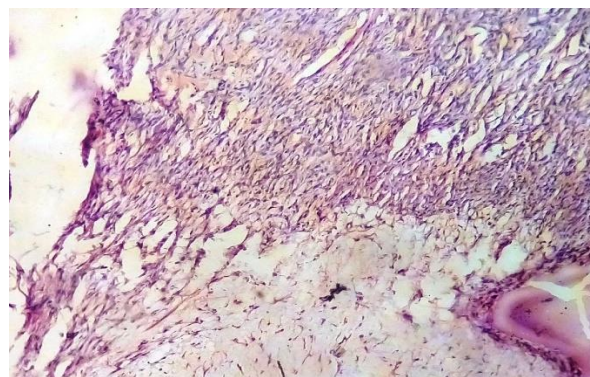


Fig. 2: A histologic section of Pleomorphic adenoma showing cellular epithelial component with myxoid stroma (100X, H&E)

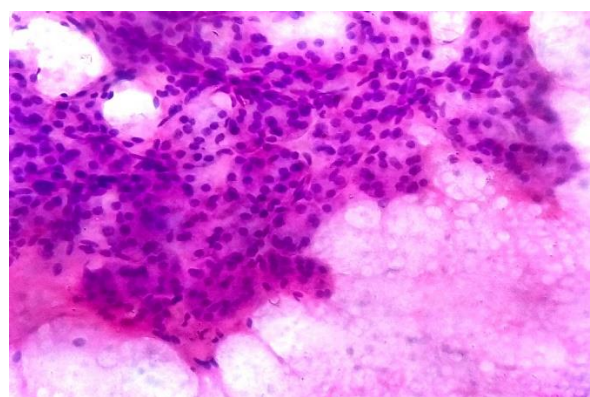


Fig. 3: A aspiration biopsy smear of Warthin's tumor showing sheets of prominent oncocytic epithelial cells with abundant eosinophilic cytoplasm and cystic fluid seen in background (100X, H&E)

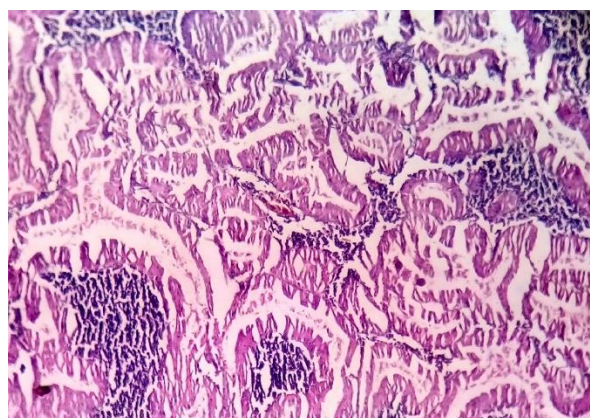


Fig. 4: A histologic section of Warthin's tumor showing multicystic tumor with oncocytic cells lining papillary intracystic projections of lymphoid tissue with prominent follicles (100X, H&E)

Table 3: Cyto- histopathological correlation of salivary gland lesions (n=59)

Types of salivary glands lesion	Cytological diagnosis	Histopathological diagnosis		
		Similar to cytological diagnosis	Dissimilar to cytological diagnosis	
			Diagnosed as benign lesion	Diagnosed as malignant lesion
Non-neoplastic lesion				
Chronic sialadenitis	4	4	-	-
Benign lesion				
Pleomorphic adenoma	36	34	-	2*
Warthin's tumor	2	2	-	-
Basal cell adenoma	2	2	-	-
Malignant lesion				
Mucoepidermoid carcinoma	10	9	1**	-
Adenoid cystic carcinoma	1	1	-	-
Salivary duct carcinoma	2	2	-	-
Squamous cell carcinoma	2	2	-	-

* Two case of pleomorphic adenoma on FNAC was diagnosed as malignant lesion (Mucoepidermoid carcinoma and adenoid cystic carcinoma) by HPE. ** One case of Mucoepidermoid carcinoma on FNAC was diagnosed as benign lesion (pleomorphic adenoma) by HPE.

Among malignant neoplastic SGs lesions, 83.33% [15/18] cases were available for histological correlation in this study. Out of 10 cases of mucoepidermoid carcinoma diagnosed by FNAC, 90.0% [9/10] cases were found to be correct on histopathology in this study. [Fig. 5 & 6] All two cases of each salivary duct and squamous cell carcinoma were correctly diagnosed by FNAC in this study. Cytological diagnosis of one case of adenoid cystic carcinoma was consistent with histopathological diagnosis. [Table 3, Fig. 7]

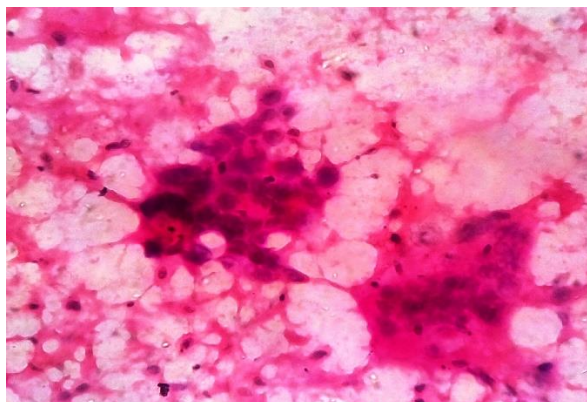


Fig. 5: A aspiration biopsy smear of Mucoepidermoid carcinoma showing pleomorphic epidermoid cells with hyperchromatic nuclei and few mucus secreting cells (100X, H&E)

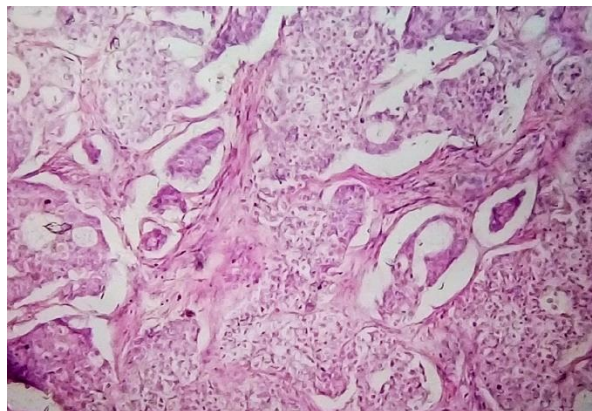


Fig. 6: A histologic section of Mucoepidermoid carcinoma showing sheets, groups and few glands composed of moderately differentiated epidermoid cells, intermediate cells and scanty mucus producing cells (100X, H&E)

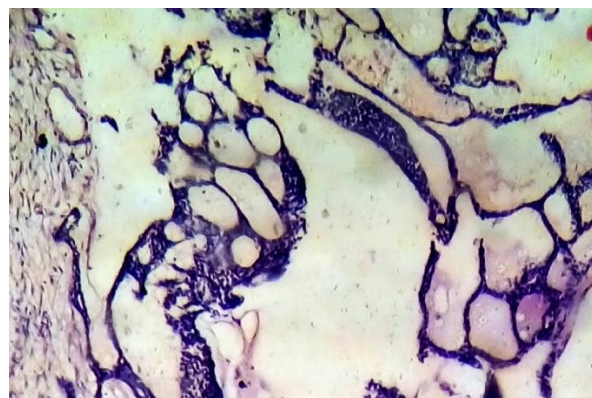


Fig. 7: A histologic section of Adenoid cystic carcinoma showing cribriform configuration of tumor with small dark basal epithelial cells lining cystic spaces filled with homogenous material (100X, H&E)

One case of each mucoepidermoid carcinoma and adenoid cystic carcinoma was misdiagnosed as pleomorphic adenoma by FNAC in this study. [Table 3] These two cases were considered as false negative. The rate of false negative diagnosis on cytology reported in literature ranges from 0 to 37%.⁽²²⁾ In our study false negative rate on cytology was 12.5%.

The false positive rate has been reported to be low with greater accuracy in FNAC and rate ranges from 0 to 10% in the literature.⁽²³⁾ In the present study, false positive rate was 2.56% and this was due to histopathologically confirmed one case of pleomorphic adenoma was misdiagnosed as mucoepidermoid carcinoma on FNAC. [Table 3]

Various studies had been reported the diagnostic utility of FNAC in the preoperative assessment of SGs lesions.^(5,24,25) In the present study, sensitivity and specificity of FNAC for diagnosis of neoplastic SGs lesions was 87.5% and 97.44% respectively. The Positive Predictive Value (PPV) was 93.33% and Negative Predictive Value (NPV) was 95.00%. [Table 4 & 5] These findings are consistent with those reported by earlier observers.^(25,26,27) The diagnostic accuracy of FNAC in detecting neoplastic SGs lesions was found 94.54% in the present study, which is similar to the study done by Stow N. et al and Vaidya S. et al. who

reported diagnostic accuracy of FNAC for SGs lesions was 92.3% and 96.55% respectively. [Table 5] In the study by Faizal B. et al, found moderate cyto-histological agreement with Cohen's Kappa (κ) index value of 0.66.⁽²⁸⁾ In the present study, statistical analysis showed a very good cyto-histological agreement with a Cohen's Kappa (κ) index value of 0.865. [Table 4] These results indicate that FNAC can be performed as an initial diagnostic method for SGs lesions because it provides a good pre-operative screening modality for neoplastic SGs lesions.

Table 4: Fine needle aspiration cytology as screening test for salivary gland neoplastic lesions

Cytological diagnosis	Histopathological diagnosis		
	Malignant neoplastic	Benign neoplastic	Total
Malignant neoplastic	14 (TP)	1 (FP)	15
Benign neoplastic	2 (FN)	38 (TN)	40
Total	16	39	55

* Sensitivity = 87.50%, Specificity = 97.44 %, Positive Predictive Value (PPV) = 93.33%, Negative Predictive Value (NPV) = 95.00 %, Accuracy = 94.54%, Cohen's Kappa (κ) value = 0.865.

Table 5: Comparison of screening test of FNAC for salivary gland neoplastic lesions with previous study

Authors	Sensitivity	Specificity	PPV	NPV	Diagnostic accuracy
Tessy PJ. et al ⁽⁵⁾	56.3%	97.7%	-	-	86.7%
Vaidya S. et al ⁽²⁴⁾	81.82%	100%	100%	95.9%	96.55%
Stow N. et al ⁽²⁵⁾	86.9%	92.3%	96.8%	86.6%	92.3%
Cristallini EG. et al ⁽²⁶⁾	97.64%	98.43%	-	-	-
Young JE. et al ⁽²⁷⁾	84%	98%	-	-	-
Our study	87.5%	97.44%	93.33%	95%	94.54%

Conclusion

The sensitivity and specificity of the FNAC is very high for the diagnosis of SGs lesions. Due to high diagnostic accuracy, this technique is highly reliable in the detection of SGs lesions. Thus preoperative FNAC can be use as a quick primary diagnostic technique for SGs lesions with lack of complications to the patient. Ultrasound guided FNAC will be more representative. This study highlights the diagnostic value of FNAC in distinguishing benign from malignant SGs lesions and thus, helped surgeon to save his time for preoperative management. The decision for surgical approach was planned according to the cytodagnosis and unnecessary surgery could be avoided. Thus, FNAC is a good supplementary, not a substitute to conventional histopathological methods.

References

1. Rosai J. Rosai and Akerman's surgical pathology. 10th ed. Reed Elsevier India Private Limited; 2011:817-840.
2. Lingen MW. Head and Neck. In: Kumar V, Abbas AK, Aster JC, eds. Robbins & Cotran Pathologic Basis of Disease. 9th ed. Reed Elsevier India Private Limited; 2015:727-748.
3. Eveson JW, Cawson RA. Salivary gland tumours: a review of 2410 cases with particular reference to histological types, site, age and sex distribution. J Pathol. 1985; 146(1):51-8. doi:10.1002/path.1711460106.
4. Schindler S, Nayar R, Dutra J, et al. Diagnostic challenges in aspiration cytology of the salivary glands. Semin Diagn Pathol. 2001;18:124-146.

5. Tessy PJ, Jayalekshmy PS, Cicy PJ, et al. Fine needle aspiration cytology of salivary gland lesions with histopathological correlation - A two year study. *International J. of Healthcare and Biomedical Research*. 2015;3(4):91-99.
6. Cajulis RS, Gokaslan ST, Yu GH, et al. Fine needle aspiration biopsy of the salivary glands. A five-year experience with emphasis on diagnostic pitfalls. *Acta cytologica*. 1996 Dec;41(5):1412-20.
7. Wong DS, Li GK. The role of fine needle aspiration cytology in the management of parotid tumors: a critical clinical appraisal *Head Neck*. 2000;22:469-473.
8. Kamal MM, Dani AA, Kotwal MN, et al. Aspiration cytology of salivary gland lesions advantages and pitfalls. *Indian J Pathol Microbiol*. 1994;37:281-87.
9. Stewart CJ, MacKenzie K, McGarry GW, et al. Fine-needle aspiration cytology of the salivary gland: a review of 341 cases. *Diagn Cytopathol*. 2000;22:139-146.
10. Zakowski MF. Fine needle aspiration cytology of tumors: Diagnostic accuracy and potential pitfalls. *Cancer Invest*. 1994;12:505-515.
11. Elhosseiny A. Salivary glands. In: Koss LG, Melamed MR, eds. *Koss Diagnostic Cytology and its Histopathological basis*. 5th ed. Lippincott Williams & Wilkins; 2006:1229-1261.
12. Gandhi SH, Purohit TM, Purohit MB, et al. FNAC Diagnosis of Salivary Gland Lesions with Histopathological Correlation. *National Journal of Integrated Research in Medicine*. 2013;4(3):70-7.
13. Nanda S, Deep K, Mehta A, et al. Fine-needle aspiration cytology: a reliable tool in the diagnosis of salivary gland lesions. *Journal of Oral Pathology & Medicine*. 2012 Jan 1;41(1):106-12.
14. Kalburge JV, Kalburge V, Latti B, et al. Salivary Gland Tumors: Clinicopathologic analysis of 73 cases. *Journal of Cranio-Maxillary Diseases*. 2014 Jul 1;3(2):111-15.
15. Ersöz C, Uguz AH, Tuncer Ü, Soyulu L, Kiroglu M. Fine needle aspiration cytology of the salivary glands: a twelve years' experience. *Aegean Pathol J*. 2004;1:51-6.
16. Ahrnad S, Lateef M, Ahmad R. Clinicopathological study of primary salivary-gland tumors in Kashmir. *JK-practitioner*. 2002;9(4):231-33.
17. Laishram RS, Kumar KA, Pukhrabam GD, et al. Pattern of salivary gland tumors in Manipur, India: A 10 year study. *South Asian journal of cancer*. 2013 Oct;2(4):250-3.
18. Akhter J, Hirachand S, Lakhey M. Role of FNAC in the diagnosis of salivary gland swellings. *Kathmandu University medical journal (KUMJ)*. 2007 Dec;6(2):204-8.
19. Khandekar MM, Kavatkar AN, Patankar SA, et al. FNAC of salivary gland lesions with histopathological correlation. *Indian Journal of Otolaryngology and Head and Neck Surgery*. 2006 Jul 1;58(3):246-48.
20. O'Dwyer P, Farrar WB, James AG, et al. Needle aspiration biopsy of major salivary gland tumors: its value. *Cancer*. 1986 Feb 1;57(3):554-7.
21. Koivuniemi A, Saksela E, Holopainen E. Cytological aspiration biopsy in otorhinolaryngological practice. A preliminary report with special reference to method. *Acta oto-laryngologica. Supplementum*. 1968 Dec;263:189-92.
22. Ashraf A, Shaikh AS, Kamal F, et al. Diagnostic reliability of FNAC for salivary gland swellings: A comparative study. *Diagnostic cytopathology*. 2010 Jul 1;38(7):499-504.
23. Daneshbod Y, Daneshbod K, Khademi B. Diagnostic Difficulties in the Interpretation of Fine Needle Aspirate Samples in Salivary Lesions. *Acta cytologica*. 2009 Jul 1;53(1):53-70.
24. Vaidya S, Sinha A, Narayan S, et al. A comparative study of fine-needle aspiration cytology and histopathology in salivary gland lesions. *Journal of Pathology of Nepal*. 2011;1(2):108-13.
25. Stow N, Veivers D, Poole A. Fine-needle aspiration cytology in the management of salivary gland tumors: an Australian experience. *Ear, Nose and Throat Journal*. 2004 Feb 1;83(2):128-32.
26. Cristallini EG, Ascani S, Farabi R, et al. Fine needle aspiration biopsy of salivary gland, 1985-1995. *Acta cytologica*. 1997;41(5):1421-5.
27. Young JE, Archibald SD, Shier KJ. Needle aspiration cytologic biopsy in head and neck masses. *The American Journal of Surgery*. 1981 Oct 31;142(4):484-89.
28. Faizal B, Bhate JJ, Hiran KR. Reliability of Fine Needle Aspiration Cytology in salivary neoplasms: surgeon's perspective. *Amrita Journal of Medicine*. 2014;10(2):23-29.