

Prospective study of characteristic of patients with Oral squamous cell carcinomas

Nitika Kesawani^{1,*}, Meena Harsh², Neena Chauhan³

¹Senior Resident, Banaras Hindu University, Varanasi, Uttar Pradesh, ²Professor & HOD, ³Professor, Dept. of Pathology, Swami Rama Himalayan University, Dehradun, Uttarakhand

***Corresponding Author:**

Email: mail.dr.nitika@gmail.com

Abstract

Background: Oral squamous cell carcinomas (SCC) still a significant health burden in developed and developing countries.

Aims and Objectives: To study the premalignant and malignant lesions of oral cavity, to classify malignant lesions according to histomorphology and to study the expression of epidermal growth factor receptor (EGFR) in lesions.

Materials and Methods: Fifty cases of SCC diagnosed by histopathology of oral cavity were studied in the Department of Pathology, Himalayan Institute of Medical Sciences, Dehradun over a period of 12 months. Semi-quantitative evaluation of EGFR expression was done. All scores were based on examining the whole section in each biopsy under a multi headed microscope by three observers.

Results: Out of 50 patients, 28% were in the age group of 51-60 years, there was an obvious male preponderance (92%). Majority of patients were only tobacco smokers (44%). The commonest site of oral cancers was tongue (26%). Out of total 50 cases, 37 (74%) were malignant and 13 (26%) were premalignant lesion. In present study, 48.64% of malignant and 84.61% premalignant lesion patients showed 3+ positivity of EGFR expression.

Conclusion: Oral SCC was most common in male elderly patients, tongue was the most common site and moderately differentiated SCC was most common. Expression of EGFR was increased in both premalignant and malignant lesions. EGFR expression was over expressed in premalignant lesions and decreased in normal mucosa so premalignant lesions can be segregated as they are likely to progress to invasive cancer.

Keywords: Squamous cell carcinoma, Epidermal growth factor receptor, Oral cancer, EGFR expression

Introduction

Reports have shown that about 90% of the total malignancies affecting oral cavity are squamous cell carcinoma (SCC) type which originate in the mucosa lining (the squamous epithelium). Oral (buccal) cancer is the 6th most common cancer reported and accounts for around 5.5% of total malignancies, more common than uterine cervical cancer.⁽¹⁾

The incidence is higher in developed countries compared to developing countries.⁽¹⁾ In India prevalence of oral cancer is reported to be highest in all malignancies of men.⁽²⁾

Regulatory agent such as epidermal growth factor receptor (EGFR) determines the cell viability and proliferation. In normal condition EGFR act in a hormone-like receptor-dependent fashion. In oral SCC and premalignant lesions expression of EGFR is increased.⁽³⁾ It has been also hypothesized that malignant lesions which have high levels of EGFR expression, leads to frank malignancies.⁽⁴⁾ Hence finding the level of EGFR expression in suspicious lesions would possibly give an idea that which lesions can become malignant. It will help in planning the adequate treatment plan.

The present study was performed to study premalignant and malignant lesions of oral cavity, to classify malignant lesions according to histomorphology and to study the expression of EGFR in lesions.

Materials and Methods

The present cross sectional study was done on 50 cases of squamous cell carcinoma (SCC) diagnosed by histopathology of oral cavity in Department of Pathology, Himalayan Institute of Medical Sciences, Dehradun over a period of 12 months.

All the relevant clinical details of history, physical examination and investigations were recorded. A Histopathology number was allotted to each specimen and grossing was done according to standard procedure.

Biopsies were processed in automatic tissue processor followed by immunohistochemistry staining for EGFR. Semiquantitative evaluation of EGFR expression was done. Each slide was scored for membranous expression as 0 (no membrane staining <10% of epithelial cells), 1 (weak membrane staining >10%), 2 (intermediate membrane staining >10%) and 3 (intense membrane staining >10%). No or weak EGFR expression in normal oral mucosa was taken as control. Scoring was classified as 0 to 1 (was taken as low EGFR expression and 2 to 3 (was taken as high EGFR expression).

All scores were based on examining the whole section in each biopsy under a multi headed microscope by three observers, who were blinded to clinical patient information.

Data analysis was done using SPSS software (Statistical Package For Social Services) version 22. The results were analysed using tables and percentage

proportion analysis was done by chi-square and p value, p<0.05 was taken as significant.

Results

Table 1: Distribution of patient’s characteristic of study population

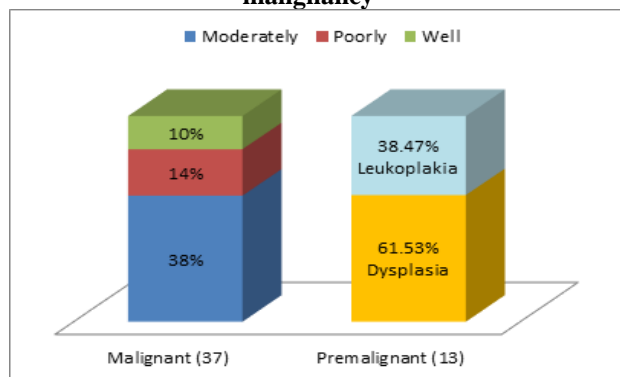
Parameters		N (%)
Age	21 – 30	3 (6)
	31 – 40	8 (16)
	41 – 50	12 (24)
	51 – 60	14 (28)
	61 – 70	11 (22)
	> 70	2 (4)
Gender	Male	46 (92)
	Female	4 (8)
Addiction	Only Tobacco	22 (44)
	Only Gutkha	2 (4)
	Tobacco + Gutkha	20 (40)
	No Addiction	6 (12)
Site of lesions	Tongue	13 (26)
	Buccal mucosa	11 (22)
	Pharynx	6 (12)
	Glottis	5 (10)
	Tonsil	5 (10)
	Lip	2 (4)
	Alveolus	6 (12)
	Palate	2 (4)

The maximum number of patients were in the age group of 51-60 years (n=14, 28%), followed by 41-50 years (n=12, 24%). There was an obvious male preponderance, accounting for 92% (n=46) of the cases in the study group.

Majority of patients were only tobacco smokers (n=22, 44%), followed by tobacco smokers and gutkha chewers (n=20, 40%). Only gutkha chewers were 2 (04%) and patients with no addiction were 6 (12%).

The commonest site of oral cancers was tongue accounting for 13 cases (26%). This was followed by buccal mucosa (11 cases, 22%).

Graph 1: Distribution of patients according to malignancy



Histomorphological spectrum of cases showed that out of 46 males, 17(36.95%) have moderately differentiated SCC and out of 4 females, 2(50%) have moderately differentiated SCC.

Out of 8 patients of leukoplakia, 4 (50%) were only tobacco smokers and 3 (37.5%) had tobacco and gutkha together whereas in patients with dysplasia 3 (75%) out 4 patients had tobacco and gutkha and 1 (25%) was only gutkha chewer. Out of 37 malignant cases, only tobacco smokers were 18 (48.64%), out of which 2 (11.11%) had well differentiated SCC, 11 (61.11%) had moderately differentiated SCC and 5 (27.77%) cases showed poorly differentiated SCC. In the group of tobacco smokers and gutkha chewers, 3 (15%) had well differentiated SCC, 8 (40%) had moderately differentiated SCC and 2 (10%) patients had poorly differentiated SCC.

Total of 37 malignant cases, majority (n=18, 48.64%) showed 3+ positivity followed by 2+ positivity (n=13, 35.13%) of EGFR expression. Out of 13 premalignant lesions, maximum cases showed 3+ positivity (11 cases, 84.61%) of EGFR expression (p>0.05).

Table 2: Tumor grade and EGFR expression

Tumor Grades	LE	HE
Grade 0	1 (14.28)	12 (27.90)
Grade 1	1 (14.28)	5 (11.62)
Grade 2	3 (42.85)	17(39.53)
Grade 3	2 (28.56)	5 (11.62)
Others	0 (0)	4 (9.30)
Total	7 (100)	43 (100)

Data is expressed as no of patients (%), LE; low expression (0 –1), HE; high expression (2 – 3)

Table 3: EGFR expression in different malignant/ premalignant lesions

Histological subtype	Total N=50	EGFR Expression		
		1+	2+	3+
Malignant (n=37)				
Well differentiated SCC	5 (13.51)	1	3	1
Moderately differentiated SCC	19 (51.35)	3	5	11
Poorly differentiated SCC	7 (18.91)	2	2	3
Basaloid SCC	3 (8.10)	0	1	2
Papillary variant of SCC	1 (2.70)	0	1	0
Verrucous SCC	1 (2.70)	0	0	1
Microinvasive SCC	1 (2.70)	0	1	0
Premalignant (n=13)				
Dysplasia	5 (38.46)	0	1	4
Leukoplakia	8 (61.53)	1	0	7

Data is expressed as no of patients (%), SSC; squamous cell carcinomas

Discussion

Oral carcinomas develop through multistep processes. At the beginning, reactive hyperkeratosis and

hyperplasia develops due to long exposure to various physical or chemical irritants or viral oncogenes. This leads to development of epithelial dysplasia, intraepithelial carcinoma, and invasive carcinomas. In proliferative and differentiated cells expression of EGFR is increased which may be due to paracrine effect which increases the expression of receptors on cell surface.⁽³⁾

Oral SCC is the disease which mainly affects elderly and commonly seen in patients between 50 and 70 years of age.⁽⁵⁾ In present study, SCC was most common and seen in patients having age more than 50 years. Males were mostly affected in present study (96%). A study done by Ribeiro et al on 48 patients had also reported male predominance and mean age of study population was 53 years which is similar to the present study.⁽⁶⁾ Khan et al performed a study in Pakistan on 46 oral SCC patients and reported a male predominance.⁽⁷⁾

Ribeiro et al also reported 62.5% patients with oral carcinoma were smokers which are almost similar to the present study findings which revealed that SCC was most commonly present in patients who were tobacco smokers (44%) followed by combined exposure of tobacco smoke and gutkha chewing (40%).⁽⁶⁾

In present study, tongue was the most common site of oral cancer followed by buccal mucosa.

But Rajeswari et al studied expression of EGFR in oral epithelial dysplastic lesions of 29 patients and reported buccal mucosa (72.41%) as the most commonly affected.⁽³⁾ Another study done by Khan et al reported mandibular alveolar ridge as the common site for oral SCC.⁽⁷⁾

In present study, majority of the patients had malignant lesion (74%) among which moderately differentiated SCC (38%) was most common. Almost similar results were reported by Khan et al.⁽⁷⁾ Leukoplakia was seen in 61.53% of the patients in which premalignant lesion was observed.

Histopathologically oral SCC can be differentiated as well, moderately and poorly differentiated tumour. In present study, histomorphological spectrum of patients revealed that moderately differentiated SCC was observed in 36.95% and 50% of the males and females respectively.

Among malignant cases, 48.64% were only tobacco smokers; most of them had moderately differentiated SCC. Leukoplakia was mostly found in patients who were only tobacco smokers whereas 75% of the patients of dysplasia were consuming tobacco and gutkha.

EGFR is a tyrosine kinase receptor which influences the biology of both normal and malignant-transformed cells but researches have proved that over expression of EGFR are strongly associated with various malignancies including oral SCC.⁽⁸⁾

Also different reports by many authors believed that expression of EGFR is a marker of proliferative

capacity of cell and it also describe the cell maturation.^(3,9,10)

In present study, most of the malignant patients showed 3+ positivity followed by 2+ positivity of EGFR expression whereas in patients with premalignant lesions, majority showed 3+ positivity of EGFR expression. Studies have shown that patients smoking history is significantly associated with EGFR expression and in lung squamous cell carcinoma, it is upregulated significantly.⁽¹¹⁾

Most of the patients in our study showed high EGFR expression. Among patients with Grade 2 SCC, majority showed high EGFR expression whereas among Grade 0 category almost all the patients showed high EGFR expression. Ribeiro et al also reported high EGFR expression in their study population.⁽⁶⁾

The present study had few limitation like low sample size, a large randomized clinical trial is required to confirm the findings.

Conclusion

The present study has found that oral SCC mostly affected male population of old age and tongue being the most commonly affected site. Histopathological analysis revealed that moderately differentiated SCC was most common.

References

1. Watanabe N, Ohkubo T, Shimizu M and Tanaka T. Preneoplasia and carcinogenesis of the oral cavity. *Oncol Discov* 2015;3:1.
2. George A, Sreenivasan BS, Sunil S, Varghese SS, Thomas J, Gopakumar D et al. Potentially Malignant Disorders of Oral Cavity. *Oral & Maxillofacial Pathology Journal* 2011;2(1):95- 100.
3. Rajeswari MC, Saraswathi TR. Expression of epithelial growth factor receptor in oral epithelial dysplastic lesions. *J Oral Maxillofac Pathol* 2012;16:183-8.
4. Cotran R, Vinaykumar A, Robbins SL. Robbins Pathologic Basis of diseases. 4th ed. Philadelphia: W.B. Saunders Company; 1989. p. 820.
5. Bhurgri Y. Karachi cancer registry data-implications for the national cancer control program of Pakistan. *Asian Pac J Cancer Prev* 2004;5:77-82.
6. Ribeiro DC, Gleber-Netto FO, Sousa SF, Bernardes VF, Guimarães-Abreu MHN, Aguiar MCF. Immunohistochemical expression of EGFR in oral leukoplakia: Association with clinicopathological features and cellular proliferation. *Med Oral Patol Oral Cir Bucal*. 2012 Sep 1;17(5):e739-44.
7. Khan A, Khan S, Khitab U. Emerging Clinical and Histopathological Spectrum of Oral Squamous Cell Carcinoma. *JKCD* 2015;5(2):12-5.
8. Ribeiro FAP, Noguti J, Oshima CTF, Ribeiro DA. Effective Targeting of the Epidermal Growth Factor Receptor (EGFR) for Treating Oral Cancer: A Promising Approach. *Anticancer Research* 2014;34:1547-1552.
9. Ohi K, Suzuki M, Koike S, Satake J, Matsu-Ura K, Takasaka T. Expression of epidermal growth factor receptor in squamous cell carcinoma of head and neck. *Nihon Jibiinkoka Gakkai Kaiho* 1993;96:2039-43.
10. Favia G, Corsalini M, Iacobellis M, Matorano E. Squamous cell carcinoma in Lichen ruber planus. A.

Clinicopathological, immunohistochemical study of 11 cases. *Minerva Stomatol* 1994;43:479-91.

11. Kan JU, Koo SH, Kwon KC, Park JW, Jung SS. Gain of the EGFR gene located on 7p12 is a frequent and early event in squamous cell carcinoma of the lung. *Cancer Genet Cytogenet* 2008;184:31-7.