

OTFS - A pathological menace leading to double trouble in women

Trupti Vyasrao Katti^{1,*}, Anand Ananthrao Shankar², Tejeshwini Patil³

¹Associate Professor, ²Professor, ³Assistant Professor,
Department of Pathology, Navodaya Medical College, Hospital & Research Centre, Raichur, Karnataka

***Corresponding Author:**

Email: drtrupti1305@gmail.com

Abstract

Background: OTFS are a heterogenous group of tumors with varying stromal activity and produce hormones such as estrogen, androgen or progesterone. These tumors are of due importance as they have widespread clinical, biochemical or pathological effects on various tissues and organs and are commonly observed in female genital tract manifesting as hyperplasias or carcinomas. It is thus important to study OTFS and analyse the associated changes in the endometrium.

Objectives: The aims of present study are: 1. Age distribution and clinical features of OTFS. 2. Histopathological spectra of OTFS. 3. Study of functional status of these tumors and associated endo-myometrial changes.

Methods: Present study of 2 years (2014-2015) analysed 48 cases of OTFS and their corresponding endo-myometrial changes in hysterectomised patients, at department of pathology, Navodaya Medical College, Raichur, Karnataka. Specimens were examined, processed and stained using Hematoxylin and Eosin.

Results: Majority of cases were in reproductive age group (83.3%) compared to postmenopausal (16.7%) category. Most were asymptomatic and few (12%) were symptomatic with menorrhagia and postmenopausal bleeding. Histopathological categories included: surface epithelial tumors (44), dermoid cysts (2), metastatic EOPPC (1) and combined tumor (1). OTFS with active stroma (64.5%) was commonly observed among total cases and the associated endo-myometrial changes, most frequently observed was endometrial polyp (29%) followed by cystoglandular hyperplasia (25.8%), adenomatous polyp (19.4%), adenomatous hyperplasia (16.1%), adenomyosis (8.7%) and leiomyoma (6.5%).

Conclusion: As OTFS with active stroma can have ill effects on endo-myometrium, an appropriate screening of the cases clinically and histopathologically would reduce morbidity and mortality, thus helping in better patient outcome.

Keywords: Ovarian tumors with functioning stroma, Endocrine manifestations, Active stroma, Endo-myometrial changes.

Introduction

Ovarian tumors are seventh most common cancer and represent approximately 4% of cancers diagnosed in women.⁽¹⁾ According to statistics (2012), these cancers accounted to 58% in developing countries.⁽²⁾ Among ovarian neoplasms, hormonally functional tumors are those which produce steroid hormones such as estrogens, androgens and progesterone and frequently belong to sex cord stromal and steroid cell categories.⁽³⁾ The stroma of some ovarian tumors may exhibit steroid hormone secretion and may be associated with clinical, biochemical or pathologic evidence of endocrine function. Morris and Scully designated these tumors as "Ovarian tumors with functioning stroma (OTFS)"⁽⁴⁾ and can be either primary -benign or malignant; or metastatic. The stroma of metastatic tumors of ovary commonly produce androgens, while that of mucinous cystadenoma produces estrogens.⁽⁵⁾ The stroma of these tumors are of two types - luteinised or condensed.⁽⁴⁾

OTFS are very important tumors as they induce hormonal effects on endometrium and may lead to pre neoplastic endometrial hyperplasias or endometrial carcinomas. Hence, an early diagnosis of OTFS can arrest the influence of the hormones and help in checking the morbidity and mortality of the patients, thus favouring better clinical outcome.

Aims

1. Age distribution and clinical features of patients diagnosed as having OTFS.
2. To analyse the histopathological spectra of OTFS.
3. Study of functional status of these tumors and associated endo-myometrial changes.

Materials and Methods

This prospective study of two years (Jan 2014-Dec 2015) comprised of 48 patients presenting with ovarian tumors who underwent hysterectomy with bilateral salpingo-oophorectomy. Specimens were routinely processed and stained using Hematoxylin and Eosin. Histopathologically, stroma of the ovarian tumors which had condensation and /or luteinisation, was defined as active. The condensed stromal cells appeared closely apposed and packed, while the luteinised cells were seen as uniform, small and polygonal with abundant eosinophilic cytoplasm and round nucleus with prominent nucleolus.

Inclusion criteria: Study included patients who had OTFS and underwent hysterectomy with bilateral salpingo-oophorectomy.

Exclusion criteria: Patients with OTFS with following features were excluded:

1. Associated non neoplastic ovarian lesions which produce hormones like stromal hyperplasia/hyperthecosis and follicular cysts.
2. Pregnancy
3. Patients on hormonal therapy and those with pituitary or adrenal abnormalities.

Results

This study comprised of a total number of 53 cases of ovarian tumors, among which 15 cases were excluded, as they belonged to one of the following categories:

1. Presence of associated non neoplastic ovarian lesions which produce hormones like stromal hyperplasia / hyperthecosis and follicular cysts - 6 cases.
2. Pregnant women presenting with ovarian tumor- 3 cases.
3. Patients on hormonal therapy- 4 cases and with endocrine problems such as pituitary and adrenal abnormalities- 2 cases (1 each).

Among 48 cases of OTFS, patients' ages ranged from 24-77 years. Forty cases (83.3%) were in reproductive age group and ranged from 24 to 47 years, while 8 (16.7%) were in post-menopausal category i.e. 58 to 77 years.

Clinically, menorrhagia (5 cases; 10.4%) and postmenopausal bleeding (1 case; 2.1%) were common endocrine manifestations (6 cases; 12.5%) and the rest were asymptomatic.

Ovarian tumors with functioning stroma in decreasing order of frequency were; mucinous tumors (28 cases; 58.3%), serous tumors (16 cases; 33.3%), dermoid cysts (2 cases; 4.2%), combined tumor (mature cystic teratoma with struma ovarii- 1 case; 2.1%) and metastatic extra ovarian primary peritoneal carcinoma (EOPPC-1 case; 2.1%).

Among mucinous tumors, benign (19 cases; 67.8%) were more common which included 18 cases of cystadenoma and 1 case of adenofibroma, followed by malignant (6 cases; 21.4%) and borderline (3 cases; 10.8%) and even in serous tumors, benign (10 cases; 62.5%) were commonest which comprised of 8 cases of cystadenoma and 2 cases of adenofibroma, followed by malignant (4 cases; 25%) and borderline (2 cases; 12.5%).

Tumors which belonged to OTFS showing features of active stroma were dermoid cysts (2 cases; 100%), mucinous tumors (21 cases; 75%) and serous tumors (8 cases; 50%), whereas the others exhibited inactive stroma.

Histopathologically, cases of OTFS having active stroma constituted 31 cases (64.5%) in which condensation was observed in 9 cases (29.1%) and luteinisation in 22 cases (70.9%).

The spectrum of endo-myometrial changes associated with OTFS in present study is illustrated in Table 1.

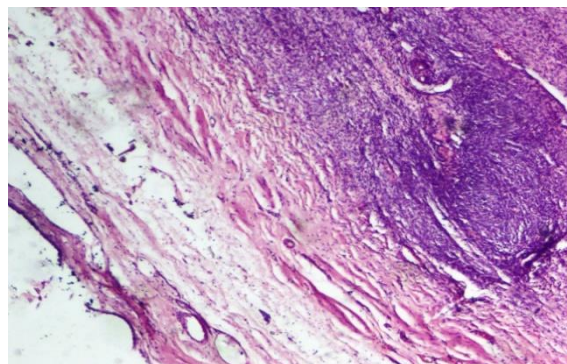


Fig. 1: Photomicrograph of serous cystadenoma- Cuboidal lining epithelium with condensed stroma (H & E, 100x)

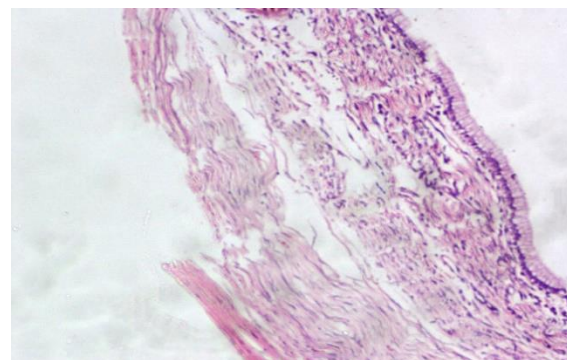


Fig. 2: Photomicrograph of mucinous cystadenoma- Columnar lining epithelium with mucous vacuoles (H & E, 100x)

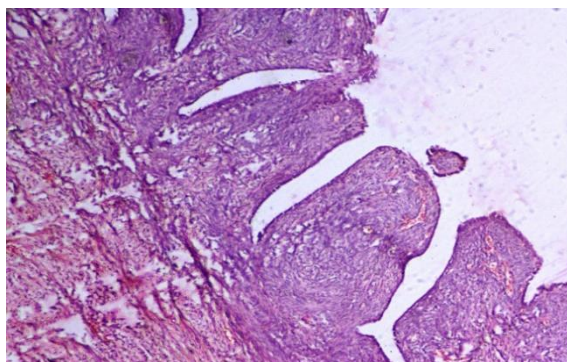


Fig. 3: Photomicrograph of serous cystadenofibroma (H & E, 40x)

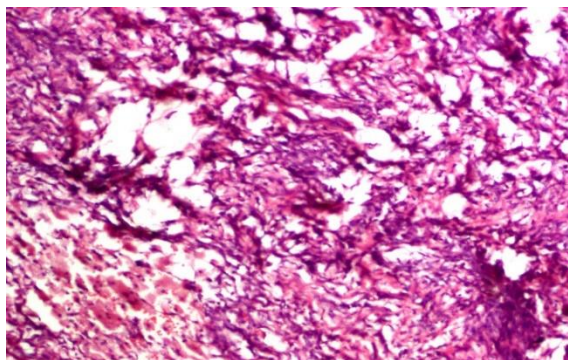


Fig. 4: Photomicrograph of luteinised cells (H & E, 200x)

Table 1: (a) OTFS with associated Endo-myometrial changes

OTFS	Proliferative	Secretory	Inflammatory Infiltrate	Cystoglandular hyperplasia	Adenomatous Hyperplasia
I. Serous					
i.Benign	-	-	-	3	-
ii.Borderline		-	-	1	-
iii.Malignant	2	-	-	-	1
II. Mucinous					
i.Benign	1	2	-	3	1
ii.Borderline	1	-	1	1	1
iii.Malignant	1		1		1
III. Dermoid cyst	-	-	-	-	-
IV. Combined	1	-	-	-	-
V. Metastasis	1	-	-	-	-

Table 1: (b) OTFS with associated Endo-myometrial changes

OTFS	Adenomyosis	Endometrial polyp	Adenomyomatous polyp	Atrophic + adenomyosis	Atrophic + intramural fibroid
I. Serous					
i.Benign	-	2	2	1	2
ii.Borderline	-	1	-	-	-
iii.Malignant	-	1	-	-	-
II. Mucinous					
i.Benign	8	-	-	2	-
ii.Borderline	1	-	-	-	-
iii.Malignant	-	1	2	-	-
III. Dermoid cyst	-	-	2	-	-
IV. Combined	-	-	-	-	-
V. Metastasis	-	-	-	-	-

Table 2: Comparative study of functional status of OTFS

Ovarian tumors	Active stroma		Inactive stroma	
	Xavier et al ⁽⁴⁾	Present study	Xavier et al ⁽⁴⁾	Present study
I.Serous				
Serous cystadenoma	-	100%	-	0%
Serous cystadenofibroma	-	100%	-	0%
Borderline serous cystadenoma	50%	100%	50%	0%
Serous carcinoma	13.3%	50%	86.7%	50%
Total	21%	50%	79%	50%
II.Mucinous				
Mucinous cystadenoma	46.6%	73.6%	53.4%	15.8%
Borderline mucinous cystadenoma	100%	100%	0%	0%
Mucinous carcinoma	-	66.7%	-	33.3%
Total	55.5%	75%	45.5%	25%
III. Dermoid cyst	0%	100%	100%	0%
IV. Combined tumor				
Mucinous cystadenoma + Dermoid cyst	100%	-	0%	100%
V. Metastasis				
i) EO PPC	-	0%	-	100%
ii) Gastric and colonic	42.8%	-	57.2%	-

Table 3: Endo-myometrial changes associated with surface epithelial carcinomas-comparison study

Endometrial changes	Serous		Mucinous	
	Marjanka et al ⁽¹⁹⁾	Present study	Marjanka et al ⁽¹⁹⁾	Present study
1.Normal	54	50	87	33.6
2.Hyperplasia	15	25	6	16.4
3.Atypical hyperplasia	24	-	6	-
4.Polyps	-	25	-	50
5.Endometrial carcinoma	7	-	1	-
Total activity (% of cases)	46%	50%	13%	66.4%

Discussion

The stromal cells of ovarian tumors have attracted the attention of gynecologic pathologists, as they interact with cancer and pre-cancerous cells, subsequently producing steroid hormones leading to estrogenic, androgenic or progestational manifestations. Laboratory studies have shown that surface epithelial tumors, especially mucinous cystadenomas have an estrogenic stroma, whereas one-third of metastatic ovarian tumors mostly of gastric origin together with primary teratomas, and carcinoids have an androgenic stroma. However, any

type of ovarian tumor other than the well-known hormone-producing ones, could have hormonal activity within its stroma.^(5,6)

According to pathogenetic point of view, OTFS belong to one of the following three categories:

- a. tumors that contain syncytiotrophoblastic cells
- b. tumors that occur during pregnancy
- c. tumors that occur in non-pregnant women and lack syncytiotrophoblastic cells (idiopathic group).⁽⁴⁾

Rutgers et al documented that activated stromal cells of OTFS can be of many types and in varying proportions in different tumors, such as i) lutein cells (estrogenic) - commonly observed in monodermal teratomas, dermoid cysts, dysgerminomas containing syncytiotrophoblastic cells and metastatic carcinoid. ii) leydig cells (mostly androgenic) - seen in struma ovarii and strumal carcinoid and iii) hilus cells (androgenic)-noted in mucinous cystadenomas, cysts of rete origin and dermoid cysts.⁽⁷⁾

The present study predominantly comprised cases of reproductive (83.3%) and few of postmenopausal age group (16.6%). Similar observation was noted in a study by Shalinee et al.⁽⁸⁾ Ovarian tumors associated with overt clinical evidence of functioning stroma are rare. Most epithelial tumors are non-functioning presenting with vague symptoms.⁽⁹⁾ However, it is possible that many tumors secrete small quantities of steroid hormones and produce subclinical as well as local pathologic manifestations.⁽¹⁰⁾ In accordance with this, most of the patients in the present study were asymptomatic and few (12%) presented with endocrine manifestations like menorrhagia and postmenopausal bleeding, which was consistent with the studies conducted by Shalinee et al⁽⁸⁾, Xavier et al⁽⁴⁾ and Robert et al⁽¹⁵⁾.

The comparison of histopathological spectrum and percentage of OTFS showing active and inactive stroma of the present study and a similar study by Xavier et al⁽⁴⁾ is displayed in Table 2.

Cases of OTFS with active stroma (39 cases) in the present study comprised of surface epithelial tumors and dermoid cysts, both of which had estrogenic stroma. Whereas the study conducted by Yumito et al documented 2 cases of OTFS with active stroma, where one was an ovarian carcinoid with testosterone-producing stroma and the other was ovarian mucinous cystadenoma with estrogenic stroma.⁽¹¹⁾

All cases of benign serous and mucinous tumors, borderline mucinous tumors and dermoid cysts in this study had active stroma, whereas others showed variable activity. While Xavier et al⁽⁴⁾ observed active stroma in all cases of borderline mucinous cystadenoma and combined tumour (mucinous cystadenoma + dermoid cyst).

The active stroma was documented in 50% of serous and 75% of mucinous tumors in this study, while it was 21% and 55% by Xavier et al⁽⁴⁾ in a similar study, respectively. (Refer Table 3)

Almost every type of ovarian tumor has been reported to show activation of its stroma. Xavier et al⁽⁴⁾ found that it is more commonly encountered in mucinous, endometrioid, clear cell and metastatic tumours.⁽⁴⁾

Histopathologically, OTFS with active stroma showing stromal luteinisation (22 cases; 70.9%) was more common when compared to those with condensation (9 cases; 29.1%). Similar findings were observed by Xavier et al⁽⁴⁾, who documented OTFS showing active stroma in the form of luteinisation in 21 cases (63.6%) and condensation in 12 cases (36.4%).⁽⁴⁾

According to Tokunaga *et al.*, the neoplastic cells of epithelial ovarian tumors produce estradiol by interaction between tumour cells and stromal cells, leading to estrogen production. Noguchi *et al* and Kitawaki *et al.* demonstrated that intratumoral aromatase activity and an increased expression of 17 beta hydroxysteroid dehydrogenase(HSD) type I has a significant role.^(10,13)

Ovarian stromal luteinisation or enzymatically active stromal cells (EASCs) are frequently seen in stroma adjacent to ovarian tumors- either of primary (benign, malignant) or metastatic origin.

Transformation of stromal cells is due to:

1. Substances produced by the tumor cells like aromatase, steroid receptors and steroidogenic factor-1. The aromatase is synthesized by intratumoral and extratumoral leutinised stromal cells, which convert androgens to estrogens with the help of 17b-HSD type 1 and estrogen sulfatase.
2. Pressure of the tumor on adjacent stroma.
3. The presence of enzyme 3 beta-HSD activity localized in the stroma, indicates that estradiol synthesis is mainly carried out in stromal cells rather than in epithelial cells.^(5,14)

Hence, hyperestrogenic manifestations are more commonly reported in ovarian epithelial tumors (mostly mucinous), even though androgens are produced in the functioning stroma.^(10,15) Similar results were obtained in present study.

It is found that in mucinous neoplasms, there are increased number of HCG immunoreactive cells when compared to serous, endometrioid and clear cell tumors.^(5,10) This explains the higher percentage of mucinous tumors with active stroma than the serous category in present study, which was in accordance to other studies.(Refer Table 2)

The influence of oestrogenic activity in the stroma of ovarian tumors can be established by its effect on other organs like endometrium, vaginal mucosa etc.^(5,10) The effect on endometrium depends on the amount and duration of exposure to hormone:

1. Estrogenic: simple/ complex hyperplasia, cystoglandular hyperplasia, adenomatous hyperplasia/ adenocarcinoma (if prolonged exposure).

2. Progesterational: secretory hypertrophy, decidual stroma.

3. Androgenic: hypoplastic, atrophic.^(4,17)

OTFS inducing endometrial changes in the present study were predominantly surface epithelial tumours (29 cases: Mucinous-21 & Serous-8), followed by dermoid cysts (2 cases). The associated endometrial changes noted were endometrial hyperplasias, polyps and fibroids. (Refer Table 1) This was in accordance to the study of Shalineet al⁽⁸⁾, who reported that surface epithelial tumors (9 cases) and germ cell tumour (mature cystic teratoma) (1 case) induced endometrial changes such as hyperplasias or endometrial carcinomas. Adenomyosis was documented in 15 cases of mucinous cystadenomas and 2 cases of serous cystadenomas. These findings corroborated with the similar study by Seema Dayal et al, who reported in 20 cases of serous cystadenomas.⁽¹⁸⁾

Among malignant tumors encountered in present study, most of the cases of mucinous carcinoma (66.4%) revealed associated endometrial changes than the serous carcinoma (50%). On the contrary, Markanja et al⁽¹⁹⁾ documented predominantly in serous (46%) when compared to mucinous carcinoma (13%) (Refer Table 2).

(Refer Table 3) The fact that intra tumoral aromatase expression is more commonly observed in stromal cells of serous than mucinous carcinomas, substantiates these results.^(10,14) Another study by Smith *et al* (1975) confirmed that the unopposed estrogenic stimulation results in endometrial hyperplasia and may further progress to endometrial adenocarcinoma.⁽¹⁶⁾

After menopause ovaries cease to produce hormones, however a small amount of estrogen is synthesized naturally in fat tissue, which has a greater impact.⁽²⁰⁾

Risk of malignant transformation is more with complex atypical hyperplasia (29%) than simple atypical hyperplasia (8%). Increased karyopyknotic index (KPI) of vaginal smear and uterine bleeding are the important signs of asymptomatic ovarian tumors in postmenopausal women.⁽²⁰⁾ In postmenopausal group, the present study showed a solitary case (12.5%) presenting with bleeding per vaginum and histopathologically OTFS with active stroma was observed in all cases (100%), whereas Robert et al⁽¹⁵⁾ in his study documented the stromal activity in only one third of the cases (33%).

OTFS induced endo-myometrial spectra in postmenopausal age group frequently noted were proliferative phase (37.5%) and atrophic with adenomyosis (37.5%), followed by atrophic with intramural fibroid (25%). Suzuki et al⁽¹⁴⁾ documented majority of cases of atrophic changes (56.6%) followed by proliferative (21.7%), cystic hyperplasia (13.0%) and adenomatous hyperplasia (8.7%), while Robert et al⁽¹⁵⁾ reported equal cases of proliferative (50%) and hyperplastic changes(50%).

Conclusion

OTFS are uncommon and most of the cases were in reproductive age group. Majority were asymptomatic and were mainly of surface epithelial category on histopathological examination. Out of the total number of cases of OTFS, those with active stroma were more common. The active stroma was observed more commonly in mucinous than serous tumors and dermoid cysts, whereas inactive stroma was seen in combined tumor and metastatic EOPPC. All cases of OTFS with active stroma revealed estrogenic influence on endometriometrium.

Early identification of OTFS and their consequent varied endometrial pathologies is vital to prevent endometrial over stimulation and arrest neoplastic transformation. An attention should be given to the possibility of concurrent endometrial pathology, if conservative surgery is considered for preservation of the uterus.

Acknowledgements: Nil

Conflicts of Interest: Nil

References

- Internet journal. Available at https://en.m.wikipedia.org/wiki/ovarian_cancer.
- Ovarian cancer statistics/World Cancer Research Fund International. Available at <https://www.wcrf.org/int/data-specific-cancers>.
- Lawrence M. Roth, Steven D. Billings. Hormonally functional ovarian neoplasms. Review- Endocrine Pathology March 2000;11(1):1-17.
- Matias-Guiu X, Prat J. Ovarian tumors with functioning stroma. An immunohistochemical study of 100 cases with human chorionic gonadotropin monoclonal and polyclonal antibodies. Cancer 1990 May 1;65(9):2001-5.
- Yumiko O, Hajime Tsunoda, Yumiko Kikagawa, Teruko Ueno, Hiroyuki Yoshikawa and Yukihisa Saida. Functioning Ovarian Tumors: Direct and Indirect Findings at Magnetic Resonance Imaging. Radiographics October 2004;(24):147-166.
- Mitsuko Furuya. Review. Ovarian Cancer Stroma: Pathophysiology and the Role in Cancer Development. Cancer 2012;4:701-724.
- Rutgers, Joanne L, Scully, Robert E. Functioning Ovarian Tumors with Peripheral Steroid Cell Proliferation- A Report of Twenty-Four Cases. International Journal of Gynecological Pathology: December 1986.
- Shalinee Rao, Shivani Rao, Sharda Lal, Raghavan Narasimhan. Evaluation of Ovarian Lesions Inducing Endometrial Hyperplasia or Carcinoma in a Tertiary Care Hospital in Southern India. Journal of Basic and Clinical Reproductive Sciences; July-December 2013;2(2):123-26.
- I Tien Yeh, Charles Zaloudek, Robert J Kurman. Chapter 102 Functioning tumors and tumour like conditions of the Ovary. Part VII Endocrinology of the female genital tract. Principles and Practice of Endocrinology and Metabolism; 1009. <https://books.google.co.in/books>.
- Hironobu Sasano and Nobuhiro Harada. Intratumoral Aromatase in Human Breast, Endometrial and Ovarian Malignancies. Endocrine Reviews:19(5):593-607.
- Yumiko Oishi Tanaka, Yoshihiro Ide, Masato Nishida, Ken Nishide, Hajime Tsunoda, Motono Kajitani Ovarian tumor with functioning stroma; Computerized medical imaging and graphics; May-June, 2002;26(3):193-97.
- Robert M. Rome, Denys W Fortune, Michael A Quinn, James B Brown; Functioning ovarian tumours in Postmenopausal women; Obstetrics & Gynaecology June 1981;57(6):705-10.
- Tokunaga H, Akahira J, Suzuki T, Moriya T, Sasano H, Ito K, Yaegashi N. Ovarian epithelial carcinoma with estrogen-producing stroma. Pathol Int 2007 May;57(5):285-90.
- Suzuki M, Sekiguchi I, Tamada T. Estrogen production by epithelial ovarian tumors and dermoid cyst. Nihon Sanka Fujinka Gakkai Zasshi 1986 Mar;38(3):303-10.
- Robert H Young, Robert E Schully. Chapter 19 Sex cord stromal, Steroid cell and other ovarian tumours. Blaustens Pathology of the Female Genital tract: 643-50. ISSN: 1756-2228; DOI 10.3843/GLOWM.10249.
- www.brooksidepress.org: Military obstetrics and gynaecology: Adnexal Mass.
- Available at www.https://books.google.co.in/books.
- Seema Dayal, Arun Nagrath. Pattern and frequency of endometrial and ovarian pathologies with adenomyosis uteri in patients who attended the tertiary care hospital among rural population of north India. Journal of MAMC Medical Sciences 2015;1:147-50.
- Markanja J Mingles, Rina Masadah, Yvette P Geels et al. High prevalence of atypical hyperplasia in the endometrium of patients with epithelial ovarian cancer. American Journal of Clinical Pathology 2014;14(2):213-21.
- Yamagata S, Yamamoto K, Tsuchida S, Kawaura N, Matsumoto Y, Sugawa T. Estrogen production in epithelial tumors of the ovary- clinical and endocrinological study in postmenopausal women. Nihon Sanka Fuginca Gakkai Zasshi 1989 Nov;41(11):1761-68.