

# Usefulness of automated hematology analyzer Sysmex XN 1000 in detection of Malaria

Sunilkumar KB<sup>1,\*</sup>, Preeti Naik<sup>2</sup>

<sup>1</sup>Associate Professor, <sup>2</sup>PG Student, Dept. of Pathology, JJM Medical College, Davangere, Karnataka

**\*Corresponding Author:**

Email: drsunilkb@gmail.com

## Abstract

**Objective:** Malaria is a common parasitic disease present worldwide, especially tropical countries. It is challenging for most laboratories to provide a rapid and accurate diagnosis of malaria by light microscopy when the workload is high. The present study was undertaken to assess the usefulness of automated hematology analyzer Sysmex XN 1000 in the detection of malaria.

**Methodology:** Sysmex XN 1000, a 6 part differential automated hematology analyzer was used to analyze EDTA anticoagulated samples of all febrile cases received from January 2014 to May 2014. Giemsa stained peripheral smears were also examined for malaria parasites. Abnormalities in WBC scattergrams were studied and their alteration in malaria cases recorded. Alterations in hematological parameters and instrument flags for samples positive for parasites were noted. All the samples were subjected to immunochromatographic assay by rapid test devices (RTD). Accordingly, sensitivity, specificity, positive predictive value (PPV) and negative predictive value (NPV) for detection of malaria by analysis of abnormal WBC scattergrams and by RTDs using immunochromatography were calculated.

**Results:** A total of 940 samples were analysed. Out of these, 49 cases were positive for malaria on peripheral smear. Various abnormalities in the WBC scattergrams, hematological parameters of these samples and the instrument flags for these samples were noted. WBC scattergram abnormalities typical of malaria showed a sensitivity of 80% and specificity of 93.26% for malaria diagnosis and RTDs using immunochromatographic assay showed a sensitivity of 90.91% and specificity of 98.92%.

**Conclusion:** Malaria diagnosis by examination of Giemsa stained peripheral smears is still the gold standard for diagnosing malaria, which is a laborious process requiring highly skilled and experienced personnel. Complete blood count is a routine investigation ordered in any febrile case and analysis of scattergrams in such cases can definitely aid in detection of malaria.

## Introduction

Malaria is one of the most common parasitic diseases present worldwide. It places a significant burden on the health care system and is endemic in various tropical countries, including India.<sup>1</sup> Diagnosis of malaria is time consuming and challenging as majority of the laboratories still use conventional microscopic identification of malaria parasite on Giemsa stained thick and thin smears. There is necessity for a convenient, sensitive and cost effective method to effectively screen all samples, especially when the workload is high, so as not to miss any malaria case.<sup>2,3</sup> Newer techniques like RDT, Quantitative buffy coat (QBC) and Polymerase chain reaction (PCR) have been introduced for malaria detection. Despite this, Giemsa stained peripheral smear examination remains the gold standard test for malaria parasite detection. RDTs are very convenient and are less labour intensive and can be performed by relatively unskilled technicians but have some limitations.<sup>4</sup> QBC and PCR tests are not available in all laboratories and are not cost effective at present.<sup>4</sup>

There is a constant search for alternate methods to detect malaria. One such method is the use of automated analyzers to detect malaria. As complete blood count is one of the basic investigations invariably done on any febrile patient, simultaneously noting abnormalities in WBC scattergrams can be helpful in early detection and decreases the turnaround time of a laboratory.<sup>1,4,5</sup>

This study was aimed at studying the usefulness of analyzing abnormal WBC scattergrams of automated

hematology analyzer Sysmex XN 1000 in the detection of malaria and also to note the various abnormalities in the hematological parameters and flags observed in malaria positive patients.

## Methodology

This study was conducted in the Central Diagnostic Laboratory attached to Department of Pathology, J J M Medical College. All blood samples of febrile illness and suspected malaria cases, received in the laboratory during the period of January 2014 to June 2014 were included in this study. History of febrile illness was obtained from the request forms. Blood samples were analysed using Sysmex XN 1000 automated hematology analyzer for complete blood count. Peripheral smears of all these samples were also examined for malaria parasites. Immunochromatographic tests were also done to detect antibodies to malarial antigen.

WBC scattergram abnormalities noted in WBC-DIFF channel were studied. Abnormal flaggings generated in the instrument were also noted. Abnormalities in hematological parameters like anaemia, thrombocytopenia and variations in leukocyte count were noted in smears positive for malaria parasite.

The sensitivity, specificity, positive predictive value (PPV) and negative predictive value (NPV) of WBC scattergram abnormalities typical in the detection of malaria positive cases were calculated using a 2x2 table. Results obtained from Immunochromatographic test were also compared with WBC scattergram results.

**Results**

A total of 941 samples were included in this study. Out of these, 49 samples were positive for malaria parasite on peripheral blood smear examination, all of which were Plasmodium vivax.


The age of the patients ranged from one year to 65 years, with majority of them falling in the age group of 31 to 40 years. Thirty seven were male patients and 12 were females.

Malaria positive cases had mean hemoglobin of 10.6g/dl (ranged from 6.1-16g/dl), mean total leukocyte count of  $6.88 \times 10^9/l$  (ranged from  $1.09 - 17.49 \times 10^9/l$ ) and a mean platelet count of  $73.3 \times 10^9/l$  (ranged from  $3 - 126 \times 10^9/l$ ). Anaemia was observed in 12% of cases, thrombocytopenia in 72% and leukopenia in 16% of cases.

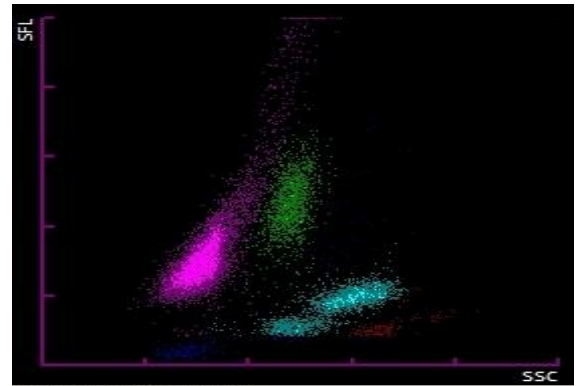
Of the 49 positive malaria cases, 40 cases showed abnormal WBC scattergrams, which included rightward shift of RBC ghost area, double neutrophil clusters, graying, merging of neutrophil and eosinophil clusters, double eosinophil clusters and pseudo eosinophilia. Four cases showed more than one scattergram abnormality.

**Table 1: Different abnormalities in WBC scattergrams**

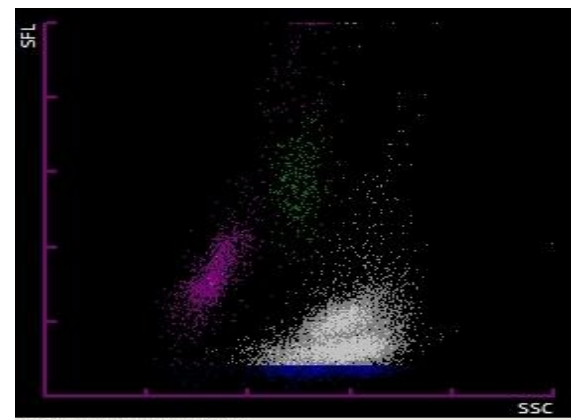
Abnormalities in WBC scattergrams	
Rightward shift of RBC ghost area	12(27.3%)
Double neutrophil clusters	10(22.3%)
Merging of neutrophil and eosinophil clusters	7(15.9%)
Graying	4(9.1%)
Multiple neutrophil clusters	4(9.1%)
Irregular shaped neutrophil cluster	4(9.1%)
Double eosinophil clusters	2(4.5%)
Pseudo eosinophilia	1(2.3%)
Total	44



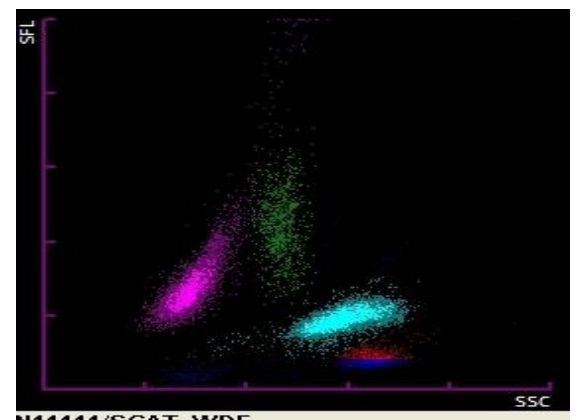
**Fig. 1: Graying of eosinophil and neutrophil clusters in WBC DIFF channel**



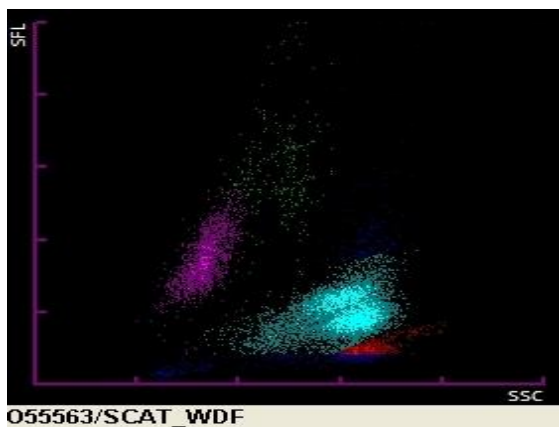
**Fig. 2: Double neutrophil clusters in WBC DIFF channel**



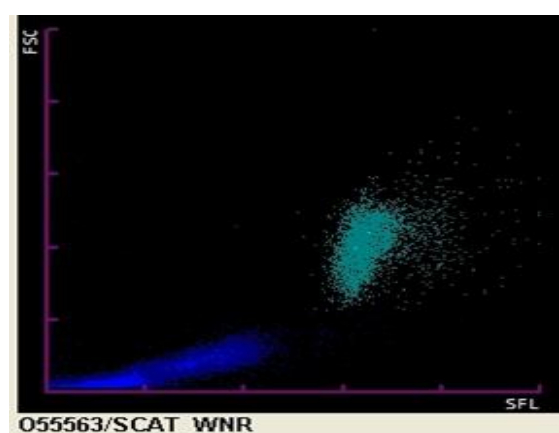
**Fig. 3: Double neutrophil clusters and graying of neutrophil clusters in WBC DIFF channel**



**Fig. 4: Irregular neutrophil cluster and pseudo eosinophilia in WBC DIFF channel**



**Fig. 5: Double neutrophil clusters and pseudo-eosinophilia in WBC DIFF channel**



**Fig. 6: Rightward shift of RBC ghost area in WBC BASO channel**

Flags observed in the present study were thrombocytopenia (42%), blasts or abnormal lymphocytes (24%), immature granulocytes (18%) and anaemia (16%).

Immunochromatographic tests were positive for *P. vivax* in 34 cases, positive for both *P. vivax* and *P. falciparum* in 2 cases and negative for both in 4 cases. It showed a sensitivity of 90.91%, specificity of 98.92%, and positive predictive value of 80% and negative predictive value of 99.57%. WBC scatter grams showed a sensitivity of 80%, specificity of 93.26%, and positive predictive value of 40% and a negative predictive value of 98.81%.

## Discussion

Sysmex analyzer works on the principle of flow cytometry and uses a semiconductor laser to give three types of optical data about the cells. Forward scatter light (FSL) which indicates cell size, side scatter (SSC) determines the complexity of internal structure such as granules, and side fluorescence light (SFL) indicates the nuclear content.<sup>5</sup>

Hemozoin, a crystalline brown pigment, is produced when free heme is liberated during hemoglobin catabolism

is detoxified by malarial parasites. Hemozoin is phagocytosed by neutrophils and monocytes. These cells allow the identification of malaria infection by automated methods by producing abnormal scattergrams.<sup>3</sup>

The present study showed abnormalities in hematological parameters like anaemia, leukopenia and thrombocytopenia which were also observed in previous studies.<sup>1,2</sup>

In a study conducted by Sharma et al. the most common scattergram abnormalities noted in *P. vivax* samples were graying of eosinophil and neutrophil groups (47.05%), rightward shift of RBC ghost area (32.4%) and two neutrophil populations (15.7%). In the present study, the most common scattergram abnormalities noted were rightward shift of RBC ghost area (27.3%), double neutrophil clusters (22.3%) and merging of neutrophil and eosinophil clusters (15.9%).

A study conducted by Mohapatra et al. showed a sensitivity and specificity of 74.2% and 91.1% respectively. Another study by Sharma et al. showed a sensitivity of 83.78% and specificity of 94.82%. In the present study, the sensitivity was 80% and specificity was 93.6% which in comparison to immunochromatographic study is less specific and sensitive. In the present study, the flags like thrombocytopenia, abnormal lymphocytes, anaemia and immature granulocytes observed in the analyser. Although these findings are nonspecific, these can provide clues to the detection of malaria.

## Conclusion

Detection of malaria by automated hematology analyzers is a relatively new concept and needs further refinement for making an accurate diagnosis. Although, it provides subtle clues for detecting malaria, it definitely aids in the diagnosis of malaria in a febrile illness, especially when clinical suspicion is low. Awareness regarding scattergrams abnormalities typical of malarial infection increases the laboratory's efficiency in malaria diagnosis.

## References

1. Sharma S, Sethi N, Pujani M, Kushwaha S, Sehgal S. Abnormal WBC scattergram: A clue to the diagnosis of malaria. *Hematology* 2013;18:101-5.
2. Jain M, Gupta S, Jain J, Grover RK. Usefulness of automated cell counter in detection of malaria in a cancer set up-Our experience. *Indian J Pathol Microbiol* 2012;55:467-73.
3. Briggs C, Da Costa A, Freeman L, Aucamp I, Ngubeni B, Machin SJ. Development of an automated malaria discriminant factor using VCS technology. *Am J Clin Pathol* 2006;126:691-8.
4. Bailey JW, Williams J, Bain BJ, Parker-Williams J, Chiodini PL. General Haematology Task Force of the British Committee for Standards in Haematology. Guideline: the laboratory diagnosis of malaria. General Haematology Task Force of the British Committee for Standards in Haematology. *Br J Haematol* 2013;163:573-

- 80.
5. Mohapatra S, Samantaray JC, Arulselvi S, Panda J, Munot K, Saxena R. Automated detection of malaria with haematology analyzer Sysmex XE-2100. *Indian J Med Sci* 2011;65:26-31.
  6. Mubeen KH, Devadoss CW, Rangan RA, Gitanjali M, Prasanna S, Sunitha V. Automated Hematology Analyzers in Diagnosis of Plasmodium vivax Malaria: An Adjunct to Conventional Microscopy. *Mediterr J Hematol Infect Dis* 2014;6:e2014034.