

Histomorphological spectrum of tumor and tumor like lesions of testis and paratesticular structures – A cross sectional study

Sanjay M^{1,*}, Sushma HM²

¹Assistant Professor, Adichunchanagiri Institute of Medical Sciences, BG Nagara, ²Assistant Professor, Mysore Medical College & Research Institute

***Corresponding Author:**

Email: sanjay.mysore82@gmail.com

Abstract

Objectives: To study the prevalence and histomorphologic spectrum of tumor and tumor like lesions of testis and paratesticular tissues.

Material and Methods: This was a prospective study conducted involving 59 cases. The clinical details were recorded from the case records. Each specimen was subjected to detailed gross examination and the histopathological features were noted on hematoxylin and eosin stained slides of all the specimens. The clinical data, macroscopic and microscopic findings in these cases were tabulated and analyzed. Descriptive parameters like mean, percentage etc were calculated using SPSS software.

Results: Prevalance of testicular tumors was 0.26%. Right testis [31 cases (52.54%)] was involved more commonly than the left [28 cases (47.45%)]. Majority of the testicular lesions were tumor like lesions comprising of 41(69.50%) of the cases followed by tumors which accounted for 18 (30.50%) cases. Seminoma was the commonest of germ cell tumor (33.30%) followed by 27.70% of germ cell tumor of more than one histologic type. Non-specific orchitis was commonest of all tumor like lesions (54.23%) followed by tuberculous orchitis. There were one case (5.60%) each of adenomatoid tumor and rhabdomyosarcoma involving paratesticular region.

Conclusion: Tumor and tumor like lesions of testis have similar presentations in the form of scrotal swelling and pain. Majority of the testicular lesions were tumor like lesions. Among tumors seminoma was the commonest neoplasm. Histopathologic examination and routine hematoxylin and eosin staining can help in accurately diagnosing and determining the prognosis of these rare tumor and tumor like lesions of testis and para testicular region.

Keywords: Testis, Paratestis, Tumors, Tumor like lesions

Introduction

The testicular tumors are relatively rare yet they constitute the fourth most common cause of death from neoplastic conditions in young male population.^[1] Although testicular cancer accounts for only 1% of all tumors in male, it is the most common malignancy in males between 15 & 34 years of age.^[2] In addition to its neoplastic and malignant features, testicular disorders also represents a developmental, endocrine and reproductive problem.^[2,3]

Relatively uncommon, the testicular neoplasms are of great interest and importance because of their varied histologic appearances and the diverse or even conflicting views held regarding their histogenesis.^[4] Clinically the diagnosis of testicular tumor is delayed in many cases. No satisfactory classification is available, therefore the urologists, the radiologists and chemotherapists are essentially dependent upon histological diagnosis of testicular tumors and tumor like lesions. Despite the major advances there is a gap in the knowledge in understanding the origin, pathological process and therapeutics of tumor.

Examination of the entire testis is required for exact histopathologic classification. It also helps in determining the stage and extent of the disease. Histopathologic features have a major stake in determining the prognosis and therapeutic options.^[2] Relative rarity of these tumors and tumor like lesions,

diverse histological structure, their controversial histogenetic terms and variation in the incidence of lesions in different parts of world, prompted to undertake the present study. Our aim was to study the prevalence of tumors and tumor like lesions of testis and paratesticular tissues and to study the clinic pathological parameters and histomorphology of the various tumors and tumor like lesions of testis and paratesticular tissues.

Materials and Methods

The present study was a prospective study conducted over a duration of two years.

All the testicular and paratesticular specimens received in the department were included in the study. The clinical details were recorded from the case records. Each specimen was subjected to detailed gross examination and the histopathological features were noted on hematoxylin and eosin stained slides of all the specimens. The clinical data, macroscopic and microscopic findings in these cases were tabulated and analyzed. Descriptive parameters like mean, percentage etc were calculated using SPSS software.

Sample size: A total of 59 cases were studied in two years.

Inclusion criteria: All tumors and tumor like lesions of testis and paratesticular tissues including secondaries as

categorized in accordance to WHO classification of 2004 were included in the study.

Exclusion criteria: Lesions of testis and paratesticular structures occurring secondary to radiation induced damage were excluded from the study. Recurrent tumors were also not included in the present study.

Results

There were total 59 cases of tumors and tumor like lesions of testis and paratesticular tissues.

Age distribution: The youngest patient was 20 years and the oldest was 53 years old.

Age range of various testicular and paratesticular tumors and tumor like lesions is shown in Table 1 and 2 respectively.

Side involved: In the present study right testis was involved more commonly than the left i.e. in 31 cases (52.54%) right testis was involved and the left testis

was involved in 28 cases (47.45%). There was no case with bilateral testicular involvement.

Mode of presentation: The commonest mode of presentation was scrotal swelling 93.22% (55/59), followed by pain seen in 37.28% (22/59) cases, pyoceles/ hydrocele in 6.77% (4), tenderness in 6.77% (4) cases. There was no involvement of scrotal skin in any of the cases. There were no patients in present study with history of cryptorchidism, trauma, mumps, syphilis, brucellosis or any endocrine disorder.

Nature of specimen: Orchiectomy specimen was received in 52 (88.14%) cases and biopsy in 7 (11.86%) specimens.

Histopathology: Testicular lesions comprised 96.61% of total (57/59) cases and 3.38% (2/59) cases were of paratesticular pathology. Out of 57 testicular lesions, 28.07% (16/57) cases were diagnosed neoplastic and remaining 82.54% (41/57) were tumor like lesions. Both the cases 100% (2/2) of paratesticular pathology were diagnosed as neoplasm.

Table 1: Shows age range of various testicular tumors

Sl. No.	Type of tumor	No. of Cases	Age group in decades (years)							
			0-10	11-20	21-30	31-40	41-50	51-60	61-70	71-80
01	Seminoma	7	--	--	1	1	4	--	1	--
02	Yolk Sac tumor	1	--	--	--	--	--	--	--	--
03	Teratoma	2	--	1	--	1	--	--	--	--
04	GCT of >1 histological type	6	--	--	3	--	2	--	1	--
05	Lymphoma	2	--	--	--	--	--	--	1	1
	Total	18	0	1	4	2	6	--	3	1
	Percentage	100	5.56	5.56	22.22	11.11	33.33	--	16.66	5.56

GCT- Germ cell tumor

Table 2: Age range of various tumor like lesions of testis

Sl. No	Type of tumor like lesion	No. of Cases	Age group in decades (years)							
			0-10	11-20	21-30	31-40	41-50	51-60	61-70	71-80
01	Epidermal Cyst	1	--	1	--	--	--	--	--	--
02	Non specific orchitis	33	1	4	4	9	3	7	4	1
03	Non specific granulomatous	1	--	--	--	--	--	1	--	--
04	Specific orchitis	5	--	--	--	2	1	2	--	--
	Total	41	1	5	4	11	5	10	4	1
	Percentage	100	2.44	12.20	9.76	26.82	12.20	24.38	9.76	2.44

Table 3: Showing distribution of testicular tumours

Sl. No.	Histopathological diagnosis	Number of cases	Percentage %
01	Seminoma	07	38.90
02	Yolk Sac tumour	01	05.55
03	Teratoma	02	11.11
04	Germ cell tumour of more than one histological type	06	33.33
05	Lymphoma	02	11.11
Total		18	100.00

Table 4: Shows distribution of tumour like lesions

Sl. No.	Histopathological type	No. of cases	Percentage %
01	Epidermal cyst	01	02.44
02	Non-specific orchitis	33	80.49
03	Non-specific granulomatous orchitis	01	02.44
04	Specific orchitis	05	12.19
Total		41	100.00

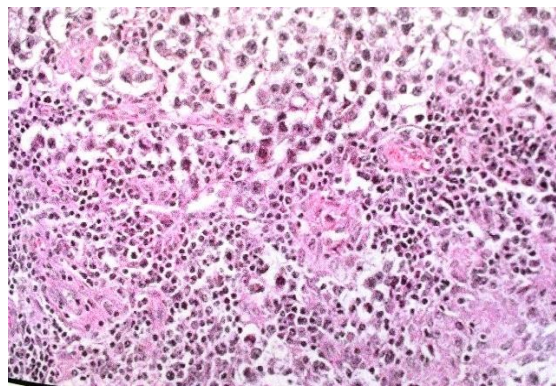


Fig. 1b: Section showing monomorphic tumor cells with prominent nucleoli with lymphoid cell aggregates – in seminoma (Hematoxylin and Eosin x 100)

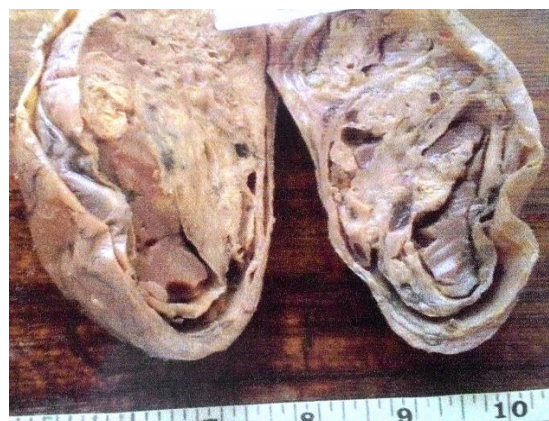


Fig. 2a: Gross Image showing cut surface of yolk sac tumor– solid and cystic with grey yellow appearance

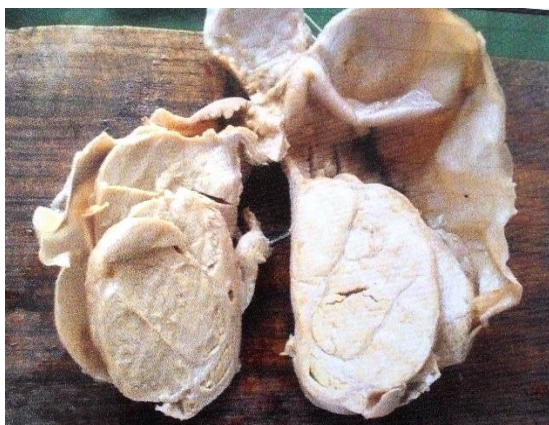

Fig. 1a: Gross Image showing cut surface of seminoma – solid grey white appearance

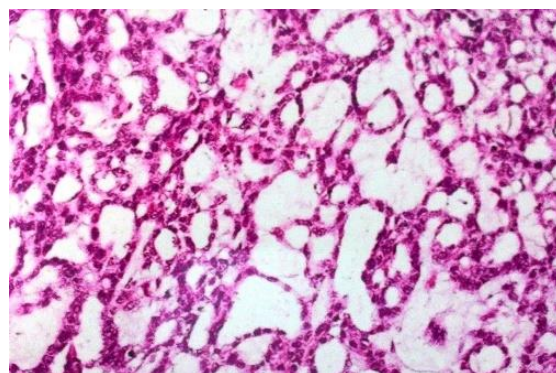


Fig. 2b: Section showing retiform arrangement of tumor cells in yolk sac tumor (Hematoxylin and Eosin x 100)

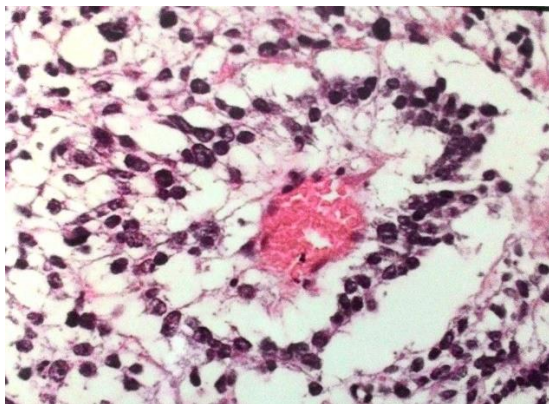


Fig. 2c: Section showing shiller duval body in yolk sac tumor (Hematoxylin and Eosin x 100)

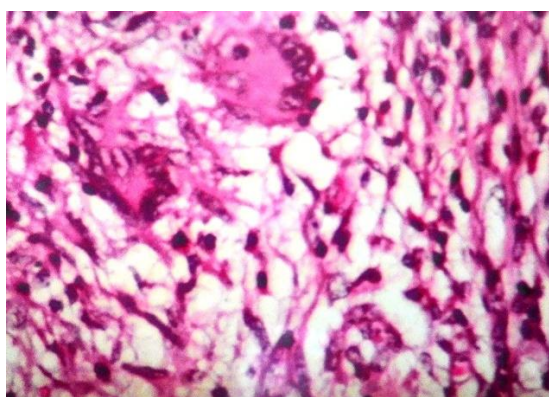


Fig. 3: Section showing granulomatous inflammation – in granulomatous orchitis. (Hematoxylin and Eosin x 100)

Discussion

The present study dealt with tumor and tumor like lesions of testis and paratesticular structures and was based on total 59 cases over a period of 5 years.

During the study period five years total of 6803 tumors were encountered in the department out of which 16 tumors were of testicular origin and two tumours were of paratesticular structures. This accounted for 0.26% of all tumors. The incidence of testicular and paratesticular tumors as recorded in literature varies from 0.5% to 2.73%.^[5]

During the 5 years study period, 18 tumors of testicular and paratesticular origin were encountered out of 85 cases of malignancies confined to male genital system. Thus the percentage of testicular and paratesticular tumors in relation to male genital system was to 21.17%. In literature the incidence of this ranges from 2.57% to 23.4% our percentage is in close agreement to that of Pratap et VK at al.^[4]

Demography and Clinical Data:

Age: Age range in the present study ranged from 17 to 80 yrs with the mean age of 41.61years. Majority of testicular lesions were in the age group of 31-40 years (35.60%). Age range observed in present study was

closer to that of Pratap VK et al. A case of rhabdomyosarcoma in a person in the 2nd decade was the youngest and one case of seminoma in 6th decade of life was the oldest patient with respect to tumors.

Mode of Presentation: Scrotal swelling was the commonest mode of presentation accounting for a total of 93.2% of cases followed by pain in 37.2%. In the series of Pratap VK el al, commonest presenting symptom was scrotal swelling (92.00%).^[4]

Comparative analysis of incidence of various histological types of testicular tumours.

Tumors of the testis have a very diverse histological structure and it is therefore essential that orchidectomy specimens be examined carefully. Many representative blocks of tumor tissue should be prepared after extensive slicing of the specimen. The specimen should not be discarded until the clinician and pathologist agree that the response of the patient to treatment is characteristic of the tumor that was diagnosed.

Germ cell tumors: Main bulk of the tumors in the present study was formed by germ cell tumors(16 cases) accounting for 88.89%. This is in close agreement to that observed by Sputa SC et al (88.66%), (82.93%).^[6]

In the literature, the percentage of germ cell tumor of more than one histological type varies widely. Mostofi and Price observed more than one histological pattern in about in 40% of testicular tumors of germ cell origin.^[7] Reddy et al reported an incidence of 4.23^[8] and Pratap VK et al 1.48%.^[4] The present study accounted for 27.7% of cases which is in close agreement with that observed by Dixon and Moore(31.1%)^[9], Deotra A, et al (23.0%).^[11]

Germ cell tumor of one histological type

Seminoma: Seminoma is the commonest histological type encountered in this study (6 out of 18 tumors) accounting for 33.3% of all tumors. The incidence rate of seminoma in this study is in agreement with that observed by Dixon and more (34%), Deotra et al (34%).^[1,9]

Majority of cases of seminoma were found in 3rd decade of life. Age range of seminoma in the present study varied from 30 to 53 years with a mean age of 35.5year. Pratap VK et al and Reddy et al reported age range and mean age of 20-60/41.25 years and 15 to 60 years/ 40 years respectively.^[4,8]

None of the patients in the present study had cryptorchidism, radiation exposure of history of trauma.^[4,8]

The typical seminoma and the anaplastic seminoma present essentially the same appearance. In 85% of patients the testis enlarges sometimes reaching 10 times the normal size. In 15% the testis is normal or smaller. The enlargement is usually diffuse. The cut section show a grayish white glistening mass that is lobulated

and homogenous. Areas of necroses and hemorrhage are infrequent. In about 8% there is extension beyond the capsule to the scrotal sac, the epididymis or the spermatic cord.

Atypicalities in the stroma in the form of scirrhous and Lymphoid Follicle features are also noted. Tumor giant cells or syncytial masses resembling syncytiotrophoblast may be present in the stroma. Immunohistochemically, seminoma cells exhibit reactivity for placental alkaline phosphatase (PLAP), vimentin, ferritin and angiotensin I converting enzyme but are generally negative for keratin, a fact of some importance in the differential diagnosis with embryonal carcinoma. Serum levels of placental alkaline phosphatase are elevated in 40% of cases of seminoma.

First recognized by Masson in 1946 and designated it as Seminoma Spermatocytariae. He considered that, although the classical seminoma originated from undifferentiated type of germ cells, spermatocytic seminoma was derived from spermatogonia and represented a more differentiated type of germ cell neoplasm. Although Masson reported 6 cases and gave a detailed description of the histological appearances, to which little has been added over the years, spermatocytic seminoma has only become recognized as a specific entity during the last two decades. Recent studies supported and confirmed Masson's findings and helped to establish spermatocytic seminoma as a distinctive clinicopathological entity that differs from the classical type pathologically as well as clinically. It is significant that spermatocytic seminoma has been included as a specific entity in the WHO classification of testicular tumor. The incidence of spermatocytic seminoma ranges anywhere from 1.7% to 12%.

Microscopically it is composed of solid sheets of tumor cells with little or no intervening stroma. A polymorphous cell population is the hallmark. There are three types of cells. The mitotic activity is often brisk and atypical mitosis may occur.

Anaplastic seminoma are thought to be variant of classical type. In most of the series its incidence varies from 2% to 15% of all seminomas. Microscopy, reveals marked cellular and nuclear pleomorphism, brisk mitosis (> 3/ hpf), scanty connective tissue stroma and minimal lymphocytic infiltration. Mostofi found that most of the metastasizing seminomas were anaplastic. Maier and his associates showed that in contrast to typical seminoma, anaplastic seminoma has a poorer prognosis.

Teratoma: In the present study teratomas accounted for 25% (4 cases) of total testicular tumours. Teratoma accounted for 10.02% of testicular tumors as observed in the study by Dixon and Moore.^[9] In a study by Thota R they accounted for 13.90% of the testicular tumors.^[10]

The age range in present study was 21 to 28 years which is in close agreement to the study results

obtained by Deotra et al with age range of 21 to 30 years.^[1]

Mature teratoma occurs with relatively greater frequency in infancy and childhood and are usually benign. Similar tumors may occur in adult but there is a far greater risk of small hidden foci of immature malignant components that may escape detection despite rigorous sampling of the lesion.

Although no malignant areas may be seen in immature teratoma, they should not be regarded as benign since about 20% show metastasis and terminate fatally in 5 years.

Teratoma with malignant transformation shows clear evidence of malignancy in derivatives of one or more germ cell layers. Thus, there may be a focus of squamous cell carcinoma, mucin-secreting adenocarcinoma, or a sarcoma. They occur more commonly in adults.

Embryonal carcinoma: There was one case of embryonal carcinoma in the present study accounting for 6.25% of testicular tumours. In the study by Deotra et al it accounted for 28% of all testicular tumours.^[1] Grossly embryonal carcinoma is smaller than other types and is less firm in consistency. On cut section it is gray white with foci of haemorrhage and necrosis. Invasion of the tunica, epididymis and spermatic cord occurs with considerable frequency and distant metastasis occurs in early stage of tumor development. It is highly malignant tumor with relatively low radio sensitivity.

Microscopy: The tumor is composed of primitive cells with clear cytoplasm arranged in a variety of patterns, acinar, tubular, papillary and solid. The nuclei are oval or are round with an irregular and coarse nuclear chromatin and one or large nucleoli with indistinct cell borders. The stroma shows primitive mesenchyme. Lymphocytic and granulomatous reactions are infrequent. Some embryonal carcinoma may contain syncytio trophoblastic cells. Areas of hemorrhage and necrosis are seen. Embryoid bodies may be seen. Invasion of the tunica, epididymis and spermatic cord occurs with considerable frequency and distant metastasis occurs in early stage of tumor development. It is highly malignant tumor with relatively low radio sensitivity. Immunohistochemically tumor cells show reactivity with Keratin, CD-30, 43-9F monoclonal antibody.

Germ cell tumor of more than one histological type: Five case of germ cell tumor of more than one histological type were recorded in the present study accounting for 27.7% of all the tumors.

This is in close agreement to that observed by Dixon and Moore (31.1%).^[9] The age range was 22 to 45 years in present study. Gupta SC et al have noted an age range of 14 to 40 years.^[10]

Except spermatocytic seminoma which tends to occur in pure form, any other cell types may occur in combinations. The germ cells capable of developing into conceivable mixture of different cell types have fascinated and confused generations of physicians. The situation has been somewhat clarified by the hypothesis that elements of choriocarcinoma and teratoma in a germ cell tumor of the testis are usually derivatives of embryonal carcinoma. Mostofi FK supports this view.^[7] Willis et al studied germ cell tumors extensively and reached the conclusion that the co-existence of embryonal carcinoma and seminoma was not fortuitous.^[12] They suggested that the young germ cells are capable of expressing its totipotentiality as mixture of embryonal carcinoma, teratoma or choriocarcinoma and that with advancing age the totipotential tendency of the germ cell lessen until they become limited to a homogenous seminoma.

From the point of view of frequency and prognosis, two combinations are most important:

Embryonal carcinoma and teratoma (teratocarcinoma): This is the most frequent combination, constituting about 24% of all testicular tumors. Its gross appearance depends on the relative amount of these two components. The term, teratocarcinoma is falling into disuse; current preference for designating the lesion as a mixed NSGCT, followed by a listing and proportion of the relative components. In the present study among tumors of more than one histologic type, seminoma with embryonal carcinoma was the commonest combination accounting for three out of total five cases.

Choriocarcinoma and any other type of germ cell tumor: This combination has grave prognosis, combination of teratoma, embryonal carcinoma and choriocarcinoma constitutes 1% of all testicular tumors.

Tumors of paratesticular region:

Adenomatoid tumor: These are the most common paratesticular tumor, accounting for one third of all epididymal neoplasm. In 20% of the cases they are located within the testicular parenchyma. The tumor is known under a variety of names, such as mesothelioma, lymphangioma and adenomyoma. The ultrastructural and immunohistochemical data support the mesothelial derivative of these tumors. A cases of adenomatoid tumor of spermatic cord was noted in the study which accounted for 5.60% of all tumors in the study. In study by Pratap VK et al it accounted for 1.33% all the cases.^[4]

Rhabdomyosarcoma: The study included a case of Rhabdomyosarcoma accounting 5.6% of total tumors which is in close agreement to that of study by Prate VK et al(3.99%)^[4] This is the most important soft tissue tumors at this site. It occurs particularly in infants, children and young adults.

Tumours like lesions of testis and paratesticular

Structures: In the present study three were 41 cases of tumor like lesions accounting for 69.50% of total cases.

Among them non-specific orchitis was commonest accounting for 78.60% of tumor like lesions. Microscopically all cases showed mild to moderate infiltration of inflammatory cells. The commonest mode of presentation was scrotal swelling followed by pain. The findings were in close correlation with study by Algaba. F et al.^[13]

Non-specific granulomatous orchitis: Four cases of non-specific granulomatous orchitis were reported accounting for 9.77% of total cases. Gregor mikuz and Ivan damjanov in their review study observed that 5.1% of presumptive diagnosis of neoplasia turned out to be non – specific granulomatous orchitis. The gross and microscopic findings are similar to that observed in literature.^[14,15]

Specific orchitis: Four cases were diagnosed as specific orchitis accounting for 9.77% of total tumour like lesions. All the cases of specific orchitis had tubercular etiology. Damjanov I and Jonathan I Epstein observed that tubercular orchitis often occurs in middle life which is similar to that seen in present study (31 years to 50 years). The gross and microscopic findings are similar to those observed in literature.^[14,15]

Epididymal cyst: One case of Epididymal cyst was recorded in the present study which accounted for 2.405 of tumor like lesions.

The age of the patient was 80 yrs. The most common age given in literature is 40 years to 59 years of age. The gross and microscopic features were similar to that observed by Algaba. F et al.^[13]

Conclusion

Tumor and tumor like lesions of testis have similar presentations in the form of scrotal swelling and pain. Majority of the testicular lesions were tumor like lesions. Among tumors seminoma was the commonest neoplasm. Histopathologic examination and routine hematoxylin and eosin staining can help in accurately diagnosing and determining the prognosis of these rare tumor and tumor like lesions of testis and para testicular region.

References

1. Deotra A, Mathur DR Vyas MC. A 18 years study of testicular tumour in Jodhpur, western Rajasthan. *Ind. Journal of surgery* 1994;40(2):68-70.
2. Scott Kinkade. Testicular cancer. *Americal family physician* 1999;59(9):2539-2550.
3. Siegel RL, Miller KD, Jemal A. Cancer statistics, 2016. *CA Cancer J Clin* 2016;66:7.
4. Pratap VK, Agarwal S. Testicular neoplasms. *India Journal of cancer* 1971;40:53.
5. Moghe KV, Agrawal RV, Junnerkar RV. Testicular Tumours. *Indian J Cancer* 1970;7:906.
6. Algaba. F, Mikuz G., Boccon – Gibod. L., Trias I., Arce Y., Montiroi R., M et al. pseudoneoplastic lesions of

- testis and paratesticular structures. *Virchow's Archiv* 2007 December;451(6):987-97.
7. Mostofi FK, Price EB Jr. Tumors of male genital system. Atlas of tumor Pathology, Series 2, Fascicle 8, AFIP, Washington DC, 1973.
 8. Reddy DB Ranganayakamma I. Review of 56 cases of testicular tumours. *Indian J Cancer* 3:255 1966;3:255.
 9. Dixon FJ, Moore RA. Tumour of the male sex organs. Atlas of tumour pathology. Armed forces institute of pathology, Washington Section VIII, Fascicle 31B and 32, 1952.
 10. Thota R, Deshmukh AV, Pattankar VL. Clinicopathological study of testicular tumours. In Gulbarga (unpublished doctoral dissertation, Gulbarga University Gulbarga., 1995:59-75.
 11. Gupta SC, Sharma A, Mehrotra TN, Gupta IM. Testicular tumours – A clinicopathological study. *Ind. J. Surgery* 1983:664-672.
 12. Willis RW, Copeland DD, Fried AF, Splenogonadal fusion. *Journal of urology* 1985:133:1052-1053.
 13. Algaba. F, Mikuz G., Boccon – Gibod. L., Trias I., Arce Y., Montiroi R., M et al. pseudoneoplastic lesions of testis and paratesticular structures. *Virchow's Archiv* 2007 December; 451(6):987-97.
 14. Damjanov I. male reproductive system – Testis, epididymis and Vas deferens, Chapter 67 in *Anderson's Pathology*, Damjanov I van, Linder, 10th Edn., Modby, 2166-2230.
 15. Jonathan I Epstein. The lower urinary tract and male genital system. Chapter 12 in *Robbins and Cotran Pathological basis of diseases*, Kumar, Abbas, Fausto, 7th Edition, WB Saunders Company, 2004:1037-41047.