

Giant Plexiform Unicystic Ameloblastoma: A rare variant of Ameloblastoma

Yashita Gupta^{1,*}, Mohd. Jafar Memon², Nighat Hussain³, Renuka Gahine⁴

¹Senior Resident, ³Associate Professor, Dept. of Pathology & Laboratory Medicine, AIIMS, Raipur, ²Assistant Professor, Pt. JNM Medical College, Raipur, ⁴Professor & Head, Dept. of Pathology, Govt. Medical College, Rajnandgaon

***Corresponding Author:**

Email: yashigupta@gmail.com

Abstract

Ameloblastoma is the most common clinically significant odontogenic tumor of the gnathic bones, characterized as a benign but persistent and locally aggressive neoplasm. According to the WHO, it presents in four forms: unicystic, multicystic, peripheral (within soft tissue), and desmoplastic, with the conventional solid intra-osseous type being the most common (86%). Microscopically, many subtypes or patterns have been described: follicular, plexiform, acanthomatous, papilliferous-keratotic (including so-called keratoameloblastoma), granular cell, desmoplastic, vascular, and with dentinoid induction (dentinoameloblastoma). This report describes a case of a giant unicystic ameloblastoma involving the left side of the mandible. Radiographically appearing as a unilocular radiolucency and non-dentigerous in nature. Histopathological analysis showed features of plexiform pattern of a unicystic ameloblastoma.

Keywords: Ameloblastoma, Odontogenic neoplasm, Unicystic, Plexiform

Access this article online	
Quick Response Code:	Website: www.innovativepublication.com
	DOI: 10.5958/2394-6792.2016.00096.X

Introduction

Churchill first used the term ameloblastoma in 1934^[1]. Ameloblastoma, is derived from the English word “amel” which means enamel and the Greek word “blastos” which means the germ^[2]. Ameloblastoma is defined as most common benign epithelial odontogenic tumor, which is slow growing, but locally aggressive, persistent, and frequently recurrent^[3]. It accounts for about 1% of all oral tumors and about 9-11% of odontogenic tumors^[4]. The majority of ameloblastomas occur in the posterior mandible, with a wide variety of radiographic and clinical presentations, each carrying treatment and prognostic implications. The tumor arises from the enamel organ or its progenitor cell lines^[3].

Unicystic ameloblastoma (UA) is considered at best an in situ or superficially invasive form of ameloblastoma and accounts for 6% of reported cases of ameloblastoma^[5]. UA is defined as variant of ameloblastoma in which there is de novo development of a cyst or neoplasm (ameloblastomatous) development in a pre-existing cyst^[6]. We report a case of giant plexiform unicystic ameloblastoma which is a relatively rare variant of UA.

Case Report

A 22-year-old male patient presented with the chief complaint of left side progressively increasing facial

swelling since 2 years. Swelling initially appeared in the left infraorbital region and gradually increased in size completely involving the left side of the face. Swelling was painless initially, but the patient now complains of mild persistent pain. The patient was prescribed antibiotics and ointments by a general practitioner multiple times in the last 2 years

The swelling was roughly oval in shape with approximate size of 16 x 13 x 12.5 cm. The margins of the swelling were diffuse. The skin overlying the swelling was smooth with a scar mark in the centre due to local application of some ointment given by general practitioner (Fig. 1).

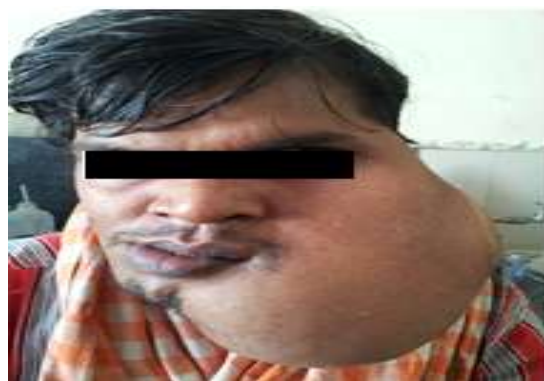

Fig. 1: Diffuse large swelling involving the left side of the face

On local examination, swelling was found to be firm to soft and temperature of overlying skin was slightly elevated. At angle of mandible expansion of the cortical plates was noted. Intraoral examination revealed a single swelling in retromolar area.

Clinically provisional diagnosis of benign odontogenic lesion was made. Differential diagnosis of

ameloblastoma, dentigerous cyst, and maxillary carcinoma was considered.

Radiologically, on sonography the lesion showed a well-defined unilocular radiolucency involving the left side of the mandible extending to the posterior border of the body and ramus of mandible. No evidence of cervical lymphadenopathy.

CT scan of the lesion showed a large expansile unilocular osteolytic lesion in the posterior part of body and ramus of the mandible measuring 20x13x13 cm. Lesion seems to be compressing and displacing the maxilla and airway towards the right side.

Routine investigations were performed and all the haematological and biochemical parameters were within normal limits. A fine needle aspiration cytology was then performed, yielding straw coloured fluid which only revealed few macrophages, neutrophils and mononuclear cells against a proteinaceous background (Fig. 2).

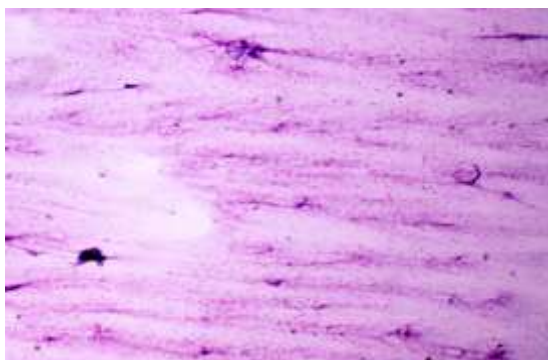


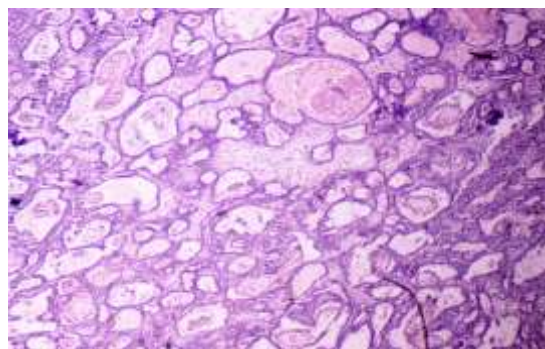
Fig. 2: Smears prepared from centrifuge deposit only revealed few macrophages, neutrophils and mononuclear cells against a proteinaceous background

Due to the large size of lesion, a segmental mandibular resection was planned. We received a specimen which revealed a well circumscribed tumour mass measuring about 12 cm X 10 cm, firm in consistency. Outer surface of mass was smooth with attached soft tissue, cut surface of which showed a cystic sac filled with gelatinous material, at places thickening of the cyst wall was evident (Fig. 3, 3a).

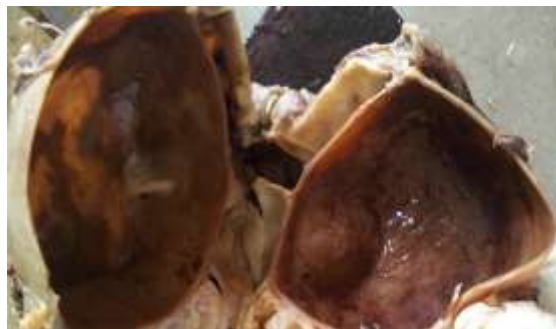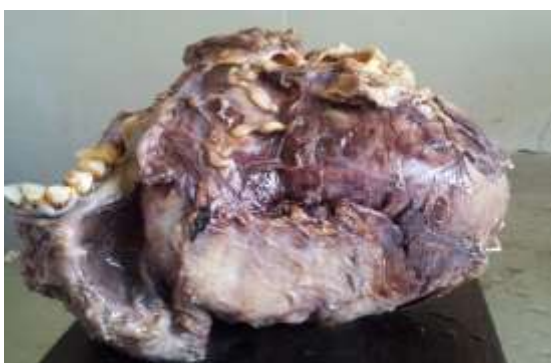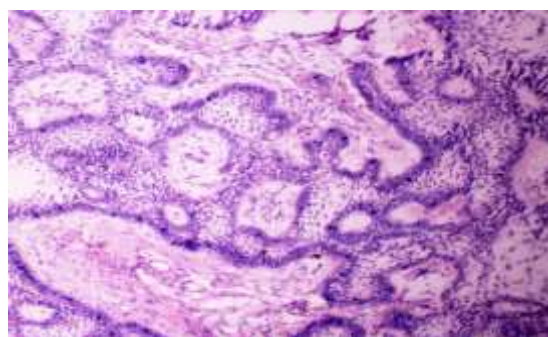


Fig. 3, 3a: Gross appearance: Specimen shows a well circumscribed tumor mass measuring about 12 cm X 10 cm, the cut surface is cystic sac like, foci of thickening of the cyst wall is detected

Microscopically, a fibrous cyst was lined by odontogenic epithelium, presence of basal cells with hyperchromatic nuclei, nuclear palisading with polarization and covered by loosely arranged stellate reticulum-like cells. The proliferation of these cells was noted in cystic lumen arranged as interconnecting strands and cords in a plexiform pattern (Fig. 4).



a



b

Fig. 4: H & E stained section showing ameloblastic cystic epithelium showing intraluminal proliferation in the form of plexiform pattern (a) H & E stain; 10x and (b) H & E Stain; 40x

Discussion

Robinson and Martinez^[1] considered ameloblastoma only if one or more of the following criteria were present:

- In the lining epithelium the basal cells were clearly columnar with hyperchromatic nuclei and the overlying cells were only loosely textured with the absence of “cohesiveness”,
- Downgrowth of ameloblastic epithelium into the connective tissue portion of the cyst wall,
- Presence in the connective tissue portion of the cyst wall of islands composed of a periphery of columnar epithelial cells and a centre identical to stellate reticulum,
- Intraluminal nodules composed of anastomosing cords and islands of epithelium

Ackermann et al.^[7] histologically classified UA into following four histologic subgroups: (1) luminal UA; (1.2) luminal and intraluminal UA; (1.2.3) luminal, intraluminal, and intramural UA; (1.3) luminal and intramural UA. The case described above shows presence of a reticulated plexiform pattern of cells involving the cyst lining and reaching upto the cystic lumen. Hence, as per Ackerman classification it belongs to the subgroup (1.2).

Philipsen and Reichart^[8] in their critical review of 193 cases of UA divided the material into two categories: UAs associated with an unerupted tooth and UAs lacking an association with an unerupted tooth. The present case was not associated with any unerupted tooth, so this tumor can be termed as non-dentigerous variant.

Approximately 85% of ameloblastomas arise in the mandible, with the majority occurring in the molar/ramus area. Maxillary tumors also develop most frequently in the molar region but occasionally may be seen in the anterior regions, maxillary sinus, and nasal cavity^[9]. Present case supports a marked prevalence for mandible.

UA differs in gender distribution depending upon its association with unerupted tooth. Dentigerous variant shows a slight male predominance with a male: female ratio of 1.6:1. However, in non-dentigerous variant the gender ratio is reversed to a male: female ratio of 1: 1.8^[8]. The present case though being the non-dentigerous variant, as opposed to the above findings was seen in a male patient.

Cases associated with an unerupted tooth show a mean age of 16 years as opposed to 35 years in the absence of an unerupted tooth^[8]. The mean age is significantly lower than that for solid/multicystic variant^[7]. However, in present non-dentigerous case patient's age is lower (22 years) than the mean age.

UA can be differentiated from other types of non-neoplastic odontogenic cysts by investigating the expression of calretinin. Expression of calretinin was demonstrated in 93.5% of invasive ameloblastomas and 81.5% of UA. However, lesions like odontogenic keratocysts, residual apical periodontal cysts, or dentigerous cysts failed to show the expression suggesting that calretinin may be a specific marker for

ameloblastic tissues^[10]. Other markers like lectins (Ulex europaeus agglutinin I and Bandeiraea simplicifolia agglutinin I), proliferating cell nuclear antigen and Ki-67 may also be helpful in differentiating UA from any other cyst^[11,12,13].

UA require less aggressive therapy, necessitating only enucleation of the cystic tumor with curettage and possible “bone burring” deemed adequate. Unicystic lesions treated less aggressively have recurrence rates of ~5%^[3]. For plexiform variant, recurrence rate after enucleation alone is the highest (30.5%), while resection results in the lowest recurrence rate (3.6%)^[14]. In our case, radical resection approach was considered to avoid the chances of recurrence as the lesion was extensively large in size and plexiform pattern was also present histologically.

Conclusion

The clinical differential diagnostic consideration for unicystic lesions includes benign odontogenic cysts and neoplasms. Hence the chances of treating the lesion conservatively with enucleation are more. However, this misdiagnosis increases the chances of complications and recurrence. Unicystic lesions treated less aggressively have recurrence rates of 5%. In order to avoid this we would like to emphasize the importance of clinico-radiological and pathological correlation of all lesions mimicking odontogenic cyst prior to the treatment plan.

References

1. Robinson L, Martinez M. Unicystic ameloblastoma. A prognostically distinct entity. *Cancer*. 1977;40(5):2278–2285.
2. Brazis PW, Miller NR, Lee AG, Holliday MJ. Neuro-ophthalmologic Aspects of Ameloblastoma. *Skull Base Surg*. 1995;5(04):233–44.
3. Thomson LDR, Goldblum JR. *Head and neck pathology*. 2nd ed, Elsevier: Saunders; 2013:360-366.
4. Becelli R, Carboni A, Cerulli G, Perugini M, Iannetti G. Mandibular ameloblastoma: Analysis of surgical treatment carried out in 60 patients between 1977 and 1998. *J Craniofac Surg*. 2002;13(3):95–400.
5. Gnepp DR. *Diagnosic surgical pathology of the head and neck*. 2nd ed, Elsevier: Saunders; 2009:802-810.
6. Wenig BM. *Atlas of head and neck pathology*. 2nd ed, Elsevier: Saunders; 2008:313-319.
7. Ackermann GL, Altini M, Shear M. The unicystic ameloblastoma: A clinicopathological study of 57 cases. *J Oral Pathol Med*. 1988;17(9-10):541–546.
8. Philipsen HP, Reichart PA. Unicystic ameloblastoma. A review of 193 cases from the literature. *Oral Oncology* 1998;34(5):317–325.
9. Nasti AL, Wiesenfeld D, Radden B, Eveson J, Scully C. Maxillary ameloblastoma: A retrospective study of 13 cases. *Br J Oral Maxillofac Surg*. 1995;33(1):28-32.
10. Coleman H, Altini M, Ali H. Use of calretinin in the differential diagnosis of unicystic ameloblastomas. *Histopathology*. 2001;38:312-317.
11. Li TJ, Browne RM, Matthews JB. Expression of proliferating cell nuclear antigen (PCNA) and Ki-67 in unicystic ameloblastoma. *Histopathology*. 1995;26(3):219–228.

12. Li TJ, Browne RM, Matthews JB. Epithelial cell proliferation in odontogenic keratocysts: a comparative immunocytochemical study of Ki67 in simple, recurrent and basal cell naevus syndrome (BCNS)-associated lesions. *J Oral Pathol Med.* 1995;24(5):221–226.
13. Saku T, Shibata Y, Koyama Z, Cheng J, Okabe H, and Yeh Y. Lectin histochemistry of cystic jaw lesions: an aid for differential diagnosis between cystic ameloblastoma and odontogenic cysts. *J Oral Pathol Med.* 1991;20(3):1991.
14. Lau SL, Samman N. Recurrence related to treatment modalities of unicystic ameloblastoma: a systematic review. *International Journal of Oral and Maxillofacial Surgery.* 2006;35(8):681–690.