

## Primary neuroendocrine carcinoma of the breast

Rupinderjeet Kaur<sup>1,\*</sup>, Puneet Kaur<sup>2</sup>, Jasbir Singh<sup>3</sup>, Monika Bansal<sup>4</sup>

<sup>1</sup>Professor, <sup>2,4</sup>Associate Professor, Gian Sagar Medical College, Rajpura, <sup>3</sup>Professor, MM Medical College, Solan, Haryana

**\*Corresponding Author:**

Email: giansagar\_rupinder@yahoo.co.in

### Abstract

**Background:** Neuroendocrine carcinoma of the breast is a rare entity. Most patients are in the sixth to seventh decade of life. The criteria for diagnosis were established by the WHO in 2003, and modified in 2013. Based on the limited number of studies done; this entity is thought to have a worse prognosis compared to the usual type of intraductal carcinoma.

**Case Report:** A 45 year old woman presented in the surgical outpatient department with complaint of lump breast. Fine needle aspiration was performed and the case was reported as suspicious of malignancy. Biopsy was advised for further evaluation. Histopathology showed a cellular tumor exhibiting a sheeting pattern with interspersed rosettes. The individual cells were relatively monomorphic, with a salt and pepper chromatin. Intraductal component was also identified. Based on the characteristic morphology and presence of chromogranin positivity in more than 50% of the tumor cells, the lump was diagnosed as primary neuroendocrine carcinoma, well differentiated.

**Conclusion:** This case has been written up because of the rarity of this entity, its characteristic histopathological features, and the importance of differentiating it from intraductal carcinoma, due to a more aggressive course than invasive ductal carcinoma, with a higher propensity for local and distant recurrence and poorer overall survival attributed to this entity by some researchers.

**Keywords:** Breast, Chromogranin, Neuroendocrine carcinoma, Primary, Prognosis

Access this article online	
Quick Response Code:	Website: www.innovativepublication.com
	DOI: 10.5958/2394-6792.2016.00095.8

### Introduction

Primary neuroendocrine carcinoma of the breast constitutes 0.1% of all breast cancers and less than 1% of all neuroendocrine tumors<sup>(1)</sup>. According to the WHO, these tumors are similar morphologically to neuroendocrine tumors of both the gastrointestinal tract and the lung<sup>(2)</sup>. They remain under recognised because they are difficult to diagnose, because of the fact that they mimic common histological subtypes of carcinoma breast.

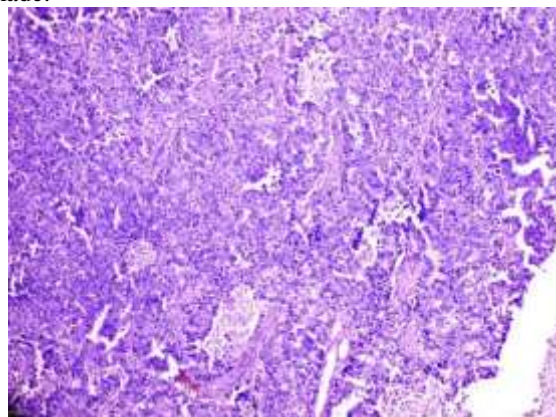
### Case Report

A 45 year old woman presented to the surgery OPD with a lump in the left breast which measured around 5 cm in diameter. It was hard and immobile, but the overlying skin was free. FNA was reported as suspicious of malignancy, and histopathology was advised. Radical mastectomy was done along with level 2 axillary clearance and the specimen was sent to the Pathology Department for histopathological examination.

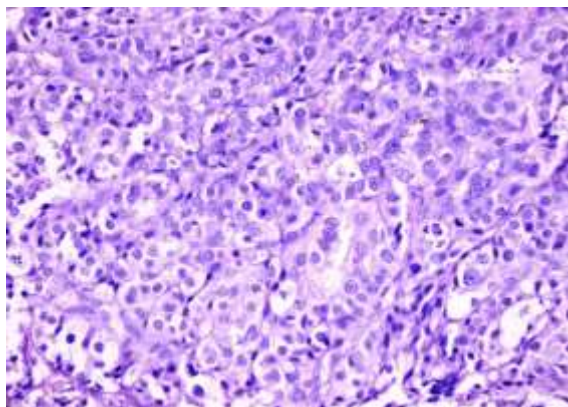
Multiple sections taken showed a densely cellular tumor present as solid sheets and trabeculae of cells having round to oval monomorphic nuclei, stippled chromatin and eosinophilic cytoplasm. At some places,

tumour cells appeared to be polarized around lumina, forming rosettes. Mitotic activity was rare. Intra ductal tumor component was also identified. The axillary nodes showed reactive hyperplasia. The tumor was accorded a score of 5, and a grade 2 (well differentiated), as per the Modified Bloom –Richardson grading system.

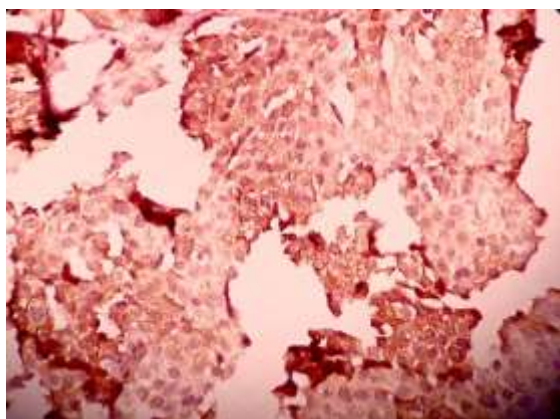
Based on the morphological features, a suspicion of neuroendocrine differentiation in the tumor was aroused. Immunohistochemistry was done from an outside lab, and revealed cytoplasmic positivity for Chromogranin in more than half of the tumor cells, which confirmed presence of neuroendocrine differentiation in the tumor. ER and PR were negative, but Her2neu was positive. A whole body CT also showed the rest of the organs to be unremarkable. In accordance with the morphological and immunohistochemical findings, a diagnosis of primary neuroendocrine carcinoma, well differentiated, was made.



**Fig. 1: Low power view showing sheeting pattern of cells, with interspersed rosettes**



**Fig. 2: High power view showing monomorphic nuclei, stippled chromatin and eosinophilic cytoplasm**



**Fig. 3: A high power view of the chromogranin immunostain done on a section of the breast tumor, showing cytoplasmic positivity in more than 50% of the cells.(DAB x 400)**

## Discussion

Feyrter et al originally described Neuroendocrine carcinoma breast in 1963, on finding that many cases of invasive breast cancer had a growth pattern akin to carcinoids.<sup>(3)</sup> Another series of cases of carcinoma breast having similar features was described in 1977 by Cubilla and Woodruff<sup>(4)</sup>. However, criteria for mammary NEC were established in 2003 by the World Health Organization classification of Tumors, when they defined NECs of the breast as having >50% neoplastic cells expressing neuroendocrine (NE) markers<sup>(2)</sup>. They also made fulfilment of two other criteria mandatory for diagnosis:

1. exclusion of other primary sites<sup>(4)</sup>,
2. evidence of an in situ component<sup>(5)</sup>

As a modification to these criteria, these tumours were classified into three categories in 2012 by the WHO: Neuroendocrine tumor, well-differentiated; poorly differentiated neuroendocrine carcinoma/ small cell carcinoma, and invasive breast carcinoma with neuroendocrine differentiation<sup>(6)</sup>. There is resemblance of the neuroendocrine component of the breast tumour

with neuroendocrine neoplasms of the lungs and gastrointestinal tract. It is characterized by monomorphic cells; nuclear palisading and pseudo-rosette formation. The individual cells have stippled, salt and pepper chromatin and abundant eosinophilic cytoplasm.<sup>(7,8)</sup>

In our case, characteristic arrangement and appearance of tumor cells, presence of an intraductal tumor component, which confirms the breast as primary site of malignancy, and greater than 50% positivity for Chromogranin enabled us to arrive at the diagnosis of well differentiated neuroendocrine carcinoma. The prognosis of neuroendocrine carcinoma is thought to be worse than invasive mammary carcinoma, not otherwise specified<sup>(9,10)</sup>. Hence, identification of this entity and its differentiation from invasive carcinoma, no special type, is important.

## References

1. Ogawa H, Nishio A, Satake H, Naganawa S, Imai T, Sawaki M, et al. Neuroendocrine tumor in the breast. *Radiat Med*2008;26:28.
2. Ellis IO, Schnitt SJ, Satre-Garau X. Invasive breast carcinoma. In: Tavassoli FA, Devilee P, editors. World health organization classification of tumors. Pathology and genetics of the tumors of the breast and female genital organs. Lyon: IARC press; 2003.p.13.
3. Feyrter F, Hartmann G. On the carcinoid growth form of the carcinoma mammae, especially the carcinoma solidum(Gelatinosum) mammae. *Frankf Z Pathol*.1963;73.
4. Cubilla AL, Woodruff JM: Primary carcinoid tumor of the breast: a report of eight patients. *Am Surg Pathol* 1977;1:283.
5. Kinoshita S, Hirano A, Komine K, Kobayashi S, Takeyama H, Uchida K, Morikawa T, Nagase J, Sakamoto G. Primary small- cell neuroendocrine carcinoma of the breast: report of a case. *Surg Today*2008;38:734.
6. Bussolati G, Badve S. Carcinoma with neuroendocrine features. In: Lakhani S, Ellis IO, Schnitt SJ, Tan PH. World Health Organization classification of tumors. Pathology and genetics of the tumors of the breast and female genital organs. Lyon: IARC press; 2012.p.62.
7. Miura K, Nasu H, Ogura H. double neuroendocrine ductal carcinomas in situ, coexisting with a background of diffuse idiopathic neuroendocrine cell hyperplasia of breast: a case report and hypothesis of neuroendocrine tumor development. *Pathol Interl* 2012;62:331.
8. Tang F, Wei B, Tiaz Z et al. Invasive carcinoma with neuroendocrine differentiation: histological features and diagnostic challenges. *Histopathology* 2011;59:106.
9. Zhang Z, Chen Z, Bao Y et al. Invasive neuroendocrine carcinoma of the breast: a prognostic research of 107 Chinese patients. *Noplasma* 2013;60:215.
10. Tian Z, Wei B, Tang F et al. Prognostic significance of tumor grading and staging in mammary carcinomas with neuroendocrine differentiation. *Hum Path* 2011;42:1169.