

## Diagnostic role of FNAC in Salivary gland lesions and its histopathological correlation

Tushar Kambale<sup>1</sup>, Banyameen Iqbal<sup>2,\*</sup>, Amardeep Patil<sup>3</sup>, Harsh Kumar<sup>4</sup>

<sup>1,2</sup>Associate Professor, <sup>3</sup>Resident, <sup>4</sup>Professor & HOD, Dept. of Pathology, Dr. D.Y. Patil Medical College, Hospital & Research Centre, Pune

**\*Corresponding Author:**

Email: banzey@gmail.com

### Abstract

**Background:** Fine needle aspiration cytology (FNAC) is the established first line investigation of mass lesions in the body. Kun was the first to describe the diagnostic use of FNAC in 1847. About 2-6.5% of all head and neck region neoplasm in adults are from salivary glands which are usually accessible for FNAC. It helps to distinguish salivary glands lesion as inflammatory, benign and malignant hence allowing proper planning for management.

**Material and Methods:** It was a retrospective study carried for the period of Feb 2014 to Feb 2016. 68 cases of salivary gland swelling were included in which cytological and histological studies were done. 22 cases were excluded from the study on view of inadequate material or lack of either FNAC or histology correlation. All the patients were clinically evaluated and FNAC was done using 10 ml disposable syringe and 23/24-gauge needle without using local anesthesia. We classified our FNAC results as true-negative, true-positive, false-negative and false-positive. We also compared the histopathology of the surgical specimens and cytology of the FNAC specimens and evaluated the sensitivity, specificity, positive predictive value (PPV), negative predictive value (NPV).

**Results:** Parotid gland was commonest affected site. Out of 46 neoplastic lesions 39 (84.7%) were benign and 07 (15.3%) were malignant. An overall of 86.9% (40/46) concordance between FNAC and final histological diagnosis was established. A sensitivity of 97.4% and specificity was 71.4%, were observed with 93.4 % of accuracy. The positive and negative predictive values were 95% and 83.3%, respectively.

**Conclusion:** FNAC is a safe and accurate diagnostic tool. Surgeon can plan treatment according the preoperative FNAC diagnosis and avoid unnecessary surgeries.

**Keywords:** Cytology, FNAC, Parotid gland

Access this article online	
<b>Quick Response Code:</b> 	<b>Website:</b> www.innovativepublication.com
	<b>DOI:</b> 10.5958/2394-6792.2016.00070.3

### Introduction

The diagnostic use of needle aspiration technique as a new instrument was first described in 1847 by Kun. After that in the United Kingdom in 1927 Dudgeon and Patrick used it as a means of rapid microscopic diagnosis but in 1933 Stewart analyzed 2500 tumors by aspiration cytology and mentioned the points which still form the core of knowledge that must be acquired to ensure the correct and successful application of needle aspiration cytology. Fine needle aspiration cytology (FNAC) is now established as the first line investigation of mass lesions in the body.<sup>[1-3]</sup>

About 2-6.5% of all head and neck region neoplasm in adults are from salivary glands which are usually accessible for FNAC. This procedure will avoid incisional biopsy and the risks of fistula formation, or tumour implantation in case of neoplasms.<sup>[4-5]</sup> However, some authors have the opinion that pre-operative FNAC

has little influence on the clinical management since most of the masses ultimately require surgery<sup>[6]</sup>.

Due to the distinct morphology of salivary glands, FNAC helps to distinguish salivary glands lesion as inflammatory, benign and malignant hence allowing proper planning for management. If the pathology is known it is easy to counsel the patient and plan surgery if necessary.

This retrospective study evaluated and analyzed salivary gland lesions by FNAC and correlated the cytologic findings with histopathology.

### Materials and Methods

Present study was carried out in the Department of Pathology in a tertiary care hospital retrospectively during the period of Feb 2014 to Feb 2016. In the present study, 68 cases of salivary gland swelling were included in which cytological and histological studies were done. Three cases were having scant or inadequate aspirate on FNAC and 19 cases were having either cytology or histology reports available and were excluded from the study. Thus only 46 cases were included in this study and cytohistological correlation was made. All patients were clinically evaluated by detailed history, clinical examination, and hematological and radiological investigations. FNAC was performed from different sites of the salivary gland

swelling using a 10 ml disposable syringe and 23/24-gauge needle without local anesthesia. FNAC air-dried smears were stained with Leishman stain and wet smears fixed in 95% ethyl alcohol were stained with either Papanicolaou stain or Hematoxylin and Eosin stain.

We classified our FNAC results as true-negative, means absence of malignancy and correctly diagnosed, true-positive means presence of malignancy and correctly diagnosed, false-negative means cytological specimen failed to diagnose a malignancy and false-positive means cytological specimen was incorrectly considered or suspected for malignancy.

We also compared the histopathology of the surgical specimens and cytology of the FNAC specimens and evaluated the sensitivity, specificity, positive predictive value (PPV), negative predictive value (NPV), and overall accuracy of FNAC to differentiate between benign and malignant disease.

### Results

The study included 46 cases of salivary gland neoplasms ranging from 1-91 years, out of which 26 (56.5%) were males and 20 (43.5%) were female with an overall male predominance. Out of 46 neoplastic lesions 39 (84.7%) were benign and 07 (15.3%) were malignant. Benign neoplasms outnumbered the malignant neoplasms. In general parotid gland was commonest affected site. In this series 34 (73.9%) patient had parotid, 6 (13.05%) had submandibular, 6 (13.05%) sublingual and minor salivary gland tumors. Pleomorphic adenoma was the most common in benign tumor group 23 (50%) cases. [Table 1 and 2] [Fig. 1]

An overall of 86.9% (40/46) concordance between FNAC and final histological diagnosis was established. The cytological diagnosis was true positive for

malignancy in 5 (10.86%) cases and true negative in 38 (82.6%) cases. Five of the 5 (100%) true-positive neoplasms and 35 of the 38 (92.1%) true-negative benign lesions were determined as accurate results. There was 1 (2.1%) false positive and 2 (4.3%) false negative results. [Tables 3, 4 and 5]

A statistical analysis of 46 cases was carried out to assess the diagnostic accuracy of salivary glands FNAC compared with that of histological results [Table 6]. A sensitivity of 97.4% and specificity was 71.4%, were observed with 93.4% of accuracy. The positive and negative predictive values were 95% and 83.3%, respectively.

No complication such as local inflammation, hematoma, infection, or facial nerve damage was observed.

**Table 1: Showing various histopathology diagnosis**

Histopathology diagnosis	Number of cases and percentage
Pleomorphic adenoma	20 (43.4%)
Warthin's tumor	3 (6.5%)
Sialadenitis	7 (15.2%)
Basal cell adenoma	1 (2.17%)
Myoepithelioma	1 (2.17%)
Cyst	6 (13%)
Kimuras Disease	1 (2.17%)
Mucoepidermoid carcinoma	2 (4.34%)
Metastasis of Squamous cell carcinoma	2 (4.34%)
Adenoid cystic carcinoma	2 (4.34%)
Carcinoma ex Pleomorphic adenoma	1 (2.17%)
Total	46 (100%)

**Table 2: Showing histopathology diagnosis & cytology discordance**

Benign	Histopathology diagnosis	Cytology discordance
Pleomorphic adenoma	20 (43.4%)	3 (6.5%)
Warthin's tumor	3 (6.5%)	
Sialadenitis	7 (15.2%)	1 (2.17%)
Basal cell adenoma	1 (2.17%)	
Myoepithelioma	1 (2.17%)	
Cyst	6 (13%)	1 (2.17%)
Kimuras Disease	1 (2.17%)	
Total Benign	39 (84.78%)	5 (10.86%)
Malignant		
Mucoepidermoid carcinoma	2 (4.34%)	1 (2.17%)
Metastasis of Squamous cell carcinoma	2 (4.34%)	
Adenoid cystic carcinoma	2 (4.34%)	
Carcinoma ex Pleomorphic adenoma	1 (2.17%)	
Total Malignant	7 (15.22%)	1 (2.17%)

**Table 3: Showing true-positive cases with accurate & inaccurate results (n=05)**

Accurate [n=05]		Inaccurate [n=02]	
Cytology	Histopathology	Cytology	Histopathology
2 Squamous cell Ca	2 Squamous cell Ca	-	-
2 Mucoepidermoid Ca	2 Mucoepidermoid Ca	-	-
1 Adenoid Cystic Ca	1 Adenoid Cystic Ca		

**Table 4: Showing True-negative cases with accurate and inaccurate results (n=38)**

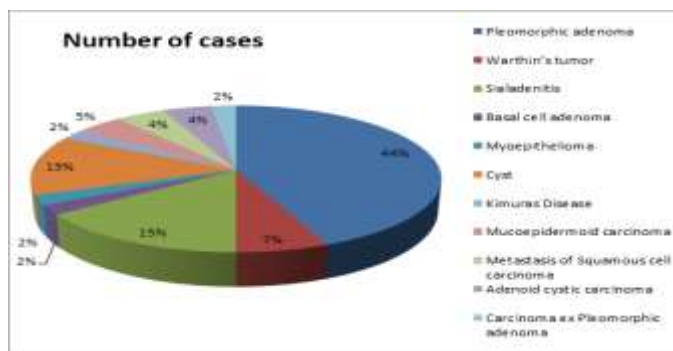
Accurate [n=35]		Inaccurate [n=03]	
Cytology	Histopathology	Cytology	Histopathology
20 Pleomorphic adenoma	20 Pleomorphic adenoma	1 Warthins Tumor	1 Kimras Disease
1 Warthins Tumor	1 Warthins Tumor	1 Warthins Tumor	1 Sialadenitis
7 Sialadenitis	7 Sialadenitis	1 Cystic Lesions	1 Sialadenitis
6 Cystic Lesions	6 Cystic Lesions		
1 Basal Cell adenoma	1 Basal Cell adenoma		

**Table 5: Table showing False Positive & False Negative results**

False-negative (n = 5)		False-positive (n = 2)	
Cytology	Histopathology	Cytology	Histopathology
1 Pleomorphic adenoma	1 Carcinoma ex Pleomorphic adenoma	1 Mucoepidermal Ca	Myoepithelioma
1 Cystic Lesion	1 Adenoid cystic Ca		

**Table 6: Comparison of histological results in 129 cases with**

FNAC diagnosis	Histological diagnosis		
	Benign	Malignant	Total
Benign	38TN	02 FN	40
Malignant	01FP	05 TP	06
	39	07	46



**Fig. 1: Pie chart showing percentage of different salivary gland lesions**

**Discussion**

The FNAC has been widely used as a diagnostic tool for the management of various head and neck lesions. It is accurate, safe and a superior modality.<sup>[7,8,9,10]</sup>

In the present study, 3<sup>rd</sup> and 4<sup>th</sup> decade age group had more cases and male preponderance was observed which was 1.3:1 but in other studies females were outnumbered.<sup>[10]</sup> Parotid gland was involved in 73.9%

cases and is comparable with other studies. There were 39 (84.7%) benign cases and 7 (15.3%) malignant cases these incidence were also comparable to other studies.<sup>[11,12,13,14]</sup>

23 out of 46 (50%) cases diagnosed as pleomorphic adenoma on FNAC, 20 out of 46 (43.5%) were correctly confirmed by histopathology and remaining three case were carcinoma ex pleomorphic adenoma, sialadenitis and Warthins tumor. These diagnostic

errors might be due to sampling from non-representative areas with inflammation and metaplastic changes. FNAC smears from pleomorphic adenoma shows epithelial and spindle-shaped cells with chondromyxoid ground substance in background. This is similar to other studies as 50% and 21.6% cases were of pleomorphic adenoma.<sup>[12,13]</sup>

There were 5 out of 8 cases of sialadenitis which were confirmed on histopathology, while 2 cases of sialadenitis were conformed as Warthins tumor and one was cystic lesion on histopathology. Similarly 5 out of 7 cases of Cystic lesion were confirmed on histopathology while 1 case was sialadenitis and another turn out to be adenoid cystic carcinoma. In present study cyto-histological correlation of for chronic sialadenitis was 62.5% compared to 90% and 81.8% in other studies.<sup>[14,19]</sup>

The diagnostic sensitivity of FNAC in detecting malignant disease was 97.4% and specificity was 71.1%. This wide range of sensitivity and specificity reported in various studies, from as low as 27% up to 97% and 84% to 100% can be because of variation in skills to perform FNAC and expertise of the Pathologist to assess the specimen<sup>[15-18]</sup>. Sampling error can lead to increase number of false negative and false positive FNAC results and decrease in diagnostic accuracy. In our study there were 2 (4.34%) false negative cases that is carcinoma ex pleomorphic adenoma and adenocystic carcinoma and 1 (2.17%) false positive case of myoepithelioma. These cases have varied complex and overlapping morphological features which make the diagnosis difficult.

## Conclusion

It can be concluded from our study that FNAC is a safe and accurate diagnostic tool. Surgeon can plan the treatment according the preoperative FNAC diagnosis and avoid unnecessary surgeries in cases where surgery is not required and also extend the treatment plan when the diagnosis of malignancy is made.

## References

- Griegg EDW, Gray ACH. Note on the lymphatic gland in sleeping sickness. *Lancet* 1904;i:1570.
- Dudgeon LS, Patrick CV. A new method for the rapid microscopical diagnosis of tumours. *Br J Surg* 1927;15: 250-61.
- Stewart F. The diagnosis of tumours by aspiration. *Am J Pathol* 1933;9:801-12.
- Cristallinin EG, Ascani S. Fine Needle aspiration biopsy of salivary gland. *ActaCytol*;41:1421-1425.
- Chatterjee T, Panda PK. Pathological study of benign and malignant tumours of salivary glands, *MJAFI* 2000;56:282-86.
- Batsakis JG, Sneige N, El-Naggar AL, Fine needle aspiration in salivary glands: its utility and tissue effects, *Annals of Otolaryngology and Rhinology and Laryngology*1992;101:185-88.
- Atula T, Gr'enman R, Laippala P, Klemi PJ, Fine needle aspiration biopsy in the diagnosis of parotid gland lesions: evaluation of 438 biopsies, *Diagnostic Cytopathology* 1996;15:185-90.
- Frable MAS and W. J. Frable WJ, Fine-needle aspiration biopsy revisited, *Laryngoscope* 1982;92:1414-18.
- Lussier C, Klijanienko J, Vielh P, Fine-needle aspiration of metastatic nonlymphomatous tumors to the major salivary glands: a clinicopathologic study of 40 cases cytologically diagnosed and histologically correlated, *Cancer* 2000;90:350-56.
- Singh N, Mehdratta KS, Satyanand. Study of salivary gland tumors. *Indian Journal of Surgery* 1968;193-206.
- Sousa J, Oswald DS, Salivary Gland tumors: an analysis of 62 cases. *Ind J of Cancer*; 2001;38:38- 45.
- Cristallinin EG, Ascani S. Fine Needle aspiration biopsy of salivary gland. *Acta Cytol*;41:1421-25.
- Cajulis RS, Gokaslan ST. Fine needle aspiration biopsy of the salivary glands. *Acta Cytol*;1997:1412-19.
- Khandekar MM, Kavatkar AN, Patankar SA, Bagwan IB, Puranik SC, Deshmukh SD, FNAC of salivary gland lesions with histopathological correlation. *Indian Journal of Otolaryngology and Head and Neck Surgery* 2006;58:246-48.
- Zurrida S, Alasio L, Tradati N, Bartoli C, Chiesa F, Pilotti S, Fine needle aspiration of parotid masses *Cancer*1993;72:2306-11.
- Wong DSY, Li GKH, The role of fine-needle aspiration cytology in the management of parotid tumors: a critical clinical appraisal, *Head and Neck* 2000;22:469-73.
- JayaramG, Verma AK, Sood N, Khurana N. Fine needle aspiration cytology of salivary gland lesions. *Journal of Oral Pathology and Medicine* 1994;23:256-61.
- QueHee CG, Perry CF, Fine-needle aspiration cytology of parotid tumors: is it useful? *ANZ Journal of Surgery* 2001;71:345-48.
- Klijanienko J. Vielh P. Salivary gland tumours. In: Orell SR. *Monographs in clinical cytology*;2000:15.