

Content available at: <https://www.ipinnovative.com/open-access-journals>

Indian Journal of Pathology and Oncology

Journal homepage: www.ijpo.co.in

Original Research Article

Studies of malignant & non-malignant lung lesions detected by USG guided FNAC in the Saurashtra region

Jaysukhkumar Berani^{1*}, J D Dalsania¹, Gauravi Dhruva¹

¹Dept. of Pathology, P.D.U. Medical College, Rajkot, Gujarat, India



ARTICLE INFO

Article history:

Received 31-07-2024

Accepted 02-09-2024

Available online 12-09-2024

Keywords:

USG guided FNAC

Lung neoplasms

Non- small cell lung carcinoma

Small cell lung carcinoma

Adenocarcinoma

ABSTRACT

Background: USG Guided fine needle aspiration cytology (FNAC) is a minimally invasive procedure used to obtain cellular samples from lung lesions for diagnostic purposes. With the help of ultrasound (USG) accurately guide the needle to the target area, ensuring precise and effective sampling. It is safe, less traumatic, quick and cost-effective tool being minimally invasive & excellent patient's compliance.

Aim: Studies of Malignant & Non-malignant Lung Lesions Detected by USG Guided FNAC.

Materials and Methods: 58 patients come for USG Guided FNAC to P.D.U. hospital was studied in the duration of year November 2021- October 2022.

Result: Out of 58 cases 79.31% were male. Maximum case present in quinquagenarian age group. 67.24% having malignant lesions and 25.86% have non-malignant lesions, 8.62% was inconclusive aspirated. Squamous cell carcinoma was identified as the most common malignant tumor.

Conclusion: USG Guided FNAC provides a reliable diagnosis of pulmonary lesions, reducing morbidity and mortality, and allowing for early initiation of treatment.

This is an Open Access (OA) journal, and articles are distributed under the terms of the [Creative Commons Attribution-NonCommercial-ShareAlike 4.0 License](https://creativecommons.org/licenses/by-nc-sa/4.0/), which allows others to remix, tweak, and build upon the work non-commercially, as long as appropriate credit is given and the new creations are licensed under the identical terms.

For reprints contact: reprint@ipinnovative.com

1. Introduction

USG Guided fine needle aspiration cytology (FNAC) is a pivotal diagnostic tool for evaluating both malignant and non-malignant lung lesions. This minimally invasive procedure by using ultrasound accurately guide a fine needle to the targeted lung lesion.^{1,2} FNAC is particularly valuable in distinguishing between benign conditions, such as inflammatory or infectious lesions, and malignant entities, including various types of lung carcinoma. By obtaining cellular samples from the lesion, FNAC provides crucial diagnostic information, aiding in appropriate treatment planning and management. Its precision and effectiveness make it an essential component in the diagnostic workup of lung lesions.^{3,4} Peripheral lesions, where bronchoscopic brush and lavage preparation is not useful, FNAC is very

much useful.⁵

2. Materials and Methods

A study was conducted in the Pathology Department of P.D.U. Medical College & Hospital. Over the course of a year, from November 2021 to October 2022, data from 58 patients undergoing USG Guided FNAC at P.D.U. Hospital were analyzed. Most cases referred to our institute originated from the clinical departments, specifically the respiratory medicine ward. USG Guided FNAC was performed following an explanation of risks and benefits and obtaining informed written consent from each patient. FNAC was carried out using a 22–24-gauge needle with a 10 ml syringe for superficial masses and a 9-cm, 20–22-gauge spinal needle for deeper lesions. The glass slides with spread material were immediately fixed in 95% alcohol for H&E staining and mounted in DPX. Some slides with

* Corresponding author.

E-mail address: jbberani314@gmail.com (J. Berani).

air-dried material were also prepared for MGG staining. Post-procedure pneumothorax was closely monitored by a respiratory medicine doctor at the procedure site to ensure prompt management and patient safety.

3. Result

Fine Needle Aspiration Cytology (FNAC) was performed under USG guidance. Out of 58 patients, 5 required a repeat FNAC. A definitive diagnosis was achieved in 54 cases. Patient ages ranged from 30 to 90 years, with the majority presenting symptoms in their 50s (44.83%) and 60s (29.31%). The youngest patient diagnosed with bronchogenic carcinoma was 39 years old. No cases were reported in the below 20-year age groups during this study.

Table 1: Age distribution and incidence of lung lesions

Age Range	Number of patients	Percentage (%)
30-39	1	1.72
40-49	6	10.34
50-59	26	44.83
60-69	17	29.31
70-79	7	12.07
80-89	1	1.72
Total	58	100

Males comprised the majority of patients presenting with signs and symptoms, with an incidence rate of 79.31%.

Female patients had an incidence rate of 20.68%, leading to a male-to-female ratio of 3.8:1.

Table 2: Lung lesion & smoking habit (58 cases)

Smoking habit	Gender	No. of patients	Malignancy present
Present (47)	Male	44/46	34
	Female	03/12	02
Absent (11)	Male	02/46	01
	Female	09/12	01
Total		58/58	38

Out of 46 male patients 38 patients had given positive history for smoking which is showing incidence rate of 82.60% and out of 12 female patients 2 patients were giving positive history for smoking (16.66%). 83.33% of female subjects were non-smoker and 17.40% of male subjects were non-smoker. Out of 46 male 38 were smoker and malignancy were diagnosed in 33 cases. Out of 12 female 02 were smoker and malignancy were diagnosed in 01 cases.

Majority of the patients had presented with chief complain of cough (77.59%), Chest Pain (44.83%) and followed by weight loss (32.76%), anorexia (31.03%), expectorant (17.24%), anorexia (31.03%) along with others 20.69% case was a history of TB. In the above-mentioned table only one main presenting symptom of the patient

Table 3: Symptomatology & lung lesions

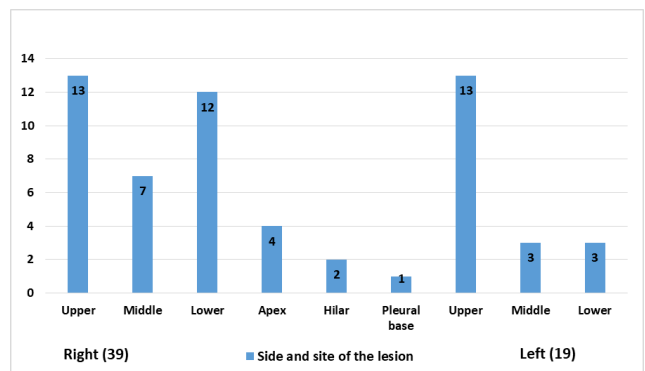
Presenting symptoms	No. of patients	Percentage (%)
Chest pain	26	44.83
Cough	45	77.59
Expectorant	10	17.24
Breathless ness	15	25.86
Weight loss	19	32.76
Fever	16	27.59
Anorexia	18	31.03
Hemoptysis	6	10.34
History of tb	12	20.69

has been considered. Patients were having associated other symptoms also.

Table 4: Mode of clinical presentation

Clinical presentation	No. of patients	Percentage (%)
Consolidation	19	32.76
Mass	13	22.41
Pleural effusion	6	10.34
Cavity	15	25.86
Svc obstruction	2	3.45
Multiple pulmonary Nodules	2	3.45
Horner syndrome	1	1.72
Total	58	100

Majority of the patients had presented with consolidation & mass lesion which was found in 19 & 13 respectively patients out of 48 patients. Cavitory lesions were found in 15 patients among which only one case was diagnosed as Horner syndrome, Pleural effusion was noted in 06 patients out of which 04 patients were having associated malignant lesion whereas only one patient was diagnosed as tuberculosis was having cavity.



Graph 1: Distribution showing side and site of the lesions (58 Cases)

Lesions were more localized on Right side of Lung (39 patients) compared to Left side (19 patients) in the present

study. Upper & Middle zone (26&10 respectively) lesions were more on both sides than lower zone (15 patients) lesions.

Table 5: Showing transthoracic FNAC results

FNAC Results		
Cytological Diagnosis	No. of patients	Percentage (%)
Malignant Lesion	43	74.14
Squamous Cell Carcinoma of lung	21	36.2
Adenocarcinoma of Lung	15	25.86
1. Large Cell Lung Carcinoma	01	1.72
Small Cell Lung Carcinoma (SCLC)	01	1.72
Carcinoid tumor (Neuroendocrine Tumor)	01	1.72
Metastatic	04	6.89
Non-Malignant Lesion	15	25.86
Inflamed Cystic Lesion	01	1.72
Inflammatory lung lesion	11	18.96
2. Fungal Inflammation	01	1.72
Tuberculosis	01	1.72
Necrosis	01	1.72
Total	58	100

Out of the 58 cases, A malignancy was identified in 43 cases: 21 patients were diagnosed with the highest incidence being squamous cell carcinoma (36.20%). Adenocarcinoma was detected in 15 patients (35.86%), while 1 patient had large cell carcinoma one had small cell carcinoma and one had carcinoid tumor. Among non-malignant lesions, there was 1 inflamed cystic lesion, 11 cases of inflammatory lung lesions, 1 case of tuberculosis, and 1 case of fungal inflammation.

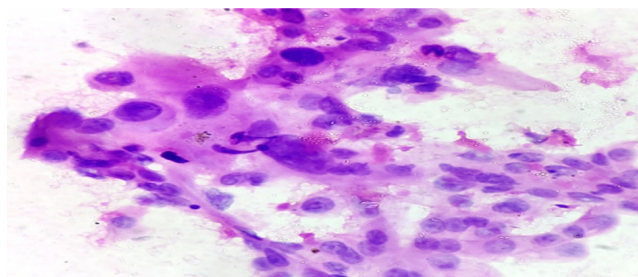


Figure 1: Squamous cell carcinoma demonstrating high N:C Ratio and Hyperchromatic Nuclei (H & E, 40X).

4. Discussion

Fine Needle Aspiration Cytology is a reliable and precise method for diagnosing and categorizing benign, malignant, and inflammatory lesions, and it is a well-established diagnostic procedure for both primary and secondary lung carcinomas.

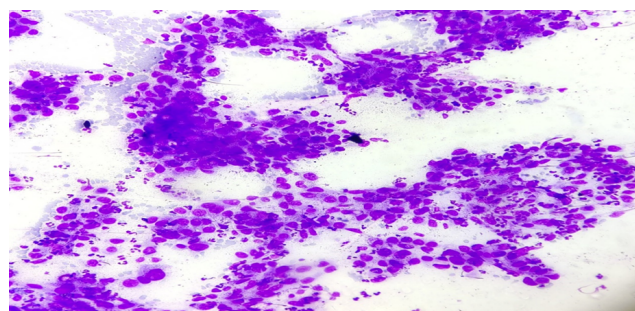


Figure 2: Adenocarcinoma showing glandular cell clusters with intranuclear cytoplasmic inclusions (Giemsa Stain, 10X)

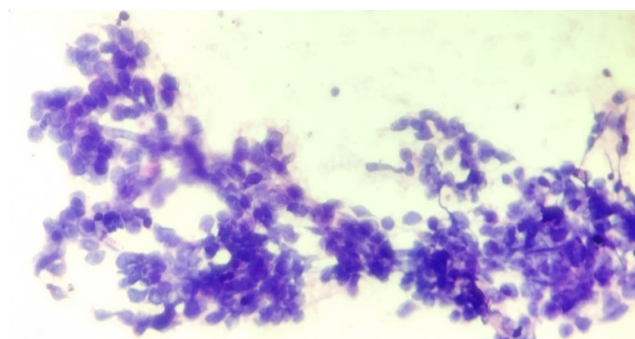


Figure 3: Small cell lung carcinoma exhibiting small clusters with minimal cytoplasm, finely granular chromatin, and nuclear molding (H & E, 40X)

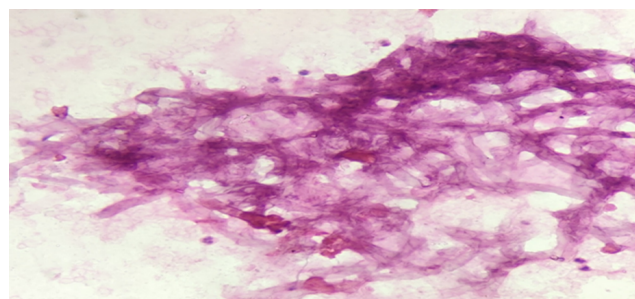


Figure 4: Aspergillosis in lung highlighting hyphae branching at 45 degrees (H & E, 40X)

Table 6: Comparison of age predilection in various studies

S. No.	Author	Year	No. of cases	Age range (year)
1	Bhattacharya et al ⁶	2011	266	41-60
2	Patel et al ⁷	2013	50	51-70
3	Mukherjee et al ⁸	2016	90	40-70
4	Jalpa et al ⁹	2018	138	51-60
5	Present Study	2022	58	50-69

Table 7: Comparative analysis of cytological diagnosis lung lesions

Author	Malignant Lesion(%)						Non-Malignant Lesions (%)
	SqCC (%)	Adeno (%)	SmCC (%)	LCC (%)	Mets (%)	NET (%)	
Upal et al ¹⁰ [2005]	49.43	34.48	11.54	3.45	1.15	0	7.27
Bhattacharya et al ⁶ [2011]	35.34	15.79	13.91	1.88	0	0	0
Patel et al ⁷ [2013]	39.39	21.21	13.63	7.57	0	0	0
Jalpa et al ⁹ [2018]	41.3	15.95	3.62	0.72	0	72	11.6
Present Study	36.2	25.86	1.72	1.72	6.89	1.72	25.86

Abbreviations: 1 SqCC: Squamous Cell Carcinoma, Adeno: Adenocarcinoma, SmCC: Small Cell Carcinoma, LCC: Large Cell Carcinoma, NET: Neuroendocrine Tumor, Mets.(Metastatic)

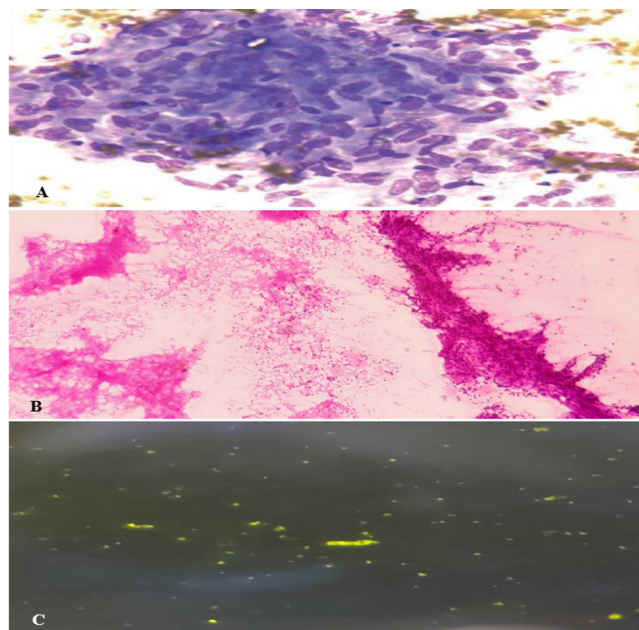


Figure 5: A): Epithelioid Granuloma, B): Caseation in FNAC, C): Acid-Fast Bacilli Stained with Auramine-Rhodamine (H & E, 40X; Auramine-Rhodamine, 100X)

Studies of FNAC have included all age groups from 8 to 90 years.^{6–9} In the present study, the ages of patients ranged from 21 to 90 years, with pulmonary neoplasms being most prevalent in the 5th and 6th decades (31.03% and 38.79%, respectively). Similar findings were observed by Agarwal et al.¹¹ The male-to-female ratio of 3.8:1 in our study was comparatively higher than in other studies, consistent with the findings of Cristallini et al.¹² (3.8:1) and Gouliamos et al.¹³ (3.6:1)

Among the 97 male patients, 75 were smokers, with malignancy diagnosed in 56 cases. Among the 19 female patients, 5 were smokers, with malignancy diagnosed in 3 cases. The incidence of smoking was 62.06%, comparable to the findings of Bhattacharya et al.⁶ and Jalpa et al.⁹

Most of the lung cancer patients (63.79%) presented with complaints of cough, similar to the findings of Ghosh et al.¹⁴ (71.2%) and Jalpa et al.⁹ (55.8%). In the present study, 58 cases were classified as suspected malignant lesions

[due to the unavailability of IHC (Immunohistochemistry) and molecular diagnostic workups]. Lung cancer were aspirated, with 43 found to be malignant and 15 benign. The most common malignancy was squamous cell carcinoma (36.20%), followed by adenocarcinoma (25.86%), small cell carcinoma (1.72%), and large cell carcinoma (1.72%), and 4 case was suspected of metastatic (6.89%). Which aligns closely with the studies conducted by Upal et al.,¹⁰ Parate et al.,¹⁵ Wallace et al.,¹⁶ and Dahistrom et al.¹⁷

5. Conclusion

With advancements in imaging techniques such as USG guidance, Fine Needle Aspiration Cytology (FNAC) has become a highly effective tool for diagnosing small lung lesions. These imaging modalities enhance the accuracy of FNAC, enabling precise identification of clinically and radiologically suspected lung tumors. Modern cytology benefits from refined cytomorphological criteria, making tumor diagnosis and typing more straightforward. The quality of the material obtained through FNAC facilitates cell block preparation and allows for the application of special stains and markers, further aiding in the confirmation of diagnoses.

6. Source of Funding

None.

7. Conflict of Interest

None.

References

1. Linsk JA, Franzens S. Clinical Aspiration Cytology. 2nd ed. Philadelphia: J.B. Lippincott Co; 1980. p. 85–104.
2. Kline TS. Handbook of Fine Needle Aspiration Biopsy Cytology. 2nd ed. Edinburgh: Churchill Livingstone; 1988.
3. Tao LC, Pearson FG, Delarue NC, Langer B, Sanders DE. Percutaneous fine-needle aspiration biopsy. I. Its value to clinical practice. *Cancer*. 1980;45(6):1480–5.
4. Saunders DE. Current concepts in fine needle aspiration cytology. *Hum Pathol*. 1980;11(2):94–6.

5. Langlois SL, Chryssidis S. Imaging methods for guidance of aspiration cytology. In: Orell SR, Sterrett GF, editors. *Orell, Orell and Sterrett's Fine Needle Aspiration Cytology*. Amsterdam, Netherlands: Elsevier Health Sciences; 2011. p. 28.
6. Bhattacharyya SK, Mandal A, Deoghuria D, Agarwala A, Ghoshal AG, Dey SK. Clinicopathological profile of lung cancer in a tertiary medical center in India: Analysis of 266 cases. *J Dent Oral Hyg*. 2011;3(3):30–3.
7. Patel P, Patel S, Kotadiya T, Gunjaliya A, Shah J, Santwani PM. Comparison and analysis of various bronchoscopic techniques in diagnosis of suspected lung cancer. *Int J Respir Med*. 2013;2(4):34–7.
8. Mukherjee S, Bandyopadhyay G, Bhattacharya A, Ghosh R, Barui G, Karmaka R. USG Guided fine needle aspiration cytology of solitary pulmonary nodules suspected to be bronchogenic carcinoma: Experience of a general hospital. *J Cytol*. 2010;27(1):8–11.
9. Bhadja JT, Dhruva GA. A study of sputum cytology, pleural fluid examination, and radiologically guided fine needle aspiration cytology in lung tumors; 2018.
10. Shah UV, Dhruva GA. Role of fine needle aspiration cytology in the diagnosis of lung lesions; 2005.
11. Agarwal A, Ghotekar LH, Garbyal RS. Evaluation of pulmonary malignancies in Kathmandu Valley and role of bronchoscopic techniques in diagnosis of such cases. *J Indian Acad Clin Med*. 2003;4(2):127–33.
12. Cristallini EG, Ascani S, Farabi R, Paganelli C, Peciarolo A, Bolis GB. Fine needle aspiration biopsy in the diagnosis of intrathoracic masses. *Acta Cytol*. 1992;36(3):416–22.
13. Gouliamos AD, Gannopoulos DH, Panagi GM, Flatoridis NK, Politi HAD, Vinhos LJ. USG Guided fine needle aspiration of peripheral lung opacities. *Acta Cytol*. 2000;44:344–8.
14. Ghosh N. USG Guided fine needle aspiration cytology of mass lesions of lung: Our experience. *Indian J Med Paediatr Oncol*. 2011;32(4):192–6.
15. Parate SN, Sankareen SM, Munshi MM. Primary bronchogenic carcinoma: Clinical profile of 60 cases. *J Cytol*. 2003;20(2):189–96.
16. Wallace MJ, Krishnamurthy S, Broamaling LD, Gupta S, Ahrar K, Morallo FA, et al. CT-guided percutaneous fine-needle aspiration biopsy of small (< or =1-cm) pulmonary lesions. *Radiology*. 2002;225(3):823–8.
17. Dahistorm JE, Langdale-Smith GM, James DT. Fine needle aspiration cytology of pulmonary lesions. *J Pathol*. 2001;13:13–6.

Author biography

Jaysukh Kumar Berani, Senior Resident

J D Dalsania, Associate Professor

Gauravi Dhruva, Professor and Head

Cite this article: Berani J, Dalsania JD, Dhruva G. Studies of malignant & non-malignant lung lesions detected by USG guided FNAC in the Saurashtra region. *Indian J Pathol Oncol* 2024;11(3):284-288.