

Content available at: <https://www.ipinnovative.com/open-access-journals>

Indian Journal of Pathology and Oncology

Journal homepage: www.ijpo.co.in

Letter to Editor

Benign metastasizing tumor or benign epithelial inclusion in the node: A diagnostic dilemma

Paruvathavarthini Thambiraj¹, Norton Stephen², Debasis Gochhait^{1*}, Neelaiah Siddaraju¹

¹Dept. of Pathology, Jawaharlal Institute of Postgraduate Medical Education and Research, Puducherry, India

²Dept. of Pathology, All India Institute of Medical Sciences, Madurai, Tamil Nadu, India



ARTICLE INFO

Article history:

Received 25-04-2024

Accepted 20-05-2024

Available online 09-07-2024

Keywords:

Metastasis

Pleomorphic adenoma

Benign

ABSTRACT

Generally metastasis implies malignancy, but there are some benign tumours which can also metastasize to lymph nodes, bone, and kidney. The benign tumours which can metastasize includes pleomorphic adenoma, leiomyoma, giant cell tumour of bone and meningioma. A 27 years old female presented to the cytology clinic with the submandibular swelling for past 3 months. Patient is a known case of pleomorphic adenoma post-surgery in the same region 6 years back. On examination two nodular swelling each measuring 1 x 1 which is firm mobile near scar site and left level III lymph node region. A non-guided fine needle aspiration cytology was performed from both the swelling. The Papanicolaou- and May-Grünwald Giemsa-stained smears from both sites showed features of pleomorphic adenoma. The interesting aspect of this article is cytological diagnosis of benign pleomorphic adenoma metastasizing to lymph nodes which is a rare entity.

This is an Open Access (OA) journal, and articles are distributed under the terms of the [Creative Commons Attribution-NonCommercial-ShareAlike 4.0 License](https://creativecommons.org/licenses/by-nc-sa/4.0/), which allows others to remix, tweak, and build upon the work non-commercially, as long as appropriate credit is given and the new creations are licensed under the identical terms.

For reprints contact: reprint@ipinnovative.com

1. Case History

Twenty-seven years old female presented to the cytology clinic with the submandibular swelling for the past three months. The patient was a known case of pleomorphic adenoma post-surgery in the same region six years back. On examination, one nodular swelling with an irregular surface measuring 1 x 1 cm was appreciated beside the scar site. The other swelling, almost of the same measurement, was seen in the left level III lymph node region (Figure 1 A). Both the lumps were firm mobile and painless. A non-guided fine needle aspiration cytology (FNAC) was performed from both the lumps. Papanicolaou- and May-Grünwald Giemsa-stained smears were moderately cellular shows clusters as well as dispersed plasmacytoid cells and few ductal epithelial cells with patchy stromal matrix in the background. (Figure 1 B). Aspirate smears from the lymph

node showed similar morphology.(Figure 1 B, C, D) No evidence of atypia/malignancy was appreciated in the smear studied from both the sites. Informed consent was obtained from patient for reporting this case.

2. Discussion

This case was reported as recurrent pleomorphic adenoma at the primary and benign metastatic deposits in the lymph node which is confirmed on ultrasonography. The diagnosis was based on presence of plasmacytoid myoepithelial cells and benign ductal epithelial cells with no atypia in a background of fibrillary chondromyxoid material at both the sites. When we see relatively bland/benign-looking foreign cells in a node should consider two possibilities. First, is it a benign epithelial inclusion in the node or second a chance of a benign metastasizing tumour. The benign epithelial lesions that can be observed in the lymph node include epithelial inclusion cysts, which are

* Corresponding author.

E-mail address: debasis.go@gmail.com (D. Gochhait).

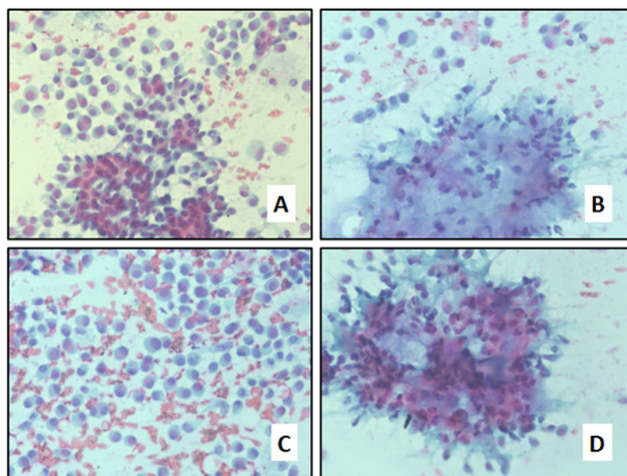


Figure 1: A, C): Sheets of plasmacytoid cells in pap stain (200x) in lymph node and salivary region swelling; B, D): Fibrillary chondroid matrix in pap stain (200x) in lymph node and salivary region swelling

also called benign metastasis or heterotopia. The sites include Axillary, cervical, mediastinal, mesenteric, para-aortic, pelvic, renal lymph nodes.¹ Different theories regarding the pathogenesis of inclusions are reported in the literature, which includes benign metastasis, developmental heterotopia, and metaplasia of multipotent cells, iatrogenic displacement, and transport.¹ Examples of benign tissue include salivary gland, thyroid follicles, breast tissue, respiratory type epithelium, fallopian tube lining, or endometrium. Single or tubules of epithelial cells in sub capsular sinus of draining lymph node after surgical or needle manipulation.¹ In cervical lymph nodes, the common epithelial inclusions include thyroid, salivary gland tissue, and squamous epithelium. We kept that possibility, but in our case, we had a history of surgery for Pleomorphic adenoma, and there was a recurrence at that site. The appreciation of epithelial cells, myoepithelial cells, and the chondromyxoid fibrillary matrix also made us conclude metastatic pleomorphic adenoma ahead of epithelial inclusion.

Pleomorphic adenoma is the most common benign salivary gland tumour. The metastases are observed more frequently in bones, lungs, and lymph nodes.² There are several hypotheses about the aetiology of the metastasis of benign tumours and the recurrence. It is believed that the enucleation of the pleomorphic adenoma may be incomplete, contributing to recurrence. At the same time, vascular implantation of tumour cells during surgery

can occur, leading to dissemination by the haematogenous route, which could be the possible hypothesis in our case. In cases with nodal metastasis, the other possibility that should be considered is malignant transformation (carcinoma ex Pleomorphic adenoma) at the recurrence site and a metastatic deposit in the lymph node. However, in our case, there was adequate cellularity in smears of both sites without any recognizable features of malignancy (Lack of rapid growth/cellular atypia/frequent mitotic figures/necrosis).

This case helps in reminding the cytologists of the list of some benign tumours which can metastasize such as pleomorphic adenoma, leiomyoma, giant cell tumour of bone and meningioma.^{3–5} This article implies the importance of cytology in early diagnosis of the rare phenomenon.


3. Conflict of Interest

None.

References

- Spinardi JR, Gonçalves I, Falce TSL, Fregnani JH, Barros MD, Macéa JR. Benign Inclusions in Lymph Nodes. *Int J Morphol.* 2007;25(3):625.
- Marioni G, Marino F, Stramare R, Marchese-Ragona R, Staffieri A. Benign metastasizing pleomorphic adenoma of the parotid gland: a clinicopathologic puzzle. *Head Neck.* 2003;25(12):1071–6.
- Chen KT. Metastasizing pleomorphic adenoma of the salivary gland. *Cancer.* 1978;42(5):2407–11.
- Abramson S, Gilkeson RC, Goldstein JD, Woodard PK, Eisenberg R, Abramson N. Benign metastasizing leiomyoma: clinical, imaging, and pathologic correlation. *AJR Am J Roentgenol.* 2001;176(6):1409–13.
- Maloney WJ, Vaughan LM, Jones HH, Ross JO, Nagel DA. Report of three cases and review of the literature. *Clin Orthop Related Res.* 1989;243:208–15.

Author biography

Paruvathavarthini Thambiraj, Senior Resident  <https://orcid.org/0009-0001-3629-1976>

Norton Stephen, Assistant Professor

Debasis Gochhait, Additional Professor

Neelaiah Siddaraju, Professor

Cite this article: Thambiraj P, Stephen N, Gochhait D, Siddaraju N. Benign metastasizing tumor or benign epithelial inclusion in the node: A diagnostic dilemma. *Indian J Pathol Oncol* 2024;11(2):216-217.