

Content available at: <https://www.ipinnovative.com/open-access-journals>

Indian Journal of Pathology and Oncology

Journal homepage: [www.ijpo.co.in](http://www.ijpo.co.in)

## Case Report

# Dual lesions in thyroidectomy, unravelling the enigma of thyroid collision tumors: A rare case report

Atira Mirza<sup>1</sup>, Amrutha B Shankar<sup>1</sup>, Akanksha Hegde<sup>1\*</sup>, Sudha H M<sup>1</sup>

<sup>1</sup>M. S. Ramaiah Medical College, Bengaluru, Karnataka, India



### ARTICLE INFO

#### Article history:

Received 01-03-2024

Accepted 20-03-2024

Available online 17-04-2024

#### Keywords:

Follicular adenoma

Papillary thyroid carcinoma

Thyroidectomy

Collision tumors

### ABSTRACT

Follicular adenoma (FA) of the thyroid gland is a benign, solitary, encapsulated tumor. It shows microfollicular and macrofollicular growth patterns. Papillary thyroid carcinoma (PTC) is the most common thyroid malignancy and follicular variant is the most common subtype of PTCs. They have tumor cells arranged in follicular pattern which exhibit nuclear features of papillary carcinoma.

Here we present a remarkable case of a patient who was clinically diagnosed as multinodular goiter, TIRADS 2 (not suspicious) by ultrasonography and Fine needle aspiration cytology report was given as a benign adenomatoid nodule. However, histopathological examination revealed the unexpected coexistence of both follicular adenoma and PTC.

This is an Open Access (OA) journal, and articles are distributed under the terms of the [Creative Commons Attribution-NonCommercial-ShareAlike 4.0 License](https://creativecommons.org/licenses/by-nc-sa/4.0/), which allows others to remix, tweak, and build upon the work non-commercially, as long as appropriate credit is given and the new creations are licensed under the identical terms.

For reprints contact: [reprint@ipinnovative.com](mailto:reprint@ipinnovative.com)

## 1. Introduction

Follicular neoplasms of the thyroid gland include benign follicular adenoma and follicular carcinoma. FA consists of a micro and macrofollicular architecture with follicles lined by cuboidal epithelial cells. It is a benign, solitary, encapsulated tumor of the thyroid gland. They are seen in 2 to 4.3% of the population and are more common in females. They present as a well-encapsulated, firm, or rubbery, homogenous, round tumor.<sup>1</sup>

Papillary carcinoma is the most common type of thyroid cancer.<sup>2</sup> Follicular variant of PTC (FV-PTC) is the most common subtype, and accounts for 41% of all PTCs. It predominantly shows a follicular architecture, lined by cells with nuclear features of PTC.<sup>3</sup> There are two forms of follicular variant: the encapsulated/well circumscribed and the infiltrative form. The encapsulated FV-PTC is characterized by a noninvasive tumor with a follicular pattern, and nuclear features of PTC, a low risk of lymph

node metastases and recurrence risk, a strong association with RAS mutations and excellent prognosis.<sup>4</sup>

The incidence of FV-PTC has been raising and since it contains a mixed histology of both, it inherits the features from both types and is thus more aggressive. It has a greater tendency for pulmonary metastasis. Among them, the likelihood of persistent disease was 15% and risk of progressive disease was 8%.<sup>5</sup> Collision tumors in thyroid (FA and PTC) accounts for 1%.<sup>6</sup>

This case illustrates the uncommon coexistence of FA and PTC in a single patient.

## 2. Case Report

A 41-year female patient came with the complaints of neck swelling for 10 years, which gradually progressed in size. It was associated with dull aching pain.

Local examination showed thyroid swelling involving both the lobes. On the right-side measuring 5x4 cm and on the left side measuring 3x2cm. The swellings moved with deglutition. Clinically it was diagnosed as multinodular

\* Corresponding author.

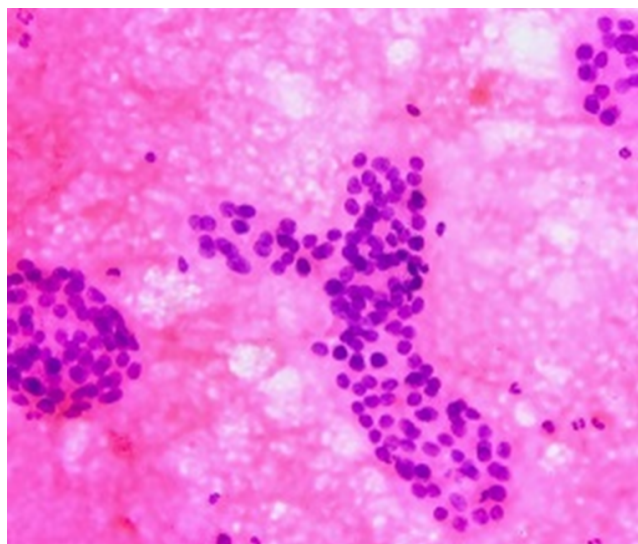
E-mail address: [akankhegde96@gmail.com](mailto:akankhegde96@gmail.com) (A. Hegde).

goiter.

Lab investigations- complete blood count, coagulation profile, serum electrolytes were found to be normal. The patient was euthyroid.

Ultrasonography- showed bulky thyroid gland lobes with nodules – TIRADS-2 (benign nodule, not suspicious of malignancy).

FNA of neck swelling- reported as adenomatoid nodule (Bethesda system of reporting thyroid cytology- Category-II) (Figure 1).



**Figure 1:** H&E, X 400, FNA showing benign thyroid follicles

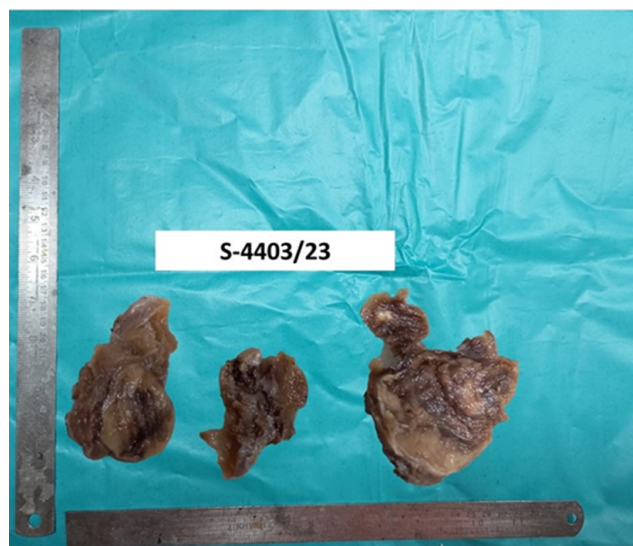
## 2.1. Histopathology

### 2.1.1. Gross

Received total thyroidectomy specimen, the right lobe measured 5.7x4.2x2.3 cm, left lobe measured 5x3.5x1.3 cm and isthmus measured 3.5x1.6x0.5cm. The external surface of the right lobe was enlarged, nodular. On the cut section amber colored fluid oozed out and noted a diffuse, grey-white, firm, and gritty area measuring 3.5x3.5x1.8cm with intervening normal tissue. The external surface of the left lobe was nodular. On the cut section noted a well circumscribed and encapsulated, tan-grey to pale yellow lesion in the lower pole measuring 2.5x2x0.5cm surrounded by normal looking thyroid tissue. The Isthmus appeared unremarkable (Figure 2).

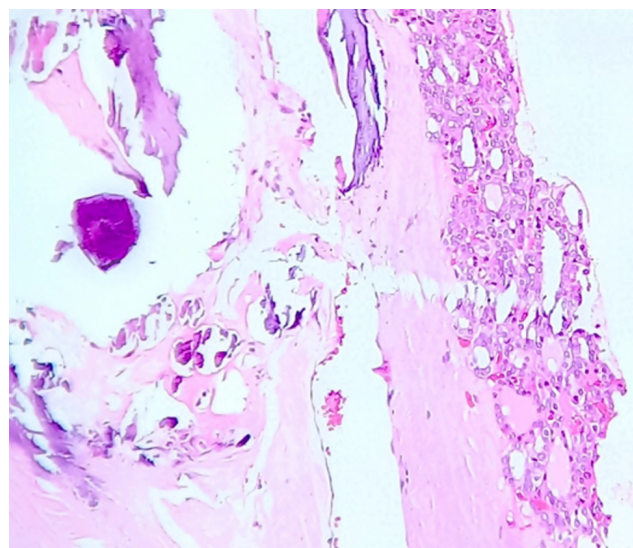
### 2.1.2. Microscopy

Sections studied from the right lobe of thyroid showed an infiltrating malignant neoplasm. The tumor cells are arranged in variable sized follicles. The individual tumour cells exhibited finely dispersed chromatin imparting an optically clear appearance, intranuclear grooves, pseudoinclusions and moderate amounts of eosinophilic



**Figure 2:** Gross picture of the total thyroidectomy specimen

cytoplasm. The mitotic count was 1 per 2 square mm. Focal areas of calcification seen (Figures 3 and 4).



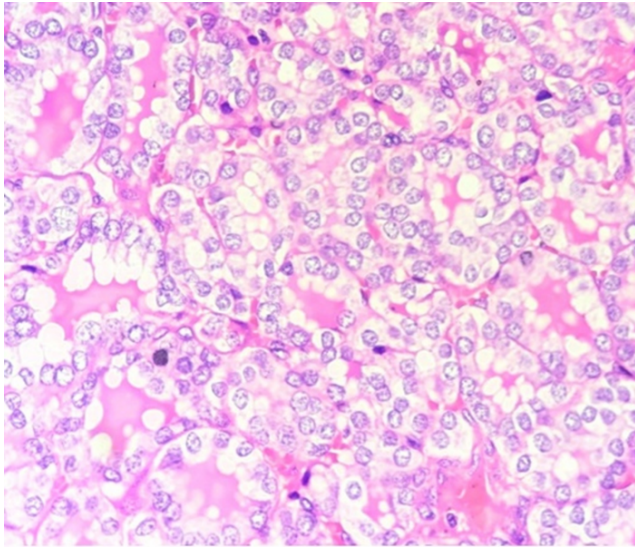
**Figure 3:** H&E, X 100, Right lobe showing tumor cells invading the capsule and focal calcification

There was no evidence of lymphatic / perineural invasion/ angioinvasion.

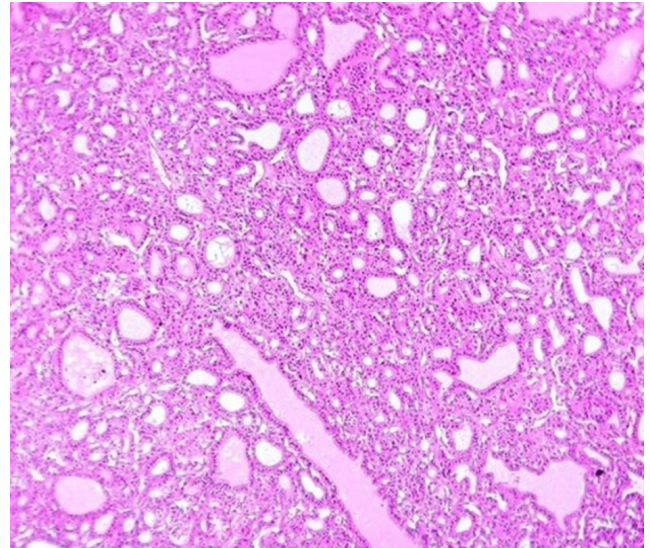
Sections studied from the left lobe showed an encapsulated benign neoplasm composed of follicular cells arranged in microfollicles and lined by cuboidal to low columnar cells. No capsular/ vascular invasion seen (Figures 5 and 6). The isthmus showed normal histology of thyroid.

The final report was given as papillary carcinoma, infiltrative follicular subtype (TNM staging-pT2N0MX,

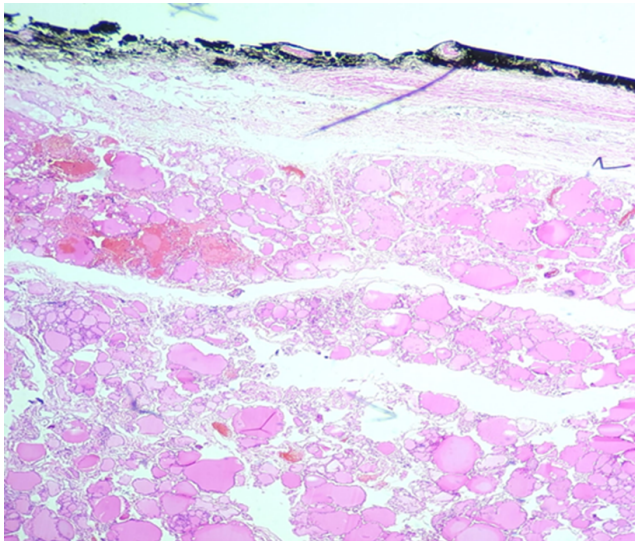




**Figure 4:** H&E, X 400, Tumor cells arranged in follicles showing papillary nuclear features



**Figure 6:** H&E, X 100, Left lobe showing benign follicular adenoma



**Figure 5:** H&E, X 40, Left lobe showing encapsulated follicular adenoma

Stage group- I) of the right lobe and follicular adenoma of the left lobe.

### 3. Discussion

The most common endocrine malignancy is thyroid carcinoma accounting for 1-5% of all carcinomas in females and less than 2% in males worldwide.<sup>5</sup>

Two independent neoplasms that occur in the same organ, separated by normal tissue, and have no histological admixture are defined as collision tumor. It includes two benign lesions or one benign, one malignant lesion or two

malignant lesions. Hence, this is a collision tumor of PTC and FA of thyroid.<sup>6</sup>

Collision tumors occur throughout the body and account for about 1% of thyroid tumors. Most literature says MTC (Medullary thyroid carcinoma) and PTC, or PTC coexisting with metastatic tumors is common collision tumor reported followed by PTC and follicular thyroid carcinoma (FTC). Thereafter, comes other collision tumor of thyroid which are extremely rare. A very few literatures are available on PTC and FA collision tumor.<sup>7</sup>

Teresa Pusiol et al. (2013) Reported the first case of coexistence follicular variant of papillary carcinoma, atypical adenoma, and adenoma with bizarre nuclei in the same thyroid.<sup>4</sup>

Sefika Burcak Polat et al. (2016) have reported 3 collision tumors of PTC and FA and concluded that further studies are required for genetic characterization.<sup>8</sup>

Ari M. Abdullah et al. (2022) have done a case series on thyroid collision tumors, which have 7 coexisting PTC and FA and 1 MTC and FA. Also stated that PTC and FA or MTC and FA are extremely rare collision tumors of thyroid.<sup>9</sup>

Several theories have been proposed regarding the pathogenesis of collision tumour. "Stem cell theory" states these tumors arise from a single pluripotent precursor cell. "Neoplastic coercion theory" postulates that the origin of one tumour alters surrounding microenvironment and makes way for other tumors to originate and proliferate. Lastly "Random collision theory" states that collision of two different tumour is coincidental.<sup>9</sup>

N-RAS and BRAF gene mutations are associated in both benign and malignant thyroid nodules, hence possibility of an adenoma-carcinoma sequence in thyroid nodule can be

considered. None of these theories is completely able to explain the origin of collision tumors as there is not enough evidence and literature.<sup>10</sup>

Treatment of collision tumour is challenging as there is no study on patient's prognosis and survival. Multimodal treatment is recommended to the most aggressive tumor with higher stage among the two.<sup>5</sup>

#### 4. Conclusion

Here we highlight the importance of gross and histomorphological examination of thyroidectomy, even when clinical and radiological findings suggest a benign lesion. This case thus serves as an important reminder that the diagnosis of thyroid nodules can be complex and unpredictable.

#### 5. Source of Funding

None.

#### 6. Conflict of Interest

None.


#### References


1. Mchenry CR, Phitayakorn R. Follicular adenoma, and carcinoma of the thyroid gland. *Oncologist*. 2011;16(5):585–93.
2. Thompson LD. Ninety-four cases of encapsulated follicular variant of papillary thyroid carcinoma: A name change to Noninvasive Follicular Thyroid Neoplasm with Papillary-like Nuclear Features would help prevent overtreatment. *Mod Pathol*. 2016;29(7):698–707.
3. Yu XM, Schneider DF, Levenson G, Chen H, Sippel RS. Follicular variant of papillary thyroid carcinoma is a unique clinical entity: a population-based study of 10,740 cases. *Thyroid*. 2013;23(10):1263–8.
4. Pusiol T, Zorzi MG, Morichetti D. Coexistence of atypical adenoma, adenoma with bizarre nuclei and follicular variant of papillary carcinoma of the thyroid. *Indian J Pathol Microbiol*. 2013;56(4):399–401.
5. James S, Aravind S, Gopinath V, Nayanar SK. Phenotypic Appraisal of Collision Tumors of Thyroid - Initial Experience of a Rare Entity at a Cancer Centre in South India. *Asian Pac J Cancer Care*. 2022;7(2):415–9.
6. Bulte CA, Hoegler KM, Khachemoune A. Collision tumors: A review of their types, pathogenesis, and diagnostic challenges. *Dermatol Ther*. 2020;33(6):e14236.
7. Bojoga A, Stănescu L, Badiu C. Collision tumors of the thyroid. A special clinical and pathological entity. *Arch Clin Cases*. 2021;8(4):84–90.
8. Polat SB, Arpacı D, Yazgan A, Başer H, Kılıç M. Simultaneous Occurrence of Different Follicular Neoplasms within the Same Thyroid Gland. *Turk J Endocrinol Metab*. 2016;20:31–5.
9. Abdullah AM, Qaradakh AJ, Ahmed MM, Salih AM, Omarf SS, Kakamad FH, et al. Thyroid collision tumors; A case series with literature review. *Ann Med Surg (Lond)*. 2022;76:103444.
10. Bangaraiahgari R, Panchangam RB, Puthenveetil P, Mayilvaganan S, Bangaraiahgari R, Banala RR, et al. Is there adenoma-carcinoma sequence between benign adenoma and papillary cancer of thyroid: A genomic linkage study. *Ann Med Surg (Lond)*. 2020;60:695–700.

#### Author biography

**Atira Mirza**, Senior Resident  <https://orcid.org/0009-0002-8076-3288>

**Amrutha B Shankar**, PG Student  <https://orcid.org/0009-0001-9117-1889>

**Akanksha Hegde**, PG Student  <https://orcid.org/0009-0008-6426-8395>

**Sudha H M**, Professor  <https://orcid.org/0009-0006-1378-5582>

**Cite this article:** Mirza A, Shankar AB, Hegde A, Sudha H M. Dual lesions in thyroidectomy, unravelling the enigma of thyroid collision tumors: A rare case report. *Indian J Pathol Oncol* 2024;11(1):52-55.