

Lipoleiomyomatous hamartoma of breast

Premalatha P¹, Renuka IV^{2,*}, Rizwana SK³, Pavani P⁴

¹Professor & Head, ²Professor, ^{3,4}PG Student, Dept. of Pathology, NRI Medical College, Andhra Pradesh

***Corresponding Author:**

Email: repriya56@gmail.com

Abstract

We report a case of bilateral massive painful breast enlargement of recent onset in a post-menopausal woman secondary to marked generalized hyperplasia of erector pilorum muscles. The histology of the lesions does not fit into any of the benign tumors of breast and probably corresponds to the mammary hamartoma. The term Lipoleiomyomatous hamartoma is apt to describe the entity. The search into the literature for such an abnormal, sudden presentation in a postmenopausal woman was not fruitful and so we consider this to be a rare case presentation.

Key Words: Lipoleiomyomatosis, Myoid hamartoma, Macromastia, smooth muscle actin, Leiomyoma

Access this article online	
Quick Response Code:	Website: www.innovativepublication.com
	DOI: 10.5958/2394-6792.2016.00067.3

Present Case

A 60 year old female presented with persistent pain in both breasts of 2 years duration. The pain was pricking in nature and there was aching pain in back and neck for one and a half years.

She had to frequently change the size of her blouse, due to progressive increase in size of her breasts in recent times. She underwent hysterectomy at the age of 30 because of uterine leiomyomata. On inspection she was found to have massive bilateral breast hypertrophy (macromastia). (Fig. 1) On palpation the breasts were non tender, soft, and no mass/ masses felt. Axillary lymph nodes were not palpable and ultrasound of the abdomen was normal.

Mammography did not reveal any significant abnormality or calcification but only bilateral breast hypertrophy.

Bilateral vertical reduction mammoplasty was done on the patient and the specimens were sent for histopathological examination. (Fig. 1)

Introduction

Breast hamartomas are rare, ill defined, benign breast neoplasms that can reach large sizes. Arrigoni et al. first used the term hamartoma in 1971.⁽¹⁾ Later several sporadic cases were reported and named as adenolipomas, fibroadenolipomas etc. based on the components present.⁽²⁾ When a hamartoma shows a predominant smooth muscle component, it is referred to as a myoid hamartoma; a still rarer variant and was described for the first time in 1973 by Davies and Riddell.⁽³⁾ The incidence of breast hamartoma among benign breast tumors was reported to be 4.8% by Charpin et al.⁽⁴⁾ Lipoleiomyomatous hamartoma of the breast has not been reported so far in literature.



Fig. 1: Pre-operative clinical picture of patient with macromastia and postoperative picture after reduction mammoplasty

Gross Examination

The right breast specimen received was a skin covered fibro fatty tissue mass measuring 24x10x5cm. On cut section the color was yellow with no solid grey white areas identified. Nipple and areola were not included in the specimen. (Fig. 2A)

The left breast specimen received was a skin covered fibro fatty tissue mass measuring 19x12x6cm. Cut section was similar to the other side. Nipple and areola were not included in the specimen. (Fig. 2B)

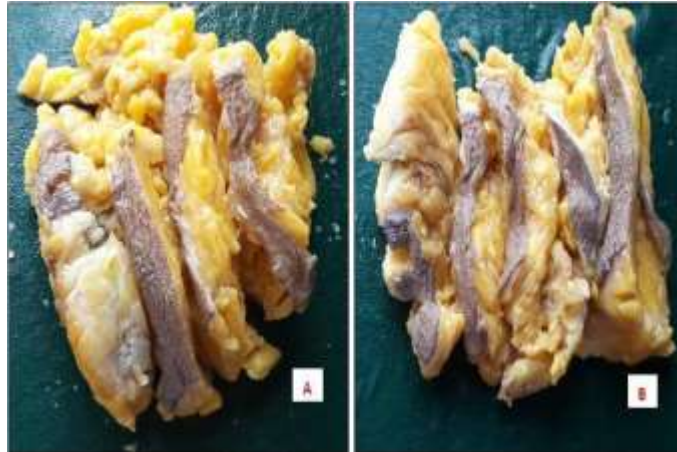


Fig. 2: Gross specimens from A) Right breast B) Left breast

Histopathology

Sections studied from skin over both breasts showed normal pigmented squamous lining epithelium and breast tissue showed multiple markedly hypertrophied and hyperplastic smooth muscle bundles (Muscularis mammillae, that are responsible for nipple retraction) intervened by ropy collagen underneath the skin as a strip. (Fig. 3) There were prominent nerve bundles in between the muscle bundles, probably the cause for pain with muscle contraction. Also there was near total obliteration and atrophy of breast specific parenchyma except for a very occasional residual duct and fat. Fat contributed to the rest of the breast substance that was at a deeper level in the breast compared to the smooth muscle bundles (Age related/ pressure atrophy of breast). A final diagnosis of Lipoleiomyomatous hamartoma of breast was signed out based on immunohistochemistry. (Fig. 4)

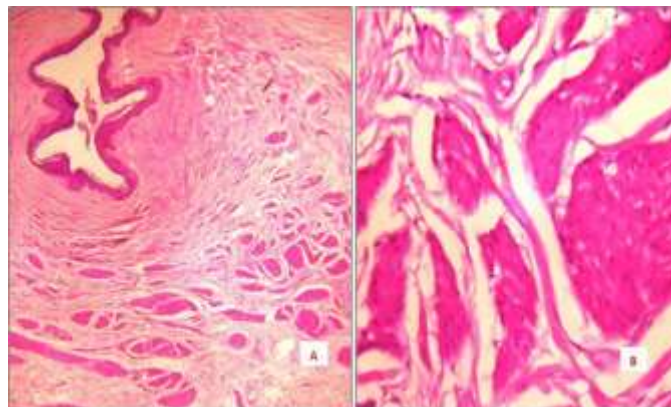


Fig. 3: A. Normal pigmented squamous epithelium and breast tissue with multiple markedly hypertrophied and hyperplastic smooth muscle bundles as a strip with intervening collagen (H&E, x100) B. High power of the muscle bundles (H&E, x400)

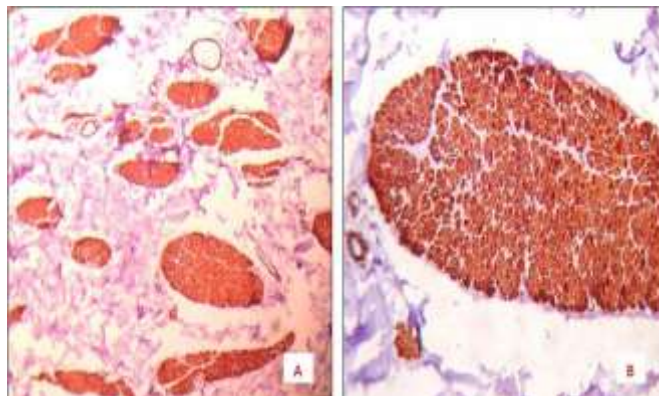


Fig. 4: A. Smooth muscle actin positivity in the muscle bundles (IHC, x100) B. Smooth muscle actin positivity in the muscle bundles (IHC, x400)

Discussion

Cutaneous Leiomyomas are benign smooth muscle tumors of skin that arise from pilar muscle, blood vessel walls, the dartos muscle of the scrotum or from the labia majora, as well as from the erectile smooth muscle cells of the nipple in either sex.^(5,6,7)

Leiomyomas of breast are extremely rare benign mesenchymal tumors derived from the erectile smooth muscle cell of the nipple⁽⁸⁾ and less than 20 cases are reported in literature. They present as asymptomatic slow growing masses or with pain and tenderness. The pain thought to occur is secondary to calcium-dependent contraction of smooth muscle cells within the tumor.⁽⁹⁾

They can be bilateral or unilateral; variably sized masses that are well-circumscribed, homogeneous, firm, and whitish on cut section. In our case the enlargement of both breasts was diffuse and lacked circumscription.

The histopathologic features of breast leiomyomas are the same as the leiomyomas of the other sites. The tumors are composed of fascicles of spindle cells that have no atypia, mitoses or necrosis and have ovoid nuclei with delicate chromatin, small inconspicuous nucleoli and eosinophilic cytoplasm. These cells show diffuse strong positivity with Immunohistochemical markers smooth-muscle actin (SMA), vimentin and desmin.⁽¹⁰⁾ In our case the tumor cells were positive for smooth muscle actin (SMA) and vimentin.

The etiopathogenesis of breast hamartomas is not clear but they are thought to result from dysgenesis⁽¹¹⁾ rather than a true neoplastic process. There are no clear data on the source of smooth muscle for myoid hamartomas, but this muscle could be derived from vessels, the nipples, undifferentiated breast stromal tissue or myoepithelial cells.⁽¹²⁾ Another study hypothesized smooth muscle source is the metaplasia of breast stromal cells.^(13,14) On the other hand Diaz-Arias et al. suggested that the origin of these tumors may include the following: (a) a teratoid origin with extreme overgrowth of the myomatous elements (b) embryologically displaced smooth muscle from the

nipple, (c) angiomatous smooth muscle, (d) multipotent mesenchymal cell, (e) myoepithelial cells.

This case neither presented as single/ multiple circumscribed masses as in leiomyoma or piloleiomyoma.

Though there was no admixture of ducts, smooth muscle and fat it still probably represents a hamartomatous process involving erector pilorum muscle unrelated to nipple or areola of both breasts in atrophic breasts containing predominantly fat.

Conclusion

A post-menopausal woman presenting with a recent onset of painful massive enlargement of both breasts did not show any circumscribed palpable nodules or radiologically defined masses that were vulnerable for surgical excision. Hence she underwent conservative bilateral reduction mammoplasty. Histology from both the breast masses showed multiple prominent markedly hypertrophied and hyperplastic smooth muscle bundles polarized to skin surface that were interspersed with collagen. There was near total obliteration and atrophy of breast specific parenchyma by fat and a very occasional residual duct that was pushed to a deeper level. The smooth muscle cells were positive with smooth muscle actin and vimentin. There was no family history of such lesion, but the indication of hysterectomy in the present case interpreted from patient's history denotes leiomyomata.

This case neither presented as single/ multiple circumscribed masses as in leiomyoma or piloleiomyoma nor was there any disorganized admixture of ducts, smooth muscle and fat as found in a hamartomatous process. It is still a non-neoplastic condition and probably a hamartoma involving erector pilorum muscle unrelated to nipple or areola in both breasts and breast fat with no identifiable cause or usage of hormones.

As breast hamartomas are rare, the possibility of its underdiagnosis as fibroadenoma especially in aspiration cytology cannot be over emphasized. But the diagnosis

can definitely be made on excision biopsy and also to a certain extent by adequate core needle biopsy, along with clinical and radiological correlation.

Conflicts of Interest: Nil

Patients consent form has been taken for this paper publication

References

1. Arrigoni MG, Dockerty MB, Judd ES. The identification and treatment of mammary hamartoma. *Surg Gynecol Obstet.* 1971;133(4):577-82.
2. Altermatt HJ, Gebbers JO, Laissue JA. Multiple hamartomas of the breast. *Appl Pathol.* 1989;7(2):145-8.
3. Davies JD, Riddell RH: Muscular hamartomas of the breast. *J Pathol* 1973,111:209-211.
4. Charpin C, Mathoulin MP, Andrac L, Barberis J, Boulat J, Sarradour B, et al. Reappraisal of breast hamartomas. A morphological study of 41cases. *Pathol Res Pract.* 1994;190(4):362-71.
5. V. A. Holst, J.M. Junkins-Hopkins, and R. Elenitsas, "Cutaneous smooth muscle neoplasms: clinical features, histologic findings, and treatment options," *Journal of the American Academy of Dermatology* 2002 vol. 46, no. 4, pp. 477–490.
6. Leiomyomas with additional mesenchymal elements B. Ragsdale, "Tumors with fatty, muscular, osseous, and cartilaginous differentiation," in *Lever's Histopathology of the Skin*, D. Elder, R. Elenitsas, B. Johnson Jr., and G. Murphy, Eds Lippincott-Raven, Philadelphia, Pa,USA, 9th edition,2005 pp. 1061–1107.
7. R. Yokoyama, H. Hashimoto, Y. Daimaru, and M. Enjoji, "Superficial leiomyomas. A clinicopathologic study of 34 cases," *Acta Pathologica Japonica*, 1987 vol. 37, no. 9, pp.1415–1422.
8. Leiomyoma of the Breast Parenchyma; (Sidoni A, Lüthy M, Bellezza G, Consiglio MA, Bucciarelli E. Leiomyoma of the breast: case report and review of the literature. *Breast* 1999;8:289–290.
9. J. A. Thompson Jr., "Therapy for painful cutaneous leiomyomas," *Journal of the American Academy of Dermatology*1985 vol. 13, no. 5, pp. 865–867.
10. Diaz-Arias AA, Hurt MA, Loy TS, Seeger RM, Bickel JT. Leiomyoma of the breast. *Hum Pathol* 1989;20(3):396-399.
11. Guray M, Sahin AA. Benign breast diseases: classification, diagnosis, and management. *Oncologist.* 2006;11(5):435-49.
12. Altermatt HJ, Gebbers JO, Laissue JA. Multiple hamartomas of the breast. *Appl Pathol.* 1989;7(2):145-8.
13. Kajo K, Zubor P, Danko J. Myoid (Muscular) Hamartoma of the Breast: Case Report and Review of the Literature. *Breast Care (Basel)* 2010;5(5):331-334.
14. Murugesan JR, Joglekar S, Valerio D, Bradley S, Clark D, Jibril JA. Myoid hamartoma of the breast: case report and review of the literature. *Clin Breast Cancer.* 2006;7(4):345-6.