

Invasive lobular carcinoma of male breast: What we don't know-A report of 5 cases

Gayatri Gogoi^{1*}, Lucky M Duara², Mondita Borgohain³, Daljeet Kaur⁴, Uttam Konwar⁵, Dipakkr Sarma⁶

^{1,2}Assistant Professor, ³Professor, ⁴PG Student, Dept. of Pathology, ⁵Assistant Professor, ⁶Associate Professor, Dept. of General Surgery, Assam Medical College & Hospital, Dibrugarh

***Corresponding Author:**

Email: gayatrigogoi303@gmail.com

Abstract

Male breast carcinoma is a very rare malignancy. It mostly has invasive ductal histology while invasive lobular histology is exceptionally uncommon constituting no more than 1-2% of male breast cancer cases. Here we present five cases of invasive lobular breast carcinoma arising in male breasts which were diagnosed by histological examination. Immunohistochemistry was performed to evaluate the hormonal receptor status. Early diagnosis of breast carcinoma in males have prognostic implication in patients' survival and show better response to hormonal therapy when it is reactive for estrogen and progesterone receptors. Therefore it is mandatory for the pathologists to keep this rare condition in their minds while evaluating any case of male breast lump and to perform a vigorous search for any small focus of this tumour in circumstances of male breast lump including gynaecomastia. Majority of information regarding treatment of male breast cancer is retrospective in nature and is derived mainly from small single-institution series; thus, the choice of treatment modalities is generally guided by extrapolation of data from female breast cancer. Due to paucity of data and the extreme rarity, male breast carcinoma should be considered and managed as a distinct entity. The invasive lobular carcinoma perhaps with an added advantage for being reactive of hormonal receptors, which could be treated by adjuvant Tamoxifen. It is hoped that a long term multicentric studies will help us to know the prognostic implication of uncommon invasive lobular histology, as well as trials could be strategically designed to optimize the treatment.

Access this article online	
Quick Response Code:	Website: www.innovativepublication.com
	DOI: 10.5958/2394-6792.2016.00060.0

Introduction

Male breast carcinoma is a very rare entity¹. This rare condition represents approximately 1% of all invasive breast cancer cases and less than 1% of all malignancies in men.² Most primary male breast cancers diagnosed are found to be of invasive ductal histology accounting for nearly 90-93.7% of total cases.^{1,3} A small percentage of cases are ductal carcinoma in situ, and lobular histology comprising of merely of 2% of the total cases.^{1,4} Reported differences between male and female breast carcinoma have been noted, and male breast carcinoma has a tendency to present at higher clinical stages and with more lymph node metastases thereby conferring an overall poor prognosis.^{5,6,7} A limited experience and scientific literature is available regarding male breast carcinoma and even more rarer is lobular histology. Even though lobular structures are quite infrequent in the normal male, sporadic cases of invasive lobular breast cancer [ILC] have been described.¹ In cases of lobular histology whether it has any advantage over invasive ductal types are yet to be known. Here we are reporting cases diagnosed as invasive lobular carcinoma of male

breast in a period between years 2009 to 2015 in our tertiary care centre from North East India.

A report of 5 Cases

Five cases of male breast cancer with histology invasive lobular carcinoma {ILC} diagnosed in a tertiary care hospital from January 2009 to December 2015.

CASE 1: Patient was 55 years old and presented with a lump of size 4x3cm² in the left breast. No ipsilateral axillary lymph nodes were palpable. He had history of undescended testes for which he underwent orchidectomy 7 years back.

CASE 2: Patient was 60 years old and had lump in the left breast measuring around 4x4cm² (Image 1). There were no palpable ipsilateral axillary lymph nodes. He had a 5 years history of gynaecomastia in the left breast.

CASE 3: Patient was 70 years old and had multiple nodules of variable sizes around nipple and sub areolar regions and towards axillary tail of the right breast [Image 2]. The largest measured approximately 3x3cm². There were 2 palpable ipsilateral axillary lymph nodes. He was also diagnosed to be suffering from fatty liver.

CASE 4: Patient was 65 years old and had lump in the left breast measuring around 5x4cm². There were 3 palpable ipsilateral axillary lymph nodes. The patient also had history of fatty liver.

CASE 5: Patient was 75 years old and presented with a lump in the left breast measuring around 3x2cm². No palpable ipsilateral axillary lymph nodes were found.

The age group of the patients ranged from 55 to 75 years. Most of the cases attended the hospital with the chief complaint of a hard, ill-defined sub areolar breast lump of variable duration ranging from 3 months to 10 months. Although none had family history of breast or ovarian carcinoma, all of them completed their families. All were occasional drinkers. All laboratory and radiological investigations were within normal limits except 2 cases which had fatty liver. All cases presented with left sided breast lumps, except one which had lump on the right breast. Ultrasound was performed in all the cases and revealed a solid breast mass suspicious for malignancy except one with multiple nodules in presentation. Imaging studies were also carried out to rule out any primary focus at other sites. Examination of the lumps revealed, firm nodules of variable sizes with a single case showing ulceration with scanty discharge. All cases were examined for any associated lymphadenopathy and 3 cases revealed ipsilateral axillary lymph nodes enlargement. Nipple retraction was found among all five patients. Modified radical mastectomy with axillary lymph node dissection was performed wherever necessary and samples were sent for histopathological examination.[The case details are summarised in Table 1]

The grossings of mastectomy specimen followed the standard laboratory protocols and slides were prepared. Routine Hematoxylin & Eosin staining was done and examined under light microscope Morphology revealed narrow trabeculae and cords of cells infiltrating the stroma. The cells were arranged one behind the other in a straight line giving the appearance of Indian file pattern [Image 3]. The tumour cells were small, almost uniform in size with scant clear to eosinophilic cytoplasm, round nucleus with vesicular chromatin and inconspicuous nucleoli. Mitosis was infrequent and breast acini or lobules were not identified. In two high histologic grades cases showed frequent mitosis and nuclear pleomorphism with solid alveolar patterns in some foci[Image 4]. Occasional areas showed concentric arrangement of the tumour cells around residual normal mammary structures[Image 5]. The characteristic histologic picture favoured the diagnosis of invasive lobular carcinoma. The lesions were reported in grade on a scale of I to III according to Elston and Ellis modified Bloom Richardson grading system. Surgical margins were negative and dissected axillary lymph nodes demonstrated evidence of disease in 3 cases [image 6]. Evaluation of Estrogen Receptor[ER], Progesterone Receptor [PR] and Human Epidermal Growth Factor Receptor 2[Her2neu] were done according to American Society of Clinical Oncology and Confederation of American Pathologist guidelines¹⁷. On immunohistochemistry, the tumour cells demonstrated strong positivity for ER PR[Image 7] and Her-2/neu negativity for 4 cases and equivocal in one case .

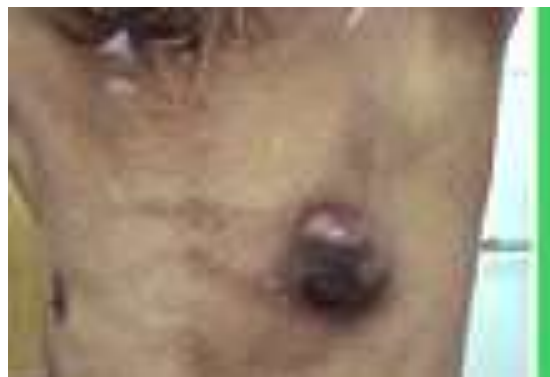

Fig. 1:

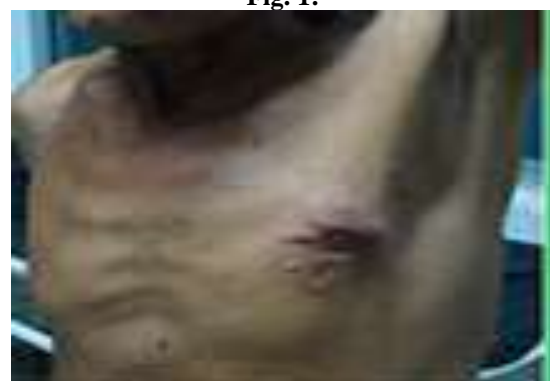

Fig. 2:

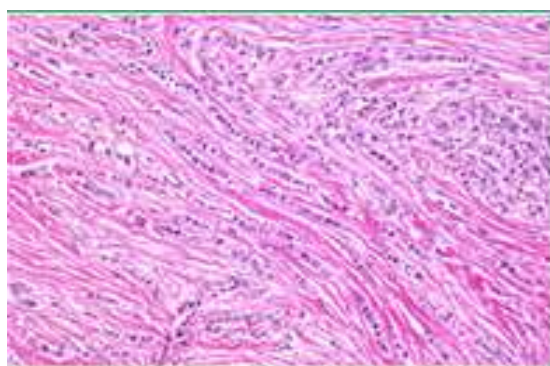


Fig. 3:

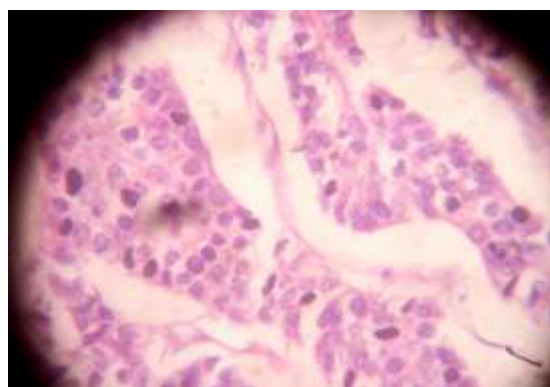


Fig. 4:

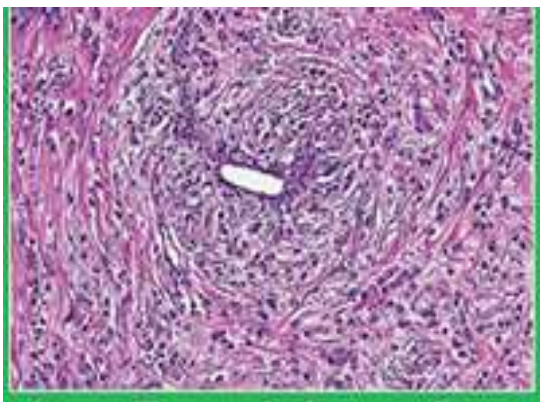


Fig. 5:

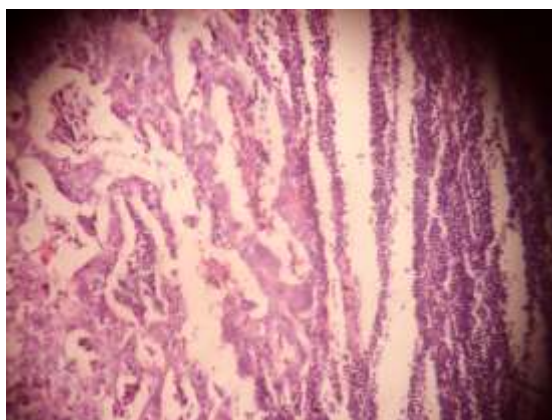


Fig. 6:

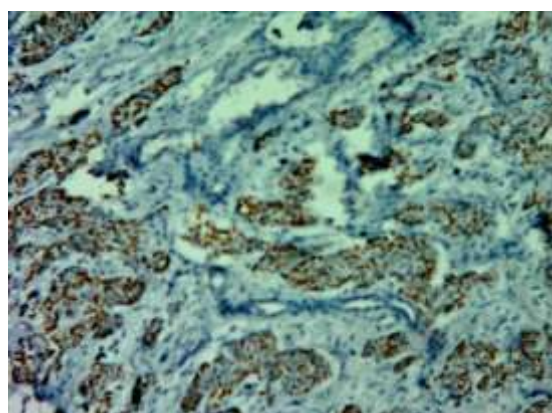


Fig. 7:

Table 1:

S. no.	Patient's Age	Any systemic pathology	Breast involved	Size of lump (cm ²)	Histo grade	Surgical stage	Axillary Lymph node	ER status	PR status	Her-2/neu status
1	55	Left sided undescended testis	Left	4x3	II	II	0	+	+	-
2	60	Gynaecomastia	Right	4x4	III	III	5	+	+	++
3	70	Fatty liver	Left	3x3	III	III	5	+	+	-
4	65	Fatty liver	Left	5x4	III	III	4	+	+	-
5	75	Nil	Left	3x2	II	II	0	+	+	-

ER- Estrogen receptor

PR-Progesterone receptor
Her2/neu- Human Epidermal Growth Factor Receptor
Her2neu++ is equivocal

Discussion

Even though breast carcinoma shows a more common association with female gender with female:male ratio of 100:1⁸, rare cases have been reported to occur in males as an important cause of cancer related death. The typical presentation is that of a firm and painless subareolar mass. Majority of the cases show a preponderance for left breast with less than one percent of cases being bilateral.⁴ One case in our study had multiple nodules instead of single mass which is also a clinical presentation found to be associated with ILC histology in breast cancer of females in our clinical experience.

Many predisposing factors that have been implicated in the development of male breast cancer include hyper-estrogenic state, undescended testes, Klinefelter's syndrome, gynaecomastia, trauma and radiation injury.⁹ Some studies also elucidated etiologies such as genetic mutations, especially BRCA2, and conditions associated with an imbalance between estrogen and testosterone. Certain medications, such as cimetidine^[22], are hypothesized to increase the risk for male breast cancer via an estrogenic mechanism. Testicular infection, injury, or maldescent resulting in a relative deficiency of testosterone have been proposed as possible predisposing factors^[19]. Some environmental factors, such as exposure to heavy industry toxins, have been implicated in the development of male breast cancer^[20]. In our study all the cases of male breast cancer that were encountered had their family completed and none had any family history of breast or ovarian cancer. One case in this study group had undescended testis and second case had long history of gynaecomastia. The age groups ranges from 55-75 years. It has been observed that male breast cancer typically presents with an advanced stage of disease than do women as these tumours are usually superficial and centrally located with a ready access to dermal lymphatics, pectoral fascia and subareolar lymphatic channels thus explaining the advanced disease at presentation.¹⁰ Our study cases presented in stage 2 in two cases and stage 3 in three cases. The risk of axillary lymph node metastasis co-related to the clinical tumour size, histologic grades as reported.¹¹ Invasive lobular cancer is a very rare histopathological type of male breast cancer, as lobular and acinar structures are infrequent in the normal²¹. Male breast Lobular cancer makes up a smaller percentage of breast cancer cases in men (1-2%) than in women (10-15%). The significance of this histology in male breast carcinoma is yet to be known. Studies done by Gayatri Gogoi et al. 2015 found higher percentage of lobular carcinoma [16%] in women than usual from the same institute.¹⁸

In contrast to females with breast cancer, a high proportion of men with carcinoma of the breast have tissue positive for ER and PR.¹² In all cases in our study, ER and PR was positive and Her2neu was negative. Thus, endocrine therapy plays an important role in the management of male breast cancer. Tamoxifen has been seen to be effective in patients without orchiectomy, and following both orchiectomy and adrenalectomy.¹³ Though experience of adjuvant therapy for males with breast cancer is very limited, two studies have reported the benefits of adjuvant chemotherapy in men.^{14,15} However, as the median age of patients presenting with male breast cancer is high and with frequently associated chronic diseases, tamoxifen as an adjuvant treatment may be a favorable option for those unfit for surgery. All our cases were treated by surgery, adjuvant tamoxifen, adjuvant chemotherapy followed by axillary irradiation in three positive nodes. Out of two cases one has completed 5 years of survival after diagnosis who was actually negative for axillary node [3 others yet to complete 5 years of first diagnosis]. The one with axillary node positive stage 3 cancer collapsed within 3 and half years. Many prognostic factors considered in literature include tumor size, histological grade and axillary lymph node status with the latter being the most important prognostic factor seemed to be in our cases too. It would be important to observe what is the advantage in response to therapy in our two node negative cases would be receiving and would be leading survival in contrast to node positive two cases.

Hence, male breast carcinoma although rare warrants the need of always suspected breast lump to be biopsied and sent for histopathological examination. Equally important is the role of pathologist to accurately diagnose this condition by better sampling and vigorously search for any tumour foci and presence of tumour in nodes to properly stage the cancer. Role of IHC is extremely indispensable to find out the presence of hormonal receptor ER, PR and Her2neu and predict the response to hormonal therapy. All cases in our study got the advantage of receiving tamoxifen treatment and observed a better response except one with stage 3 collapsed with 3 and half years of diagnosis. So there is a need of prospective randomized clinical trials addressing the optimal surgical management, adjuvant radiation therapy, hormonal therapy, or chemotherapy for male breast carcinoma. Studies suggest an adjuvant treatment, anti-estrogen therapy seems to be the first line approach in a majority of patients with receptor positive tumours and chemotherapy is reserved for patients with poor prognostic factors.¹⁶

Conclusion

Whether of lobular histology in male breast carcinoma has any advantage? Difficult to comment at this moment but definitely have advantage of adjuvant tamoxifen in its management as it is most likelihood of

being positive in ER, PR study. Much of the knowledge remains to be gained about male breast carcinoma. Majority of information regarding treatment of male breast cancer is retrospective in nature and is derived mainly from small single-institution series; thus, the choice of treatment modalities is generally guided by extrapolation of data from female breast cancer. In regard to the paucity of data and the extreme rarity of the disease carcinoma of male breast should be considered and managed as a distinct entity. It is hoped that a long term multicentric studies for risk factors association and trials will be strategically designed to optimize the treatment of this uncommon disease.

Reference

1. Susanne Briest, Russell Vang, Kyle Terrell, Leisha Emens, and Julie R. Lange. Invasive Lobular Carcinoma of the Male Breast: A Rare Histology in an Uncommon Disease. *Breast Care (Basel)*. 2009 Feb;4(1):36–38.
2. Giordano SH, Cohen DS, Buzdar AU, Perkins G, Hortobagyi GN. Breast carcinoma in men: a population-based study. *Cancer*. 2004;101:51–57.
3. Agrawal A, Ayantunde AA, Rampaul R, Robertson JF. Male breast cancer: a review of clinical management. *Breast Cancer Res Treat*. 2007;103:11–21.
4. Goss PE, Reid C, Pintilie M, Lim R, Miller N. Male breast carcinoma: a review of 229 patients who presented to the Princess Margaret Hospital during 40 years: 1955-1996. *Cancer*. 1999;85:629–639.
5. Carmalt H, Mann L, Kennedy C, Fletcher J, Gillett D. Carcinoma of the male breast: a review and recommendations for management. *Aust N Z J Surg* 1998;68:712–715.
6. Williams W, Powers M, Wagman L. Cancer of the male breast: a review. *J Natl Med Assoc* 1996;88:439–443.
7. Yildirim E, Berberoglu U. Male breast cancer: a 22-year experience. *Eur J Surg Oncol* 1998;24:548–552.
8. Lori Jardines, Sharad Goyal, Paul Fisher, Jeffrey Weitzel, Melanie Royce, Shari B. Goldfarb. Breast Cancer Overview: Risk Factors, Screening, Genetic Testing, and Prevention. June 01, 2015. *Cancer Management*.
9. Sasco AJ, Lowrefels AB, Pasker-de-Jong P. Epidemiology of male breast cancer. A meta-analysis of published case-control studies and discussion of selected etiological factors. *Int J Cancer* 1993;53:538-49.
10. Adami HO, Holmberg L, Malker B, et al. Long term survival in 406 males with breast cancer. *Br J Cancer* 52:9-103.
11. Salvadori B, Saccozzi R, Manzari A, et al. Prognosis of breast cancer in males: An analysis of 170 cases. *Eur J Cancer* 1994;30A:930-5.
12. Ribeiro G. Male breast carcinoma. A review of 301 cases from the Christie Hospital and Holt radium Institute, Manchester. *Br J Cancer* 1985;51:115-9.
13. Aerrigada R, Rutquist LE, Mattson A, Kramar A, Rolstein S. Adequate loco-regional treatment for early breast cancer may prevent secondary dissemination. *J Clin Oncol* 1995;13:2869-78.
14. Bagley CS, Wesley MN, Young RC, et al. Adjuvant chemotherapy in males with cancer of the breast. *Am J Clin Oncol* 1987;10:55-60.
15. Patel HZ, Buzdar AV, Hortobagyi GN. Role of adjuvant chemotherapy in male breast cancer. *Cancer* 1989;64:1583-5.
16. Sushmita Ghoshal, Bhavana Rai, Suresh C Sharma. Breast cancer in males: A PGIMER experience. *Journal of Cancer Research and Therapeutics*, Vol. 1, No. 1, January-March, 2005, pp. 31-33.
17. Hammond ME, Hayes DF, Dowsett M, American Society of Clinical Oncology/College of American Pathologist Guidelines Recommendations for Immunohistochemical Testing of Estrogen and Progesterone Receptors in Breast Cancer. *Journal of Clinical Oncology*, 2010;28:2784-2795.
18. Gayatri Gogoi, M Borgohain, H Saikia, STUDY OF HER2/NEU PROTEIN PATTERN IN OF BREAST CARCINOMA AND CORRELATION WITH VARIOUS PROGNOSTIC PARAMETERS, *Indian Journal of Pathology and Oncology*, October -December 2015,2[4]:265-275.
19. Thomas DB, Jimenez LM, Mc Tiernan A, Rosenblatt K, Stalsberg H, Stembagen A, Thompson WD, Curnen MG, Satariano W, Austin DF, et al. Breast cancer in men: risk factors with hormonal implications. *Am J Epidemiol*. 1992;135:734–748.
20. Cocco P, Figgs L, Dosemeci M, Hayes R, Linet MS, Hsing AW. Case-control study of occupational exposures and male breast cancer. *Occup Environ Med*. 1998;55:599–604.
21. Ouriel K, Lotze MT, Hinshaw JR. Prognostic factors of carcinoma of the male breast. *Surg Gynecol Obstet*. 1984;159:373–376.
22. Sorensen HT, Friis S, Olsen JH, Thulstrup AM, Møller-Jensen L, Linet M, Trichopoulos D, Vilstrup H, Olsen J. Risk of breast cancer in men with liver cirrhosis. *Am J Gastroenterol*.