

Rapid decalcification technique using tissue floatation bath (TFB) in a tertiary care oncology centre

Sandeep Ojha^{1,*}, Amit Haritwal², Ramashankar Patel³, Farah Meenai⁴, Rajesh Chaurasia⁵, Sonam Gupta⁶

¹Assistant Professor, ^{2,4,5}Associate Professor, ³Senior Technician, ⁶Tutor, Chirayu Medical College, Bhopal

***Corresponding Author:**

Email: drsandy0582@gmail.com

Abstract

Background: Decalcification of bone is a very important procedure in pathology especially in an oncology set up for proper staging, chemotherapy response or even in diagnosis of tumors. Objectives- To evaluate the use of tissue floatation bath (TFB) for rapid decalcification of mandibulectomy specimens in an oncology setup.

Materials and Methods: Bony specimens received at pathology department were sliced using bone saw and then placed in 10% formalin at 45 0 C for 4 hours. These sections were then kept overnight in 10% nitric acid at 45 0 C in TFB for decalcification. Decalcification was checked manually next day morning and if decalcification is complete, and then the tissue transferred to tissue processor for routine tissue processing.

Results: Decalcification in tissue floatation bath takes approximately 18-20 hours with better cytomorphological details as compared to routine decalcification process which takes around 7-8 days for complete decalcification.

Conclusion: Tissue floatation bath is a common instrument available in all laboratories performing histopathological examination. Staining quality is comparable and time required for decalcification is improved as compared to routine decalcification technique. It can be used as an alternative to the more expensive microwave technique which requires additional instrument and space. To the best of our knowledge this is the first study using tissue floatation bath for rapid decalcification process.

Keywords: Routine decalcification, Rapid Decalcification, Tissue floatation bath, Bone, Mandibulectomy

Access this article online	
Quick Response Code:	Website: www.innovativepublication.com
	DOI: 10.5958/2394-6792.2016.00044.2

Introduction

Decalcification is a process of complete removal of calcium from bone, teeth and other calcified tissues. It is a very important routine procedure that is employed in nearly all histopathology laboratories but is a very time consuming process and may lead to delay in management of patients. Decalcification is performed to assure that the specimen is soft enough to allow cutting with the microtome knife, so that to avoid damage to tissue as well as to knife.

Decalcification is carried out by various agents which either form soluble calcium salts (acids) or by chelating the calcium ions¹. Strong acids decalcify tissue faster but can cause deterioration of stainability of tissue section and it increases with acidity of solution and length of decalcification periods^{2,3}. Several factors influence the rate of decalcification including concentration and volume of decalcifying agent, temperature at which reaction takes place, size of the specimen, and use of microwave and solution agitation¹. Thus, the speed of decalcification can be

fastened. More concentrated acidic solution and microwave can produce rapid decalcification but damages the morphology of the tissues^{4,5}. High temperature can expedite the decalcification process but temperature of more than 60°C can cause charring of tissues.⁵

Decalcification is particularly important in an oncology setup where it is essential for diagnosis of primary bone tumors and involvement of bone by external malignancy like squamous carcinoma or other tumors. It is also important to know the extent of bone involvement along with the knowledge of margin status. This helps in knowing the staging, completeness of surgery and need for further management like radiotherapy or chemotherapy. Many treatment protocols for bone tumors require a report on an entire slice/grid of resected bone to allow assessment of the benefit or otherwise of preoperative drug treatment.

These all requires a good cellular morphology and a quick result to allow rapid therapeutic intervention for optimal patient care.

Heating is also a method known to accelerate the decalcification process^{1,6} and in this study we used tissue floatation bath instead of microwave for rapid decalcification of bone using heat as a source to reduce time of decalcification.

The aim of the present study was to evaluate and compare decalcification of bone by routine method and by using tissue floatation bath with special attention to duration of decalcification and nuclear details.

In India, oral squamous cell carcinoma is one of the most common malignancies and in our institute also we receive many mandibulectomy specimens for histopathological examination. Sections from underlying mandibular bone provide internal control to look for nuclear and cytoplasmic details of squamous carcinoma.

Many studies are there in literature evaluating the role of microwave in rapid decalcification⁴⁻⁹, but to the best of our knowledge no study has described the role of TFB for the same.

Materials and Methods

This study was performed at pathology department of a tertiary care oncology centre in India. In this study we used TFB as a heat source for rapid decalcification on bony cut margin and underlying bone of mandibulectomy specimens. We also compared the decalcification using TFB with conventional decalcification method with special reference to duration of decalcification and nuclear details.

In this study, a total of twenty hemimandibulectomy specimens were studied. Twenty Sections each of anterior bony cut margin and underlying bone were taken. Bony tissues were sliced using bone saw with a uniform thickness of 2-3 mm and a parallel slice of bone from the same site was taken to prepare another set of specimens. One set of specimens (20 sections of anterior bony cut margins and 20 of underlying bone) was processed through routine decalcification and another set was kept in TFB for rapid decalcification. Thus, we ensured that the two sections under comparison were from the same bone and from the same site. This was done to eliminate bias from other factors that can affect the decalcification process like age and type of bone.

These tissues were then placed in 10% formalin for 4 hours in order to achieve proper fixation. After removing from formalin, these tissues were placed in running water for 30 minutes to remove excess formalin. After that tissues were kept in decalcifying solution (10% nitric acid).

In the routine decalcification method, tissues were placed in a decalcifying agent at room temperature with change of solution at regular intervals till the decalcification is completed. In the method using tissue floatation bath, bony tissues in cassettes are placed in the decalcifying agent in a metal container which was then kept overnight in preheated tissue floatation bath with temperature maintained at around 45°C. The duration of decalcification and nuclear details of the tissue were noted, compared and tabulated. In both the methods, after completion of decalcification, the tissues were washed using distilled water for 30 minutes and were transferred to ammonia solution to neutralize the remaining acids. Tissues were then subjected to routine processing. Sections were then stained with hematoxyline and eosin stain and submitted for reporting. The stained sections of decalcified bone were assessed for the quality of staining and preservation of nuclear details.

Results

(Table 1) In this study, the average time required for decalcification was approximately 7-8 days by routine decalcification technique while with tissue floatation bath technique the time taken for decalcification reduced to 18- 20 hours for the same set of specimens.

The stained sections of the processed decalcified bone were assessed for the staining quality and preservation of the cytoplasmic and nuclear details. In our study the cellular architecture of the tissue was comparable in both techniques. Decalcification with TFB technique provides a better nuclear staining and nucleo- cytoplasmic differentiation of the stained section with a lesser shrinkage of tissue probably because of lesser duration of contact with the acid. Yellowishness of the stained section was also significantly reduced thus leading to better interpretation. Morphology of soft tissue squamous cell carcinoma was also better preserved then that with conventional methods.



Fig. 1: Showing a common tissue floatation bath showing a metallic container holding the decalcifying fluid

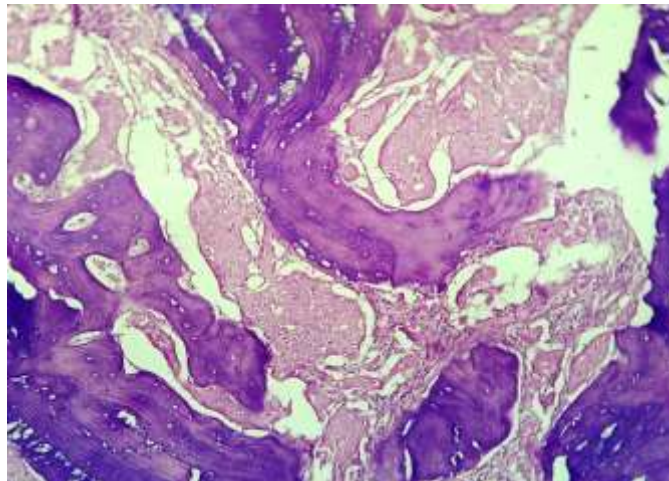


Fig. 2: Showing section of mandibulectomy showing bony trabeculae and a squamous carcinoma infiltrating the bone (100 X)

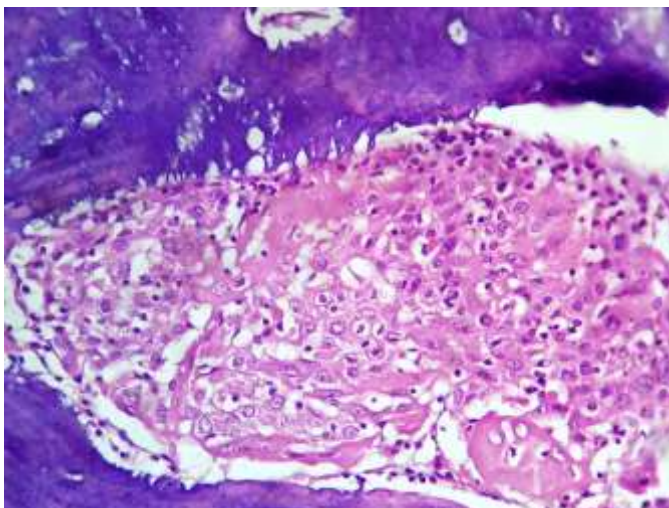


Fig. 3: High power of same section showing preserved nuclear details of squamous carcinoma and decreased eosinophilia (400 X)

Table 1: Comparison of cellular morphology of tissue processed by conventional and TFB method

Parameters	Routine method	TFB method
Yellowishness of tissue section	Present	Significantly reduced
Tissue shrinkage	Present	Less than routine method
Nuclear details	Average	Good
Cytoplasmic eosinophilia	Present	Reduced
Nucleo- cytoplasmic contrast	Blurred	Better
Decalcification time	8-10 days	1 day

Discussion

Decalcification is a routine procedure and its aim is to remove calcium salts while preserving the normal architecture of the cells. Bones are one of the important specimen of decalcification in an oncology institute, but other specimens, such as calcified soft tissue tumors, calcified lymph nodes etc. also require this process.

Since the start of decalcification procedure, many studies were conducted for any advances in reagents or procedure with very little change in methodology. This is limited to some additional decalcification solutions and microwave-assisted decalcification. The duration of decalcification is very important for timely diagnosis and management of the patients. In this study we tried decalcification on mandibulectomy sections as they form a majority of specimens in an oncology institute and management of patient also depends on the fast comments on bony cut margins and status of underlying bones. Involvement of underlying bone by squamous carcinoma also requires adequate preservation of the tumor component. Thus, it is very essential to have a correct balance between speed and quality of processing so that ultimate goal of quality patient care is achieved.

Heat is known to expedite the rate of decalcification as it increases the rate of diffusion and increases rate of chemical reaction⁹. In a study performed by Verdenius et al¹⁰ it was observed that time required for decalcification was reduced with increase in temperature. In a study done by Supriya Nikita Kapila et al¹¹, they have used hot air oven and magnetic stirrer for rapid decalcification process with significant reduction in time of decalcification and improvement in quality of staining. In our study also, there was shortening of time required for decalcification when tissues were continuously exposed to a controlled temperature of 45°C. When comparing to conventional method of decalcification which require 7-8 days for complete decalcification, our method using TFB require only 18-20 hours for complete decalcification.

Various studies are in literature describing the role of microwave in rapid decalcification. In a study done by R Sangeeta et al⁴, microwave was used as for expediting the decalcification process which takes around 2 days for condyles to get decalcified. Pitol et al⁵ also mentioned the use of domestic microwave in

decalcification with similar results as R Sangeeta et al. It was also suggested that domestic microwave cannot be effectively used for decalcification due to absence of temperature control and temperature beyond 60°C can damage the tissue^{9,12}.

These all studies require a separate instrument for this process which require additional space and cost constraints. In our study we have used the tissue floatation bath which is present in nearly every histopathology laboratory which minimizes the requirement for a separate instrument. Also this instrument has an adjustable temperature control up to 110°C which enables the adequate temperature control throughout the process. In our study it takes about 18-20 hours for decalcification process which is slightly better to that in above mentioned studies.

This instrument which is readily available in all laboratories, fitted with a temperature control provides a rapid decalcification which is comparable to other techniques in respect of duration and staining quality and can be used as an alternative to other methods for decalcification.

Conclusion

The TFB method decalcifies bony tissues much faster than the routine method and is available in nearly all histopathology laboratories. Tissue preservation and staining efficacy is comparable to routine decalcification. It is to emphasize that no separate instrument is required for decalcification process as in microwave technique especially at a tertiary care centre with a lesser workload.

Thus, the TFB is rapid technique as compared to routine methods and is cheaper and easily available technique then microwave with comparable staining quality and preservation.

To the best of our knowledge, this is the first study demonstrating the use of tissue floatation bath in rapid decalcification of bony tissues. Also this can be used for other calcified or bony specimens and further studies are required.

Conflicts of interest: There are no conflicts of interest.

References

1. Callis GM, Bancroft JD. Theory and Practice of Histological Techniques. 6th ed. Edinburgh: Churchill Livingstone; 2008; p. 338-360.
2. Prasad P, Donoghue M. A comparative study of various decalcification [4] techniques. *Indian J Dent Res.* 2013;24:302-08.
3. Sanjai K, Kumarswamy J, Patil A, Papaiah L, Jayaram S, Krishnan L. Evaluation and comparison of decalcification agents on the human teeth. *J Oral Maxillofac Pathol.* 2012;16(2):222-27.
4. Sangeetha R, Uma K, Chandravarkar V. Comparison of routine decalcification [6] methods with microwave decalcification of bone and teeth. *J Oral Maxillofac Pathol.* 2013;17(3):386-91.
5. Pitol DL, Caetano FH, Lunardi LO. Microwave-induced fast decalcification of [8] rat bone for electron microscopic analysis: an ultrastructural and cytochemical study. *Braz Dent J.* 2007;18(2):153-57.
6. Roncaroli F, Mussa B, Bussolati G. Microwave oven for improved tissue fixation and decalcification. *Pathologica* 1991;83:307-10.
7. Mathai AM, Naik R, Pai MR, Rai S, Baliga P. Microwave histoprocessing versus conventional histoprocessing. *Ind J Pathol Microbiol* 2008;51:12-6.
8. Keithley EM, Truong T, Chandranait B, Billings PB. Using the microwave oven for decalcification of human temporal bones. *Newsletter of the NIDCD National Temporal Bone, Hea Balance Pathol Res Registry* 2001;9:1-5.
9. Culling CFA, Allison RT, Barr WT. Hard tissue. In *Cellular Pathology Technique.* 4th ed. London; Butterworths: 1985. pp. 408-17.
10. Verdenius HHW, Alma L. A quantitative study of decalcification methods in histology. *J Clin Path.* 1958;11:229-36.
11. Supriya Nikita Kapila, Srikant Natarajan, Karen Boaz, Jay Ashokkumar Pandya, Shanmukha Raviteja Yinti. Driving the Mineral out Faster: Simple Modifications of the Decalcification Technique. *Journal of clinical and diagnostic research.* 2015;9:ZC93-ZC97.
12. Chaudhari K, Chattopadhyay A, Dutta SK. Microwave technique in histopathology and its comparison with the conventional technique. *Indian J Pathol Microbiol.* 2000;43(4):387-94.