



## Case Report

# Recurrent chondrosarcoma of skull in a 15-year-old patient

Vikas Kalashiya<sup>1</sup>, Tanima Mandal<sup>1\*</sup>, Ravi Shankar Prasad<sup>2</sup>

<sup>1</sup>Dept. of Pathology, Institute of Medical Sciences, Banaras Hindu University, Varanasi, Uttar Pradesh, India

<sup>2</sup>Dept. of Neurosurgery, Institute of Medical Sciences, Banaras Hindu University, Varanasi, Uttar Pradesh, India



### ARTICLE INFO

#### Article history:

Received 31-07-2023

Accepted 28-09-2023

Available online 11-12-2023

#### Keywords:

Chondrosarcoma

Tumour

### ABSTRACT

Chondrosarcoma is rare condition affecting the head and neck region. Here we report a case of in a 15-year old male patient presenting with growth behind the right ear that recurred following radiotherapy and resection. The lesion was treated by re excision of tumour followed by reconstruction and chemotherapy. Histopathological examination revealed chondrosarcoma grade III. The case report describes a tumour which is rare in young adults as well as in location. The tumour also upgraded from Chondrosarcoma grade II in the first resection to Chondrosarcoma grade III in the recurrence.

This is an Open Access (OA) journal, and articles are distributed under the terms of the [Creative Commons Attribution-NonCommercial-ShareAlike 4.0 License](https://creativecommons.org/licenses/by-nc-sa/4.0/), which allows others to remix, tweak, and build upon the work non-commercially, as long as appropriate credit is given and the new creations are licensed under the identical terms.

For reprints contact: [reprint@ipinnovative.com](mailto:reprint@ipinnovative.com)

## 1. Introduction

Chondrosarcoma is a malignant neoplasm characterized by formation of cartilaginous matrix. It accounts for about 20% of all the malignant bone tumours. Chondrosarcoma of the head and neck region is a rare entity representing approximately 0.1% of all head and neck neoplasm.<sup>1</sup> The maxilla is the most affected bone and usually has slow growth, but it can be locally aggressive with a high rate of recurrence. Other primary sites in the head and neck are the jaw, nasal cavity and maxillary sinus.<sup>2,3</sup>

## 2. Case Report

15-year-old male patient from Varanasi presented with a large swelling behind the right ear for 9 months. Previously the patient was symptom free. The swelling increased gradually over the next 2 months. Swelling was not associated with pain, fever, ulceration, similar swelling over other site of body. He was initially treated outside with Single Fraction (6Gy) Radiotherapy followed by resection

of mass in July 2021. Histopathological diagnosis was given as Chondrosarcoma WHO grade II.

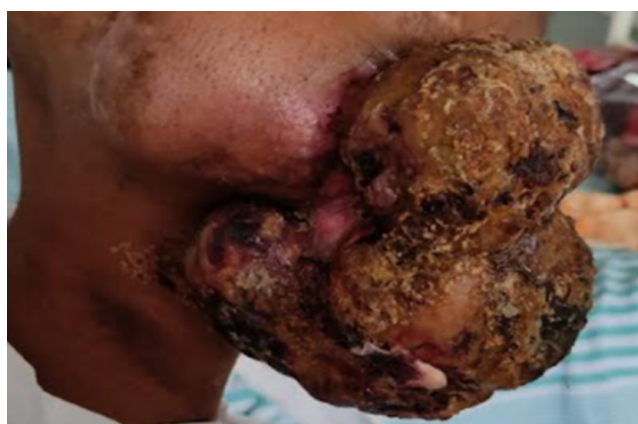One month after this he presented with discharge from the drain site at the skull followed by rapid painless growth of the swelling in the next three months.

The patient presented at IMS, BHU with a 16x14 cm irregular bosselated greyish brown mass in the right retro-auricular area involving parieto-occipital region (Figure 1). CT scan showed heterodense lesion of right posterior parieto-occipital region with intracranial and extra cranial calvarial extension (Figure 2). Lesion was osteolytic, destroying both outer and inner table of bone, with spickled area of calcification in extracalvarial portion. Intracranial portion was hyperdense and caused local mass effect without any gross midline shift. 3D CT showed Involvement of right parieto occipital bone (Figure 3) and CT angio showed no major feeder vessel (Figure 4). Patient was scheduled for debulking of the tumour followed by reconstruction and radiotherapy. The specimen was submitted in 3 containers. The specimen was partially skin covered mass ranging in size from 11x11x8 cm to 2.5x2x1 cm received in multiple pieces. Hence, margins

\* Corresponding author.

E-mail address: [tanima.mbbs@gmail.com](mailto:tanima.mbbs@gmail.com) (T. Mandal).

could not be inked. The cut surface was gelatinous with pin point areas of calcification and haemorrhage. Histopathology showed an infiltrating tumour with lobules of cartilage and areas of necrosis. Tumour cells are round to oval with nuclear hyperchromasia, moderate to severe nuclear pleomorphism, irregular nuclear membrane and scanty cytoplasm (Figures 5, 6 and 7). No osteoid formation was noted in tumour. Atypical mitosis was also noted. Tumour was infiltrating the overlying skin however margins could not be commented upon as the tissue was received in multiple pieces. The final diagnosis was given as Chondrosarcoma WHO Grade III. Pathologic Stage Classification (pTNM) according to AJCC 8<sup>th</sup> edition was y pT2 pN not assigned as no nodes submitted pM not applicable.



**Figure 1:** Bosselated mass in the parieto occipital region of the patient

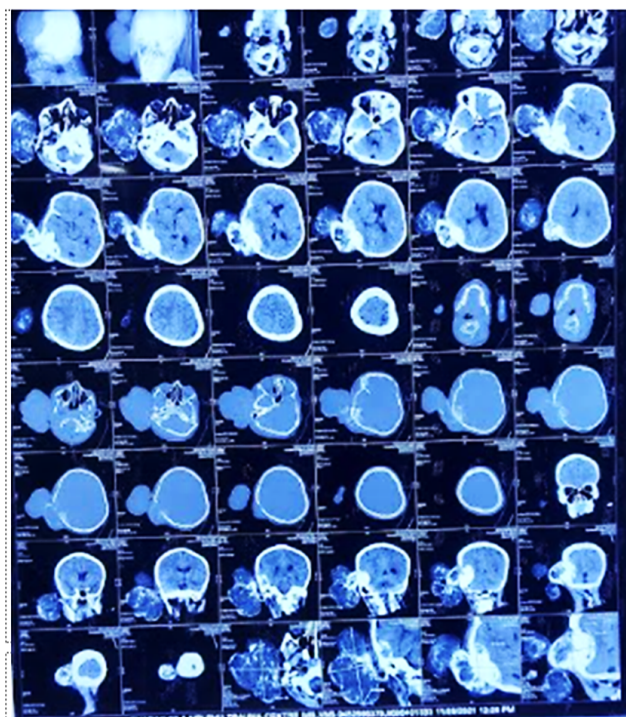
### 3. Discussion

Chondrosarcoma of the head and neck is a rare entity which includes only 1-3% of all chondrosarcoma cases. Chondrosarcoma is most common among the third and fifth decade of life.<sup>1</sup>

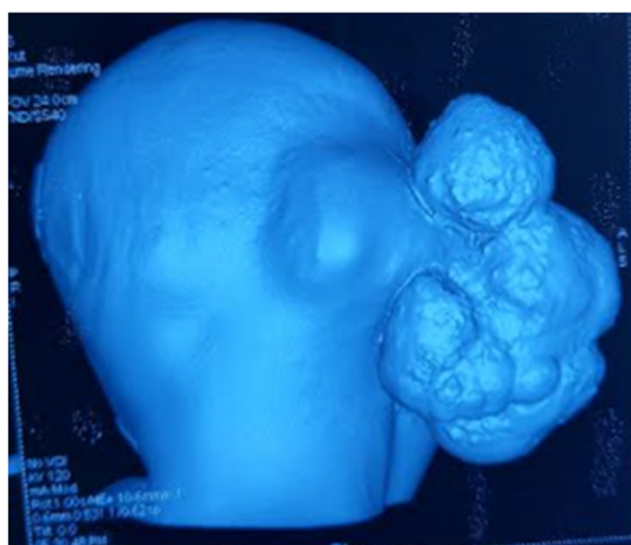
It is extremely rare for this tumour to occur in young adults and only <7% of all chondrosarcoma occur in patients below 21 years of age.<sup>4</sup>

According to the 2020 WHO chondrosarcoma are divided into locally aggressive and malignant categories. Locally aggressive variants include Chondromatosis NOS and Atypical Cartilaginous Tumour. Malignant variants include Grade I, II, III chondrosarcoma, Clear cell chondrosarcoma, Periosteal chondrosarcoma, Dedifferentiated chondrosarcoma and Mesenchymal chondrosarcoma.

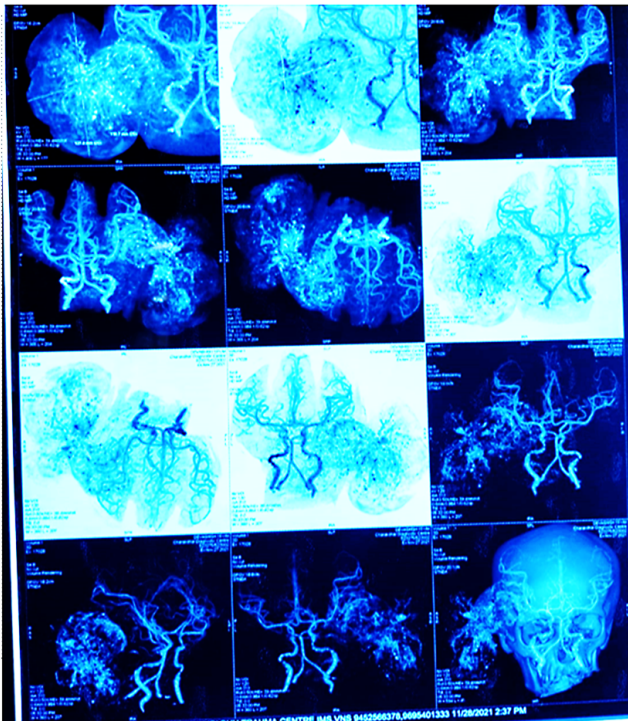
Chondrosarcomas are classified into three grades based on the differences in cellularity, mitotic activity, nuclear pleomorphism and cellular atypia.



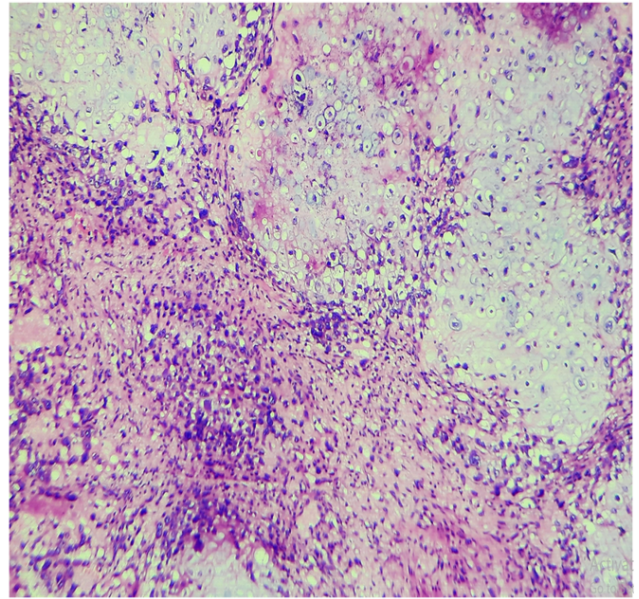
**Figure 2:** CT scan of head shows heterodense lesion of Right posterior parieto-occipital region with intracranial and extra cranial calvarial extension



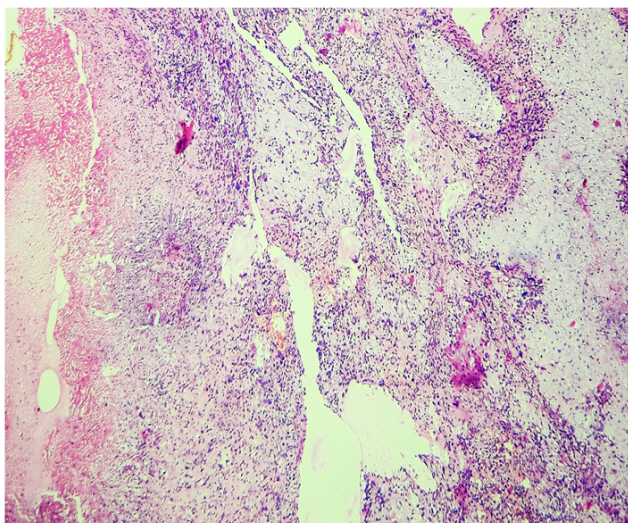
**Figure 3:** 3D CT of lesion



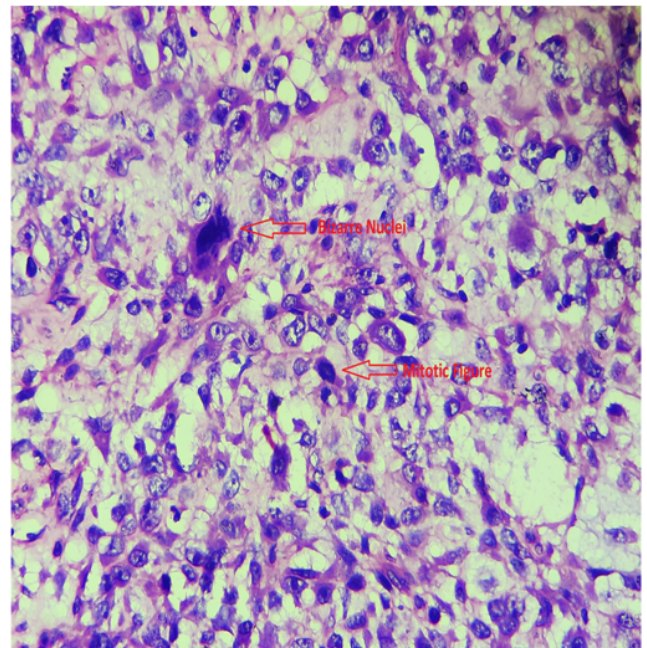
**Figure 4:** CT angio show absence of any major feeder vessels



**Figure 6:** Tumour showing cartilaginous differentiation, high cellularity and presence of necrosis (100x view)



**Figure 5:** Tumour showing cartilaginous differentiation, high cellularity and presence of necrosis (40x view)



**Figure 7:** Tumour showing marked nuclear pleomorphism, multinucleation, bizarre nuclei, and mitotic figures

The main prognostic factors for chondrosarcoma are surgical resection, stage, grade and primary site.<sup>1</sup> The mesenchymal and dedifferentiated forms of chondrosarcoma usually have poor prognosis. Tumour recurrence is relatively common and usually occurs due to an incomplete resection of the tumour. It also may be due to the local spread of the disease. Local recurrence rate of Grade III chondrosarcoma is 26%.<sup>5</sup> Arlen et al. described 10 recurrences out 18 treated patients.<sup>3</sup>

It is noted that in 10% of cases recurring chondrosarcoma a progression to a higher grade can be seen.<sup>6</sup>

The reported 5-year survival rate of grade III chondrosarcoma is 31-77%.<sup>5</sup> However, chondrosarcoma with axial localization have significantly lower survival rate than extremity chondrosarcoma.<sup>7,8</sup> Arlen et al. described 10 recurrences out 18 treated patients.<sup>3</sup> Study conducted by Mark et al. showed that only one of the seven patients considered to have high grade chondrosarcoma was rendered disease free.<sup>2</sup>

#### 4. Conclusion

Chondrosarcoma of head and neck region is itself a rare tumour and its occurrence in young adults is even rarer. This tumour also shows increase in grade from II to III.

#### 5. Source of Funding

None.

#### 6. Conflict of Interest

None.

#### References

1. Quevedo FC, Quevedo FB, Neto JCB, Ferreira EN, Carraro DM, Soares FA, et al. Case report: Chondrosarcoma of the head and neck. *Hum Pathol Case Rep.* 2017;7:4–7.
2. Mark RJ, Tran LM, Sercarz J, Fu YS, Calcaterra TC, Parker RG. Chondrosarcoma of the head and neck. The UCLA experience, 1955-1988. *Am J Clin Oncol.* 1955;16(3):232–7.
3. Arlen M, Tollefsen HR, Huvos AG, Marcove RC. Chondrosarcoma of the head and neck. *Am J Surg.* 1970;120(4):456–60.
4. Gambarotti M, Righi A, Picci P, Bertoni F, Manfrini M, Donati DM, et al. Paediatric chondrosarcomas: a retrospective review of 17 cases. *Histopathology.* 2016;68(7):1073–8.
5. Angelini A, Guerra G, Mavrogenis AF, Pala E, Picci P, Ruggieri P, et al. Clinical outcome of central conventional chondrosarcoma. *J Surg Oncol.* 2012;106(8):929–37.
6. Brien EW, Mirra JM, Kerr R. Benign and malignant cartilage tumors of bone and joint: their anatomic and theoretical basis with an emphasis on radiology, pathology and clinical biology. I. The intramedullary cartilage tumors. *Skeletal Radiol.* 1997;26(6):325–53.
7. Duchman KR, Lynch CF, Buckwalter JA, Miller BJ. Estimated cause-specific survival continues to improve over time in patients with chondrosarcoma. *Clin Orthop Relat Res.* 2014;472(8):2516–25.
8. Coşkun HS, Erdoğan F, Büyükceran İ, Dabak N. Evaluation of prognostic factors affecting survival in chondrosarcoma treatment and comparison with literature. *Jt Dis Relat Surg.* 2022;33(2):440–8.

#### Author biography

**Vikas Kalashiya**, Assistant Professor

**Tanima Mandal**, Pathologist

**Ravi Shankar Prasad**, Professor

**Cite this article:** Kalashiya V, Mandal T, Prasad RS. Recurrent chondrosarcoma of skull in a 15-year-old patient. *Indian J Pathol Oncol* 2023;10(4):413-416.