

Content available at: <https://www.ipinnovative.com/open-access-journals>

Indian Journal of Pathology and Oncology

Journal homepage: www.ijpo.co.in

Case Report

Giant lipoma of thigh – Case report of rare tumour

Bijan Kumar Saha^{1,*}, Kaushik Saha¹, Abhishek Jaiswal²

¹Tata Main Hospital, Jamshedpur, Jharkhand, India

²MTMH Cancer Hospital, Jamshedpur, Jharkhand, India



ARTICLE INFO

Article history:

Received 17-06-2023

Accepted 17-08-2023

Available online 27-09-2023

Keywords:

Giant lipoma

Soft tissue tumour

ABSTRACT

Lipomas are tumours which arise from fat tissues and are most common soft tissue tumours. When lipomas turn malignant, they are known as liposarcoma. Lipomas of length greater than 10cm or weight greater than 1000 grams is defined as giant lipoma. Lipomas are mostly asymptomatic at presentation, however when enlarged they can cause symptoms like pain, difficulty in walking due to compression of underlying neurovascular structures. A male patient aged 65 years presented with non-painful swelling in the left thigh which gradually increased in size over last 6 months. The patient did not have any symptoms due to swelling. On examination the swelling was measured 20x15 cm not fixed to skin or underlying bone or soft tissues. No inguinal lymph node was palpable. Contrast Enhanced Magnetic Resonance Imaging (CEMRI) of thigh showed a well circumscribed fat enhanced lesion in the anterior compartment of the left thigh which measures approximately 10.4 x 12.5 x 21.4 cm. The mass lesion was abutting & medially displacing the femoral neurovascular bundle without encasement. Core biopsy from lesion showed adipocytes with background myxoid stromal and skeletal tissue. No cellular pleomorphism mitosis or increased vascularity is evident. Patient underwent excision of tumour with intact capsule under GA via longitudinal elliptical incision. Final histopathology was reported as mature adipocyte separated by thin fibrous septa suggestive of lipoma without any evidence of lipoblasts or atypical nuclear cells. Patient does not have any recurrence after one year of follow up. Surgical excision with intact capsule is treatment of choice for lipoma. In giant lipomas malignant transformation to liposarcoma should be suspected. On imaging malignant transformation is suspected with characteristics like solid component, haemorrhage, infiltration into neurovascular structures which is confirmed on final histopathology report after excision.

This is an Open Access (OA) journal, and articles are distributed under the terms of the [Creative Commons Attribution-NonCommercial-ShareAlike 4.0 License](https://creativecommons.org/licenses/by-nc-sa/4.0/), which allows others to remix, tweak, and build upon the work non-commercially, as long as appropriate credit is given and the new creations are licensed under the identical terms.

For reprints contact: reprint@ipinnovative.com

1. Introduction

Soft tissue tumours arise from mesenchymal cells. Lipoma is the most common soft tissue tumour which constitutes to around 16% of all mesenchymal tumours.¹ Depending upon location they can be classified (I) Subcutaneous or subfascial (II) Intermuscular or intramuscular (III) Visceral which can be located at serosal or sub-serosal location.^{2,3} Lipomas most commonly occur in trunk and upper extremities. Usually, patients with lipoma present as a small swelling

however in some cases they can rapidly increase in size which should arouse suspicion of lipoma turning malignant i.e., liposarcoma.⁴ Lipomas are more common in females than males as female body has greater amount of fat. They occur most commonly between age 40–60 years.^{5,6} Lipomas of diameter greater or equal 10 cm in diameter in one dimension or weight equal or greater than 1000 grams is defined as giant lipoma.⁷ Patients with giant lipoma usually present as asymptomatic swelling however when enlarged, they can compress of surrounding neurovascular bundle causing symptoms like pain, difficulty in walking, lymphedema.^{8,9} Surgical Case Report (SCARE) guidelines

* Corresponding author.

E-mail address: sahabijan2@gmail.com (B. K. Saha).

were used preparing this case report.¹⁰

2. Presentation of Case

A male patient aged 65 years with no co-morbidities presented with painless swelling in the thigh which gradually increased in size over last 6 months. The patient did not have any symptoms due to swelling. On examination the swelling was measured 20x15 cm, mobile, had smooth surface, firm in consistency, not fixed to skin or underlying bone or soft tissues (Figure 1). No inguinal lymph node was palpable. CEMRI of thigh showed a well circumscribed fat enhanced lesion noted in the anterior compartment of the left thigh which measures approximately 10.4 cm (AP)x 12.5 cm (W)x 21.4 cm (CC) (Figure 2 a & b). Within this mass lesion – thin T2 hypointense septa noted in medial aspect which is showing enhancement on postcontrast scan. The proximal extension of the mass lesion is approximately 6 cm below the hip joint. The caudal limit of the mass lesion is approximately 14 cm above the knee joint level. No enhancing soft tissue component noted within it. No internal hemorrhage seen. The fat containing mass lesion is abutting & medially displacing the femoral neurovascular bundle. It has well-defined fat plane with it. No vascular encasement noted. The posterior extension of the mass lesion is abutting the anteromedial cortex of the femur. No abnormal marrow signal changes seen in the visualized bones, suggestive of Lipoma of anterior compartment of thigh. Core biopsy from lesion showed adipocytes with background myxoid stromal and skeletal tissue with well fined capsule. No cellular pleomorphism mitosis or increased vascularity is evident. Patient underwent excision of tumour with intact capsule under GA preserving underlying muscles. Longitudinal elliptical incision was used to excise the tumour and the defect on thigh was primarily closed after placing a suction drain. Medially a part of tumour was adherent to femoral vessels. The tumour was meticulously dissected away from femoral vessels and femoral vessels was preserved (Figures 3 and 4). Patient post-operative recovery was uneventful. Patient was discharged on third day after surgery and drain was removed on seventh day after surgery. Final histopathology was reported as mature adipocyte with well-defined capsule separated by thin fibrous septa suggestive of lipoma without any evidence of lipoblasts or atypical nuclear cells (Figures 5 and 6). 20 sections were taken from tumour, 1 cm apart. IHC with MDM2 was not done on tumour specimen, which is a marker of well differentiated lipoma. Patient does not have any recurrence after 1 year of follow up.

3. Discussion

Lipomas are most common benign soft tissue tumours which arise from fat tissue. Lipomas can be managed conservatively or excised. Surgical excision is done mainly

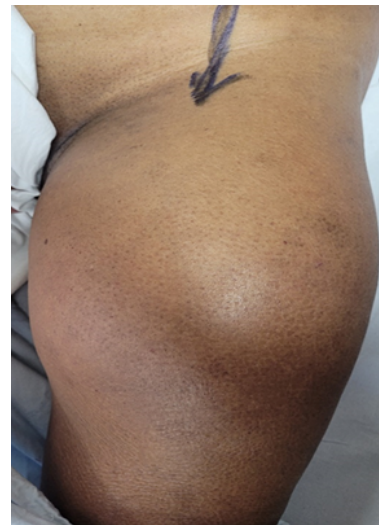

Fig. 1: Clinical picture of lipoma in the left thigh

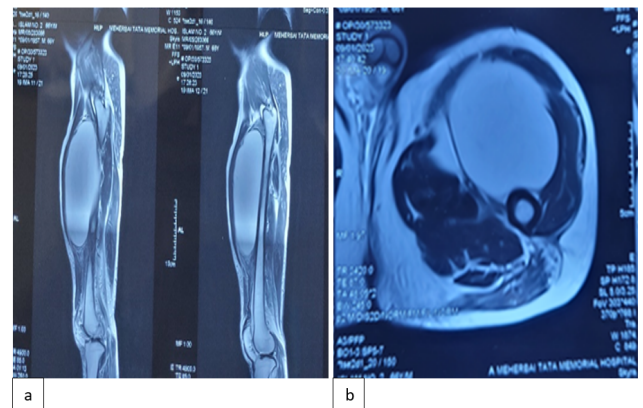


Fig. 2: CEMRI picture a) Sagittal b) Axial

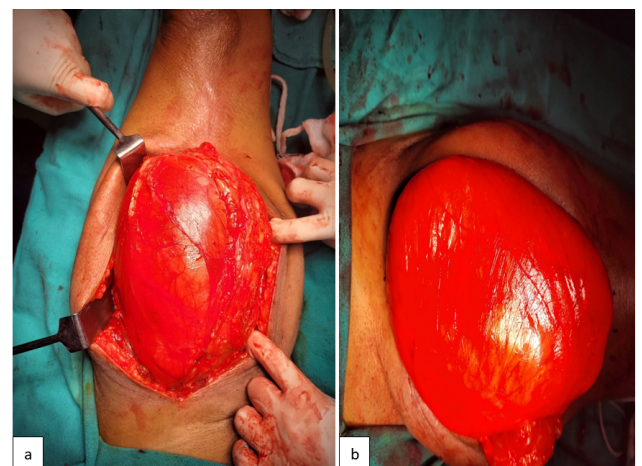


Fig. 3: a and b: Lipoma was excised using vertical incision and intact capsule

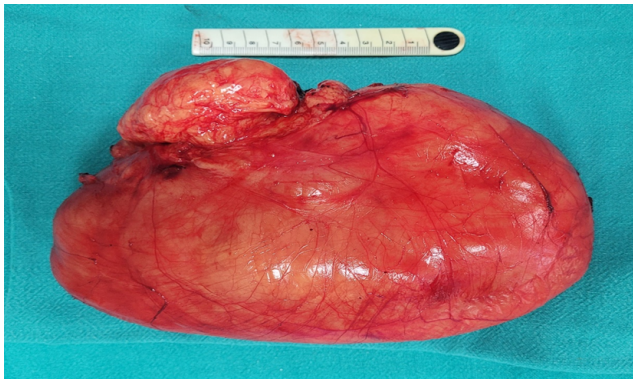


Fig. 4: Gross specimen of tumour after excision

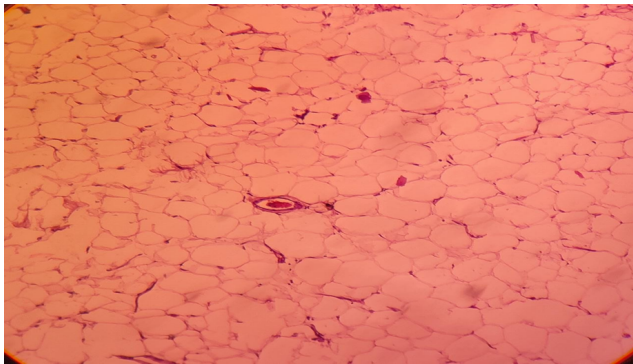


Fig. 5: 20x magnification HE stained section shows lobules of mature adipose tissue separated by thin fibrovascular septa

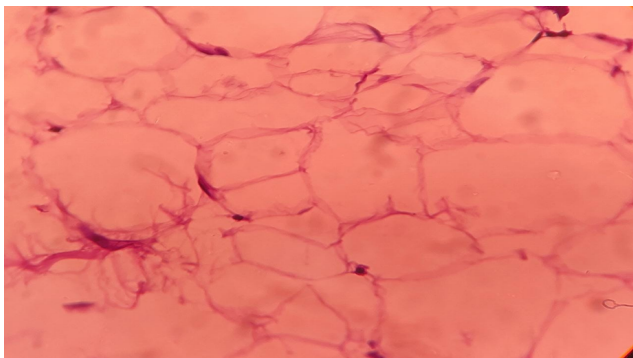


Fig. 6: 40x magnification of HE stained slide shows histologically benign adipocytes

for cosmesis or ruling out malignant transformation to liposarcoma. According to Kransdorf et al.¹¹ primary excision of giant lipomas can be done without a pre-operative biopsy if imaging is suggestive of benign lipoma like thin septa, homogenous echogenicity, and well-defined capsule. Transformation to liposarcoma is suspected when there is history of rapid increase in size swelling. Preoperative biopsy is indicated in these patients after imaging.⁶ Liposarcoma is suspected when imaging shows

large size, heterogeneity, irregularly thickened septa, high degree of vascularity, solid areas with low-fat content. In our patient though imaging was suggestive of benign lipoma, a pre-operative biopsy was done to rule out malignancy because of large size and tumour infiltration into femoral vessels medially. In case of liposarcoma excision with curative margin is indicated. Pre-operative radiotherapy can be used to reduce the volume and better delineation of disease to help in achieving curative margins avoiding amputation and doing limb salvage surgery preserving neurovascular structures. Adjuvant radiotherapy in form of EBRT or brachytherapy is indicated in liposarcomas of size greater than 5cm, deep-seated tumours or having close margin or positive margin post excision.^{12,13}

4. Conclusion

Lipomas of size greater than 10 cm in one dimension or weight heavier than 1000 grams is defined as giant lipoma. Imaging should always be done before excision to rule out malignant transformation. Pre-operative biopsy can be avoided in case imaging shows classical finding of benign disease. Excision with 1 cm margin should be done to avoid local recurrence. Drains can be placed to prevent seroma or haematoma formation following excision. Diagnosis of giant lipoma is made on histopathology report after excision after ruling out malignancy.

5. Source of Funding

None.

6. Conflict of Interest

None.

References


1. Zografos GC, Kouerinis I, Kalliopi P, Karmen K, Evangelos M, Androulakis G, et al. Giant lipoma of the thigh in a patient with morbid obesity. *Plast Reconstr Surg*. 2002;109(4):1467–8.
2. Bjerregaard P, Hagen K, Daugaard S, Kofoed H. Intramuscular lipoma of the lower limb. Long-term follow-up after local resection. *J Bone Joint Surg Br*. 1989;71(5):812–5.
3. Davis C, Gruhn J. Giant lipoma of the thigh. *Arch Surg*. 1967;95:1–6.
4. Abdulsalam T, Osuafor CN, Barrett M, Daly T. A giant lipoma. *BMJ Case Rep*. 2015;2015. doi:bcr2015212030.
5. Phalen GS, Kendrick JI, Rodriguez JM. Lipomas of the upper extremity. *Am J Surg*. 1971;121(3):298–306.
6. Salam GA. Lipoma excision. *Am Fam Phys*. 2002;65(5):901–5.
7. Sanchez MR, Golomb FM, Moy JA, Potozkin JR. Giant lipoma: case report and review of the literature. *J Am Acad Dermatol*. 1993;28(2 Pt 1):266–8.
8. Benedetto GD, Aquinati A, Astolfi M, Bertani A. Giant compressing lipoma of the thigh. *Plast Reconstr Surg*. 2004;114(7):1983–5.
9. Guerrissi J, Klersfeld D, Sampietro G, Valdivieso J. Limitation of thigh function by a giant lipoma. *Plast Reconstr Surg*. 1994;94(2):410–1.
10. Agha RA, Franchi T, Sohrabi C, Mathew G, Kerwan A. The SCARE 2020 guideline: updating consensus Surgical Case REport (SCARE) guidelines. *Int J Surg*. 2020;84:226–30.

11. Kransdorf MJ, Bancroft LW, Peterson JJ, Murphey MD, Foster WC, Temple HT. Imaging of fatty tumors: distinction of lipoma and well-differentiated liposarcoma. *Radiology*. 2002;224(1):99–104.
12. Celik C, Karakousis CP, Moore R, Holyoke ED. Liposarcomas: prognosis and management. *J Surg Oncol*. 1980;14(3):245–9.
13. Orson GG, Sim FH, Reiman HM, Taylor WF. Liposarcoma of the musculoskeletal system. *Cancer*. 1987;60(6):1362–70.

Kaushik Saha, Specialist

Abhishek Jaiswal, Senior Consultant & HOD

Author biography

Bijan Kumar Saha, Specialist  <https://orcid.org/0000-0003-3430-462X>

Cite this article: Saha BK, Saha K, Jaiswal A. Giant lipoma of thigh – Case report of rare tumour. *Indian J Pathol Oncol* 2023;10(3):321-324.