



Case Report

Seromucinous carcinoma of ovary - A rare entity

Madhuri Sethia^{1,*}, Bushra Siddiqui¹, Surabhi Gautam¹, Veena Maheshwari¹

¹Dept. of Pathology, J.N. Medical College, AMU, Aligarh, Uttar Pradesh, India



ARTICLE INFO

Article history:

Received 17-08-2023

Accepted 11-09-2023

Available online 27-09-2023

Keywords:

Seromucinous carcinoma

Ovary

Histopathology

ABSTRACT

Ovarian epithelial tumours are common tumors of female genital tract and they account for vast majority of female ovarian neoplasms. ovarian seromucinous carcinomas (OSMC) are rare ovarian tumours containing serous and endocervical mucinous type cells. In 2020, World Health Organization Classification of Female Genital Tumors recategorized seromucinous ovarian carcinomas as ovarian endometrioid carcinoma with mucinous differentiation. Most OSMC present in stage I or II and have a favourable prognosis.

We present the case of a 30-year-old female who presented with complaints of lower abdominal pain and abdominal distension. Contrast enhanced computed tomography of abdomen suggested a left sided malignant adnexal mass following which Left sided salpingo-oophorectomy was performed and histopathological examination and immunohistochemistry of specimen was done and a diagnosis of left ovarian seromucinous carcinoma was rendered.

This is an Open Access (OA) journal, and articles are distributed under the terms of the [Creative Commons Attribution-NonCommercial-ShareAlike 4.0 License](https://creativecommons.org/licenses/by-nc-sa/4.0/), which allows others to remix, tweak, and build upon the work non-commercially, as long as appropriate credit is given and the new creations are licensed under the identical terms.

For reprints contact: reprint@ipinnovative.com

1. Introduction

In the revised World Health Organisation classification of Tumours of the Female Reproductive organs, seromucinous neoplasms are a new category of ovarian epithelial tumor which are believed to have an association with endometriosis.¹ In older classification these tumors follow a wide range of course ranging from benign to malignant included seromucinous cystadenoma/cystadenofibroma, seromucinous borderline tumor/atypical proliferative seromucinous tumor and seromucinous carcinoma. These tumors histomorphologically are a mixture of serous and endocervical type with occasionally having foci of clear cell, squamous, transitional and endometrioid epithelium.² Ovarian seromucinous carcinoma was removed as separate entity and renamed as ovarian endometrioid carcinoma with mucinous differentiation according to 2020 World Health Organisation classification of Female Genital Tumors.³

Seromucinous carcinoma does not exhibit a distinct genotype or immunophenotype and its morphological diagnosis is also not very reliable.⁴ The molecular features of seromucinous carcinoma overlaps with endometrioid and low grade serous carcinomas.⁴ Serous, mucinous, clear cell, endometrioid, transitional, and squamous cell carcinoma are classified under epithelial ovarian neoplasm.³ It is most common in elderly patient, mean age group is around 48 years.⁵ The most common complain of patient is abdominal distension.⁵ The serum concentration of CA125 and CA19-9 is elevated in most of the patients.⁵ ER, PR, CA-125 and mesothelin are various markers of mullerian epithelium which is also expressed by seromucinous carcinoma.³ Ovarian seromucinous carcinoma also expresses PAX-8 strongly which was similar to serous tumors but different from mucinous tumors.³ Seromucinous component shows strong expression for CK7 and no expression for CK20 and CDX2.⁶ Endometrioid carcinoma component had higher immunoreactivity for ER and PR as compared to Seromucinous component.⁶ The prognosis of seromucinous

* Corresponding author.

E-mail address: madhurisethia1994@gmail.com (M. Sethia).

carcinoma was excellent as most of this tumors belongs to Stage I disease.⁶

2. Case Report

A 30-year-old female presented with complain of lower abdominal pain which was more prominent on left side for the past 30 days. It was gradual in onset, progressive in nature, moderate to severe in intensity. She also complained of abdominal distension for past 20 days which was gradual in onset. The patient had no history of fever, cough, yellowish discolouration of eyes, no puffiness of face and swelling over legs. The bowel and bladder habits were normal, but she complained of irregular menstrual cycle and heavy menstrual bleed for past 3 months. She was extremely weak with loss of appetite.

2.1. Examination

On physical examination she was hemodynamically stable and hydrated. Local examination revealed tenderness in all the quadrant and a lump was felt in lower abdomen. Initially it was small in size around 2 cm as examined by clinician and then it progressed gradually to around 5 cm after 6 months. It was firm in consistency and mobile.

Serum levels of CA125 were markedly raised (>225.5U/ml), Serum Carcinoembryonic antigen (CEA) levels were also raised (9.5ng/ml).

2.2. CECT-scan

Contrast enhanced computed tomography of abdomen was taken that showed evidence of a well defined peripherally enhancing collection with central hyperdense debris in the lower central abdomen closely adhered to left adnexa, abutting the fundus of uterus with terminal ileum loops adhered to its margins appearing oedematous and collapsed with peritoneal mesenteric fat stranding and ascites.

Finally Left sided salpingo-oophorectomy was performed for the patient and the specimen was sent to department of pathology for histopathological examination.

2.3. Gross

A gross examination of resected specimen was carried out. Left tubo-ovarian mass measures 12.5x11.3x6.9 cm, outer surface shows multiple nodular growth alongwith areas of congestion and specks of haemorrhage.(Figure 1) Cut section of specimen shows necrosis, papillary areas, solid, cystic and nodular areas along with few loculated areas with solid gel like material.(Figure 2)

2.4. Microscopy

Microscopic examination of section obtained from left sided tubo-ovarian mass showed both serous and mucinous components embedded in a background of fibrocollagenous

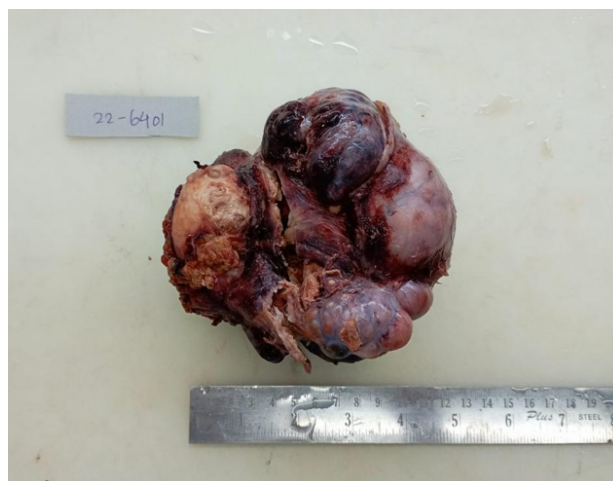

Fig. 1: Resected specimen of left tubo-ovarian mass showing multiple nodular areas

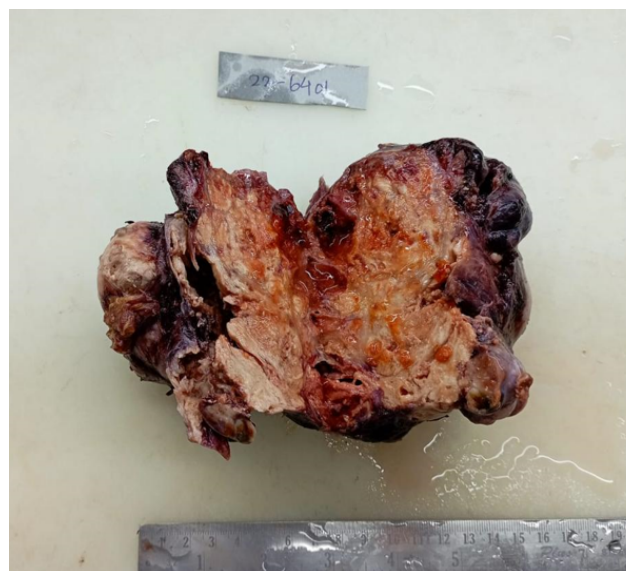

Fig. 2: Cut section of specimen shows necrosis, papillary areas, solid, cystic and nodular areas alongwith few loculated areas with solid gel like material

stroma.(Figure 3) Psammoma bodies were seen in serous component along with areas of necrosis, haemorrhage and few dilated and congested blood vessels. As the sections showed clear cut demarcation of serous and mucinous components, the histopathological picture was clearly that of a sero-mucinous ovarian carcinoma and no other differential diagnoses were made.

Immunohistochemical marker CK7, CK20 and CDX2 were applied. Positive reactivity for CK7 and negative reactivity for CK20 and CDX2 was seen on IHC examination.(Figure 4) Few IHC markers and Molecular studies could not be carried out because of poor financial status of the patient and non-availability of resources.

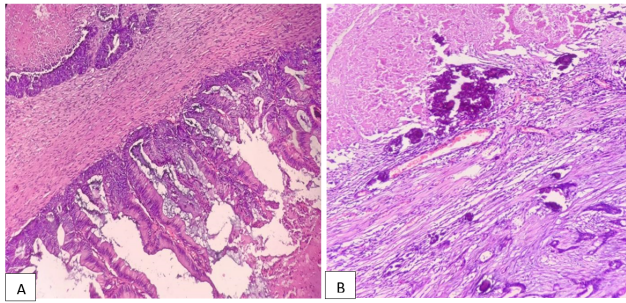


Fig. 3: A,B): Section shows serous and mucinous component. Serous component has psammoma bodies. Background shows fibrocollagenous stroma. Few dilated and congested blood vessels are also seen

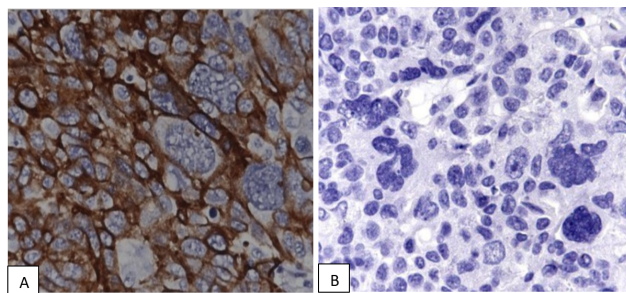


Fig. 4: A): Immunohistochemistry shows positive reactivity for CK7; **B):** Immunohistochemistry showing negative reactivity for CK20 and CDX2

Thus, a final diagnosis of Seromucinous carcinoma of ovary was made on the basis of gross, microscopic examination and immunohistochemical studies.

3. Discussion

Ovarian tumors are classified as Germ cell, Epithelial/surface, Sex cord - Stromal tumor; out of which epithelial ovarian tumors are most common and accounts for almost 70% cases. The epithelial ovarian tumors are further subcategorized as Brenner, Serous, Mucinous, Endometrioid and Clear cell. However Germ cell tumors accounts for 10% of cases and it includes Dysgerminoma, Teratoma, Embryonal, Yolk sac and Choriocarcinoma. Seromucinous tumor is composed of serous-type cells and endocervical-type mucinous epithelium.⁷ In the 2014 WHO classification, Ovarian seromucinous tumors were introduced as one of the seven types of ovarian epithelial tumors. Ovarian seromucinous carcinoma was removed as separate entity and renamed as ovarian endometrioid carcinoma with mucinous differentiation according to 2020 World Health Organisation classification of Female Genital Tumors.³ Benign and malignant categories of seromucinous tumors do exist although most of them are classified under borderline category.⁸ Different categories of seromucinous tumors shows common characteristics

features:- (i) (20–40%) shows involvement of both the ovaries, (ii) no gastrointestinal differentiation, as evidenced by mixture of goblet cells and/or paneth cells and, (iii) (30–70%) shows association with endometriosis.⁸ The clinical and molecular features of seromucinous tumors demonstrates close relationship with endometriosis similar to that of endometrioid and clear cell tumors.⁷ Seromucinous carcinoma is most common in elderly patient (>45 years).⁵ The most common in early stages of ovarian cancer are lower abdominal pain and abdominal distension.⁹ CA125, also referred as Carbohydrate Antigen 125 is a high molecular weight mucinous glycoprotein found on surface of ovarian cancer cells. This antigen is then shed and quantified in serum samples of ovarian cancer patients.¹⁰ Seromucinous tumors shows strong expression of ER(100%), PR(67%), CA125(92%), weak expression of WT1(8%) and no expression of CK20 and CDX2 on immunohistochemical profile.⁷ The main management of ovarian tumor is its removal by surgery. In terms of practicality and safety in comparison to laparoscopy, laprotomy is preferred.⁹

Post surgery the patient is doing well and there was decline in levels of CA125 and CEA. No post-operative chemotherapy or radiotherapy is required for the patient.

4. Conclusion

This is a very rare case of Seromucinous Carcinoma of ovary in a young female. Seromucinous Carcinoma shows strong expression for CK7 and no expression for CK20 and CDX2 on immunohistochemical profile. Owing to its rarity the case is being presented here.

5. Source of Funding

None.

6. Conflict of Interest

None.

References

1. Taylor J, McCluggage WG. Ovarian Seromucinous Carcinoma: Report of a Series of a Newly Categorized and Uncommon Neoplasm. *Am J Surg Pathol.* 2015;39(7):983–92.
2. Idrees R, Din NU, Siddique S, Fatima S, Abdul-Ghafar J, Ahmad Z. Ovarian seromucinous tumors: clinicopathological features of 10 cases with a detailed review of the literature. *J Ovarian Res.* 2021;14(1):47.
3. Hu Y, Fu K, Liu H, He Q, Qiu X, Yang W, et al. Ovarian seromucinous carcinoma: an independent epithelial ovarian cancer. *J Ovarian Res.* 2023;16(1):1–8. doi:10.1186/s13048-023-01100-w.
4. Rambau PF, McIntyre JB, Taylor J, Lee S, Ogilvie T, Sienko A, et al. Morphologic reproducibility, genotyping, and immunohistochemical profiling do not support a category of seromucinous carcinoma of ovary. *Am J Surg Pathol.* 2017;41(5):685–95.
5. Tang SX, Sun YH, Xu Y, Zhou XR, Yang WT. Clinicopathological study of seromucinous carcinoma of ovary. *Zhonghua Bing Li Xue Za Zhi.* 2016;45(11):774–9.

6. Miyamoto M, Takano M, Aoyama T, Soyama H, Yoshikawa T, Tsuda H, et al. Seromucinous component in endometrioid endometrial carcinoma as a histological predictor of prognosis. *J Gynecol Oncol*. 2018;29(2):e20.
7. Kurman RJ, Shih IM. Seromucinous tumors of ovary. What's in a Name? *Int J Gynecol Pathol*. 2016;35(1):78–81.
8. Nagamine M, Mikami Y. Ovarian Seromucinous Tumors: Pathogenesis, Morphologic Spectrum, and Clinical Issues. *Diagnostics (Basel)*. 2020;10(2):77–9.
9. Tjokropawiro BA, Novitasari K, Ulhaq RA. A Huge Malignant Ovarian Tumor: A Case Report. *Am J Case Rep*. 2023;24:e939387. doi:10.12659/AJCR.939387.
10. Charkhchi P, Cybulski C, Gronwald J, Wong FO, Narod SA, Akbari MR. CA125 and Ovarian Cancer: A Comprehensive Review. *Cancers (Basel)*. 2020;12(12):3730. doi:10.3390/cancers12123730.

Author biography

Madhuri Sethia, Junior Resident  <https://orcid.org/0009-0004-7293-1864>

Bushra Siddiqui, Assistant Professor

Surabhi Gautam, Senior Resident

Veena Maheshwari, Professor

Cite this article: Sethia M, Siddiqui B, Gautam S, Maheshwari V. Seromucinous carcinoma of ovary - A rare entity. *Indian J Pathol Oncol* 2023;10(3):317-320.