



Case Report

Mesenteric fibromatosis: A rare entity- case report

Swati Sharma^{1,*}, Anupam Sarma¹, Deep Jyoti Kalita^{1,2}, Shiraj Ahmed¹, Lopa Mudra Kakoti¹

¹Dept. of Oncopathology, Dr B Borooh Cancer Institute, Guwahati, Assam, India

²Dept. of Surgical Oncology, Dr B Borooh Cancer Institute, Guwahati, Assam, India



ARTICLE INFO

Article history:

Received 05-08-2023

Accepted 11-09-2023

Available online 27-09-2023

Keywords:

Mesenteric fibromatosis

GIST

Immunohistochemistry

ABSTRACT

Mesenteric fibromatosis or desmoids are a part of spectrum of deep fibromatosis. Deep fibromatosis is a group of proliferative, locally aggressive lesions that can be infiltrative and can recur without metastasis. Case report: A 42-year male came to hospital with complains of abdominal pain and discomfort. On imaging a mesenteric tumour was noted and diagnosis of gastrointestinal tumour was considered. On histopathological examination a spindle cell tumour of low grade was diagnosed. IHC came out to be SMA positive and negative for DOG1, CD34, desmin and CD117. Ki67 was around 4%. HPE and IHC favored a diagnosis of mesenteric fibromatosis. Conclusion: mesenteric GIST and fibromatosis are very similar in clinical & radiological presentation and moreover pathological picture is quite similar. To differentiate the two immunohistochemistry helps. The two entirely poles apart entities have different management hence should be differentiated to avoid unnecessary treatment in case of benign fibromatosis.

This is an Open Access (OA) journal, and articles are distributed under the terms of the [Creative Commons Attribution-NonCommercial-ShareAlike 4.0 License](https://creativecommons.org/licenses/by-nc-sa/4.0/), which allows others to remix, tweak, and build upon the work non-commercially, as long as appropriate credit is given and the new creations are licensed under the identical terms.

For reprints contact: reprint@ipinnovative.com

1. Introduction

Mesenteric fibromatosis or desmoids come under the spectrum of deep fibromatosis, which is a group of benign proliferative lesions that can infiltrate the surrounding tissues i.e. locally aggressive. They can recur also but without metastasis. Depending upon their location they are classified as-intra-abdominal or extra-abdominal.¹

Although there are many risk factors predisposing for mesenteric fibromatosis, but actual etiology is still unknown. The common risk factors associated are-prolonged intake of estrogen, Gardner's syndrome and trauma. But de novo causes without any such risk factors are also known. Clinical features are generally related to the mass effect or obstruction of surrounding organs like small bowel, or ureters.²

Imaging studies are not of much use when this uncommon entity has to be differentiated from other similar soft tissue tumours with malignant potential, which is a must so as to avoid unnecessary treatment.³

The main line of treatment is surgical excision but some studies also recommend use of antiestrogens, non steroidal anti inflammatory drugs and cytotoxic chemotherapy.⁴

2. Case Report

We report a case of 42 year male complaining of on and off abdominal pain. Outside ultrasonography revealed 10x4cm intraperitoneal mass in infracolic compartment of mesentery with differential diagnosis of primary peritoneal neoplasm and small bowel Gastro intestinal tumour (GIST). There was no significant medical or surgical history. All the hematological and biochemistry investigations, including tumour markers were within the normal limit.

* Corresponding author.

E-mail address: drswatisharma.204@gmail.com (S. Sharma).

CT scan of abdomen showed nodular mesenteric mass near ileo-cecal junction of approximately 10x9cm² and diagnosis of gastrointestinal stromal tumour was made. Patient underwent exploratory laprotomy. Intra-operatively a mesenteric mass measuring 10x9 cm was seen in close proximity to ileum. Mass was also seen adhered to third part of duodenum. No peritoneal or liver metastasis was seen. Excision of the mesentery along with ileum in wedge fashion was done. Duodenal wall was also excised and primarily repaired. Ileo-ascending anastomosis was done. Meanwhile lymph node was sent for frozen section, which came out to be reactive. Mesenteric mass was then sent for histopathological examination. We received a mesenteric mass, measuring 12x8x5cm, with part of intestine measuring 15cm in length. On cut section the mucosa of the intestine was intact and unremarkable. On serial sectioning, mesenteric mass showed grayish white firm growth with few dark brown areas. Focal areas also showed mucoid degeneration. On histopathological examination mesenteric mass came out to be low grade spindle cell tumour comprising of stellate fibroblastic cells embedded in myxoid and collagenous stroma with prominent blood vessels. (Figures 1 and 2) Differential diagnosis of GIST and mesenteric fibromatosis was thought of. IHC revealed CD117, CD34 and desmin to be negative and SMA to be positive. Ki67 was around 4%. (Figures 3, 4, 5, 6 and 7) The final diagnosis of mesenteric fibromatosis or desmoid was made. Beta catenin was not available so it was suggested to further confirm the diagnosis.

The patient is still under follow up and has no recurrence or complication yet.

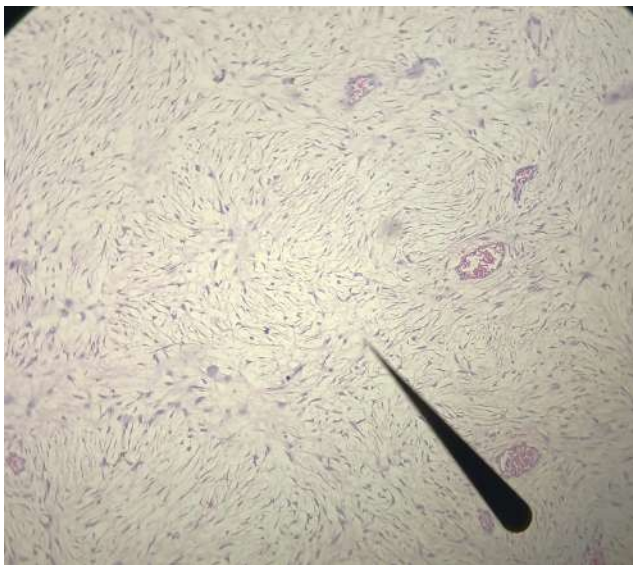


Fig. 1: H&E. Low power view of low grade spindle cell tumor

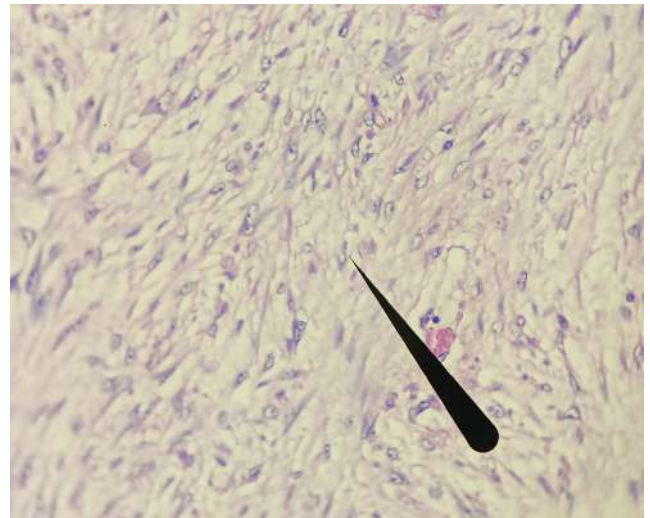


Fig. 2: H&E. high power view of spindle cells with minimal atypia

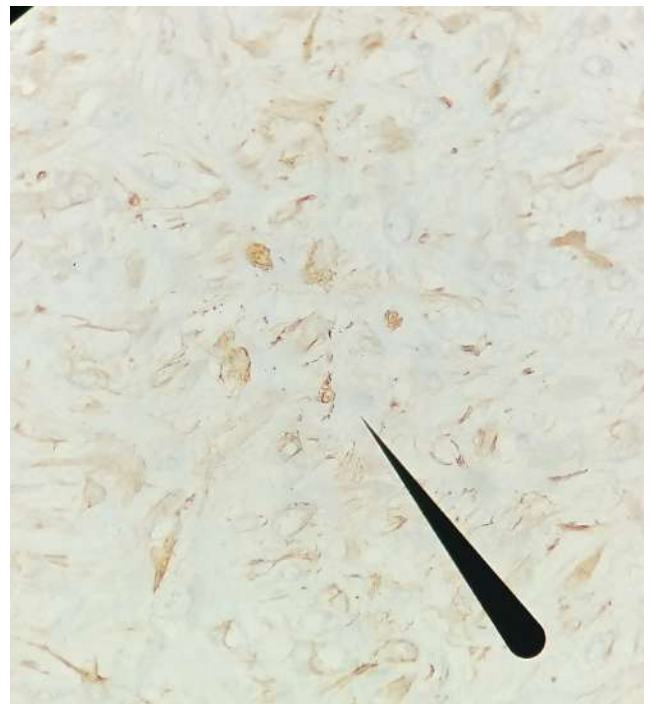


Fig. 3: IHC for SMA - positive

3. Discussion

Mesenteric fibromatosis is a rare entity which is locally aggressive. It has a characteristic pattern of growth, where it grows rapidly in initial phases and then get stabilizes or can even regress sometimes. It can occur in two forms sporadically or associated with syndromes like familial adenomatous polyposis coli (FAP), Gardner syndrome, and bilateral ovarian fibromatosis. There are some risk factors associated with this tumour, which

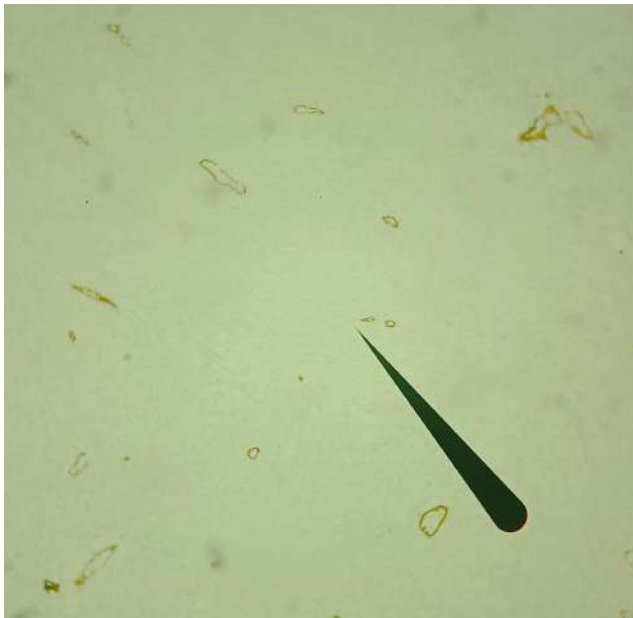


Fig. 4: IHC for CD34 positive in blood vessels and negative in tumor cells

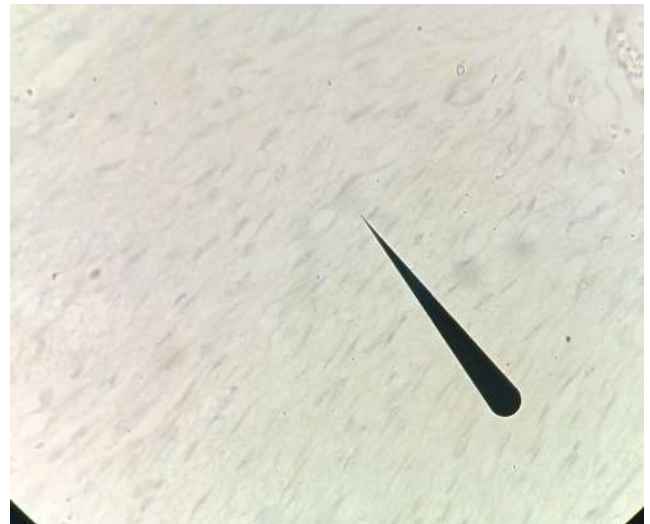

Fig. 6: IHC negative for desmin

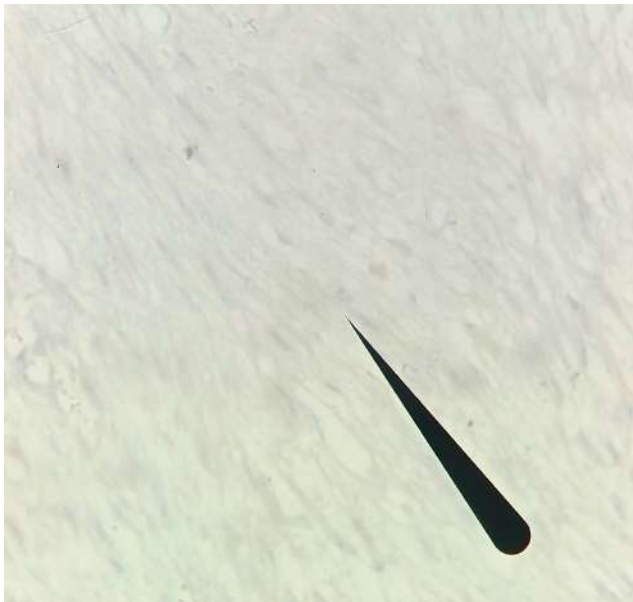

Fig. 5: IHC negative for CD117

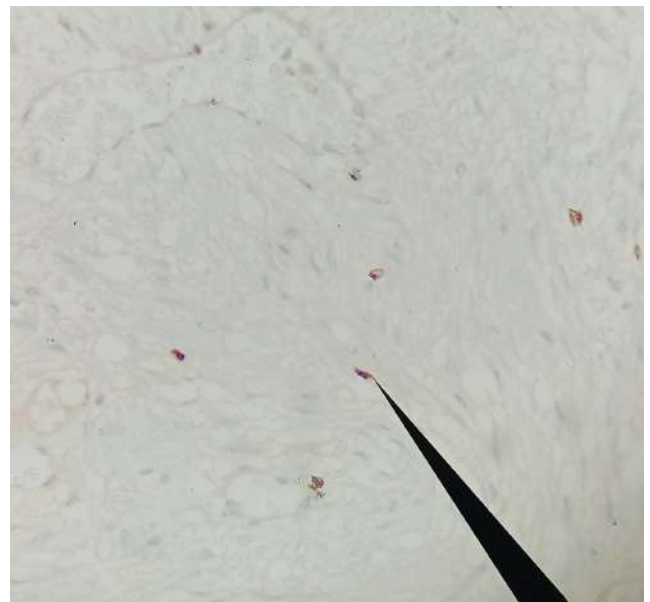


Fig. 7: IHC Ki67 around 4%

include trauma, previous abdominal surgery, pregnancy and estrogen therapy.⁵

Histopathological picture of desmoid fibromatosis shows proliferation of well differentiated fibroblasts with intercellular collagen, without nuclear atypia, invasion and distant metastasis. The tumor is locally aggressive and has common tendency to recur.⁶ Imaging techniques are not of much use when we have to differentiate between GIST and mesenteric fibromatosis. It is the

immunohistochemistry which can conclude the diagnosis. If Bcatenin and SMA come out to be positive then it favors mesenteric fibromatosis and if DOG1, CD117, PDGFRA or CD34 come positive then it favors GIST.⁷

The main treatment modality is surgical resection in most of the cases, if the root of mesentery is not involved. Sometimes large tumours may cause intestinal obstruction thus leading to mesenteric ischemia.⁸ Other than surgical resection other treatments include hormonal therapy-tamoxifen, interferon, NSAIDs and chemotherapy, especially when chances of local recurrence are high as seen in Gardner syndrome, if patient is unfit of surgery or multiple comorbidities are there in the patient.⁹

4. Conclusion

We report this case of mesenteric fibromatosis, not only because of its rarity but also because it poses a clinical and radiological challenge which can be sorted with the help of ancillary techniques like immunohistochemistry.

5. Source of Funding

None.

6. Conflicts of Interest

The authors declare no conflicts of interest.

References

- Mahajan A, Singh M, Varma A, Sandhu GS, Singh M, Nagori R. Mesenteric fibromatosis presenting as a diagnostic dilemma: a rare differential diagnosis of right iliac fossa mass in an eleven year old-a rare case report. *Case Rep Surg*. 2013;2013:569578. doi:10.1155/2013/569578.
- Karakousis CP, Berjian RA, Lopez R, Rao U. Mesenteric fibromatosis in Gardner's syndrome. *Arch Surg*. 1978;113:998–1000.
- Wronski M, Ziarkiewicz-Wroblewska B, Slodkowski M, Cebulski W, Gornicka B, Krasnodebski IW. Mesenteric fibromatosis with intestinal involvement mimicking a gastrointestinal stromal tumour. *Radiol Oncol*. 2011;45(1):59–63.
- Polat C, Aktepe F, Turel S, Yazicioglu B, Ozkececi T, Arikan Y. A giant mesenteric fibromatosis case presenting with mechanical intestinal obstruction and successfully resected with partial duodenojejunectomy and right hemicolectomy. *Clinics (Sao Paulo)*. 2010;65(1):110–3.
- Chen FJ, Jeng KS. Intraabdominal fibromatosis; a rare complication of previous abdominal surgery. *Formos J Surg*. 1999;32:97–100.
- Stout AP, Latters R. Tumors of the soft tissues. Washington DC: The National Academies Press; 1967. p. 451–5. doi:10.17226/18647.
- Nicolas G, Kfoury T, Shimlati R, Tohmeh M, Wakim R. Incidental Finding and Management of Mesenteric Fibromatosis. *Am J Case Rep*. 2016;17:389–94.
- Smith AJ, Lewis JJ, Merchant NB, Leung DH, Woodruff JM, Brennan MF. Surgical management of intra-abdominal desmoid tumours. *Br J Surg*. 2000;87(5):608–13.
- Janinis J, Patriki M, Vini L, Aravantinos G, Whelan JS. The pharmacological treatment of aggressive fibromatosis: A systematic review. *Ann Oncol*. 2003;14(2):181–90.

Author biography

Swati Sharma, Senior Resident  <https://orcid.org/0000-0001-8029-7999>

Anupam Sarma, Professor and HOD

Deep Jyoti Kalita, Associate Professor

Shiraj Ahmed, Professor

Lopa Mudra Kakoti, Associate Professor

Cite this article: Sharma S, Sarma A, Kalita DJ, Ahmed S, Kakoti LM. Mesenteric fibromatosis: A rare entity- case report. *Indian J Pathol Oncol* 2023;10(3):303-306.