



Letter to Editor

Confluent and reticulated papillomatosis (CARP) of gougeret and carteaud

Sujata Panda¹, Shilpa Padhi², Deepika Sahu², Shushruta Mohanty^{2,*}¹NIDAN Diagnostic & Research Centre, Ganjam, Odisha, India²Dept. of Pathology, MKCG Medical College and Hospital, Brahmapur, Odisha, India

ARTICLE INFO

Article history:

Received 11-05-2023

Accepted 06-06-2023

Available online 17-06-2023

This is an Open Access (OA) journal, and articles are distributed under the terms of the [Creative Commons Attribution-NonCommercial-ShareAlike 4.0 License](https://creativecommons.org/licenses/by-nc-sa/4.0/), which allows others to remix, tweak, and build upon the work non-commercially, as long as appropriate credit is given and the new creations are licensed under the identical terms.

For reprints contact: reprint@ipinnovative.com

Dear Sir,

Confluent and Reticulated papillomatosis is uncommon and distinctive ichthyosiform dermatosis seen in young adults. It was first described by French dermatologist Gougeret and Carteaud in the year 1927 who named this entity then as papillomatous pigmentee inominee.¹ Subsequently 5 years later Wise and Sachs gave the term confluent and reticulated papillomatosis.² It is characterised by persistent brown scaly macules to papules, patches and plaques localized predominantly on neck, intermammary, interscapular, axillae and abdomen.³ Other unusual sites of involvement that were reported in literature were knee, elbows, hand and antecubital and popliteal fossa.^{4,5} These lesions mostly begins in the late teens and early twenties, with an equal sex distribution and affects white, blacks and Asian patients.⁶

A 18-year old obese adolescent presented to skin OPD with multiple hyper pigmented raised lesions in the lower abdomen since 5 months. There was no complaints of itching. He was prescribed antifungal ointment by some local practitioner from his village but the lesions gradually progressed to involve the flanks, which compelled him to seek a dermatologist. On examination tan brown pigmented fine scaly macules to papules were present that were confluent in the centre and reticulate at the periphery.(Figure 1) All routine

hematological investigation and biochemical investigations were normal. His family history and past history were not significant. Biopsy was done and was sent to our dept for histopathology. Microsection shows undulating basket weave hyperkeratosis, focal acanthosis and papillomatous projections of the papillary dermis.(Figure 2) Increase basal layer pigmentation with melanin incontinence in superficial dermis. Histopathologic picture was consistent with clinical diagnosis of Confluent and Reticulated Papillomatosis (CARP).

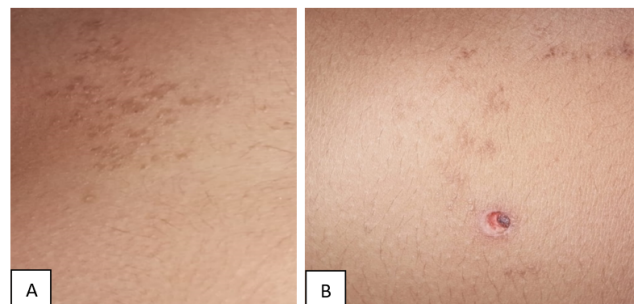


Fig. 1: A): Hyperpigmented tan brown pigmented fine scaly macules to papules were present that were confluent in the centre and reticulate at the periphery in the lower abdomen; **B):** Pic indicating the site of biopsy

The precise underlying cause has not yet been determined. Abnormal host reaction to pityrosporum

* Corresponding author.

E-mail address: sushruta.mohanty@gmail.com (S. Mohanty).

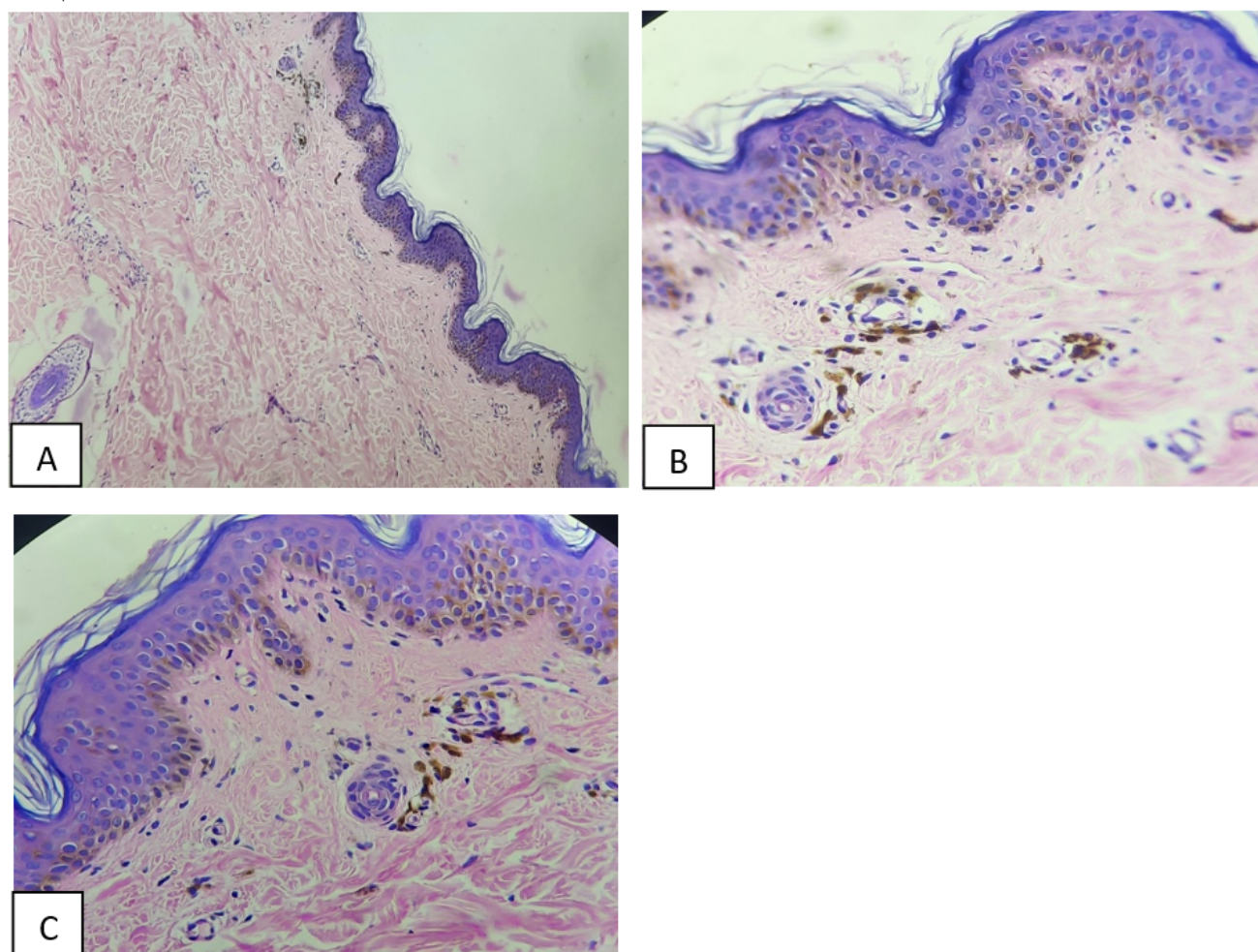


Fig. 2: A): Scanner view 40x- Epidermis showing - undulating basketweave hyperkeratosis, focal acanthosis and papillomatous projections of the papillary dermis; B, C): Low power : LP 100x Increase basal layer pigmentation with melanin incontinence in superficial dermis

organisms or bacteria and endocrine abnormalities (hyperinsulinemia, insulin resistance, Cushing's disease and pituitary dysfunction, acanthosis nigricans) ultraviolet exposure, amyloidosis, disorder of keratinisation with overexpression of keratin 16 have been suggested to play a role in development of this disease.⁷ *Dietzia papillomatosis* is a gram positive actinomycete that is a potential infectious candidate that was first isolated from a patient of CRP in the year 2005.⁸

The differential diagnosis to be considered here are acanthosis nigricans, *Tinea versicolor* and Darrier disease.⁹ *Tinea versicolor* was ruled out by absence of organisms on KOH mount and PAS staining. Darrier disease was ruled out on histology by lack of subbasal acantholysis and dyskeratotic cells (corps ronds and grains). Acanthosis nigricans clinically is characterized by hyperpigmented, velvet textured plaques and is often accompanied by malignancies and endocrinopathy. Histologically characterised by orthokeratotic hyperkeratosis (basket

weave), delicate elongated papillomatosis of stratum spinosum, slight acanthosis, mild increase in basal pigmentation with no melanocytic hyperplasia and no dermal inflammation. No such evidence was seen clinically or histopathologically. Less common disorders to be considered in differentials are Dowling degos disease, epidermal nevus, lichen or macular amyloidosis, variants of seborrheic keratosis, Becker's Nevus. Dowling degos disease is characterized by hyperkeratosis overlying a normal to reduced epidermis. Hyperpigmented thin filiform epithelial strands extend into the superficial dermis from epidermis and hair follicles in an "antler like pattern". The infundibular portion of the hair follicle appears dilated with occasional small horn cysts.

To conclude CRP is a rare skin condition, its etiology and pathogenesis is still poorly understood. Majority of the cases are sporadic although familial occurrences have been reported. Various treatment options have been described in literatures with prognosis of CRP being good with marked

improvement and close to complete clinical resolution when minocycline or azithromycin was used as first line of treatment. This was proved in the largest prospective cohort of 11 patients with CRP treated with oral minocycline 50mg twice daily for 6 weeks.¹⁰ Raja Babu et al⁴ prescribed azithromycin 500 mg daily for 7 days and total regression followed within 4 weeks. Systemic retinoids are reserved for non-responders to antibiotics.

References


- Gougerot H, Carteaud A. Papillomatosepigment-eeinnominee. *Bull Soc Fr Dermatol Syphiligr.* 1927;34:719–21.
- Wise F. Confluent and reticular papillomatosis (Gougerot-Carteaud). *Arch Dermatol Syphilol.* 1937;35:550.
- Elgat ML, Warren NG. The superficial and subcutaneous Mycosis. In: Moschella SL, Hurley HJ, editors. *Dermatology.* Philadelphia: WB Saunders; 1992. p. 869–912.
- Babu KKR, Snehal S, Vani DS. Confluent and reticulated papillomatosis: Successful treatment with azithromycin. *Br J Dermatol.* 2000;142:1252–3.
- Atasoy M, Aliagaoglu C, Erdem T. A case of early onset confluent and reticulated papillomatosis with an unusual localization. *J Dermatol.* 2006;33(4):273–7.
- Lee MP, Stiller MJ, McClain SA, Shupack JL, Cohen DE. Confluent and reticulated papillomatosis: Response to oral isotretinoin therapy and reassessment of epidemiologic data. *Am Acad Dermatol.* 1994;31:327–31.
- Le C, Bedocs PM. *Confluent and Reticulated Papillomatosis.* Treasure Island (FL): StatPearls Publishing; 2022.
- Natarajan S, Milne D, Jones AL, Goodfellow M, Perry J, Koerner RJ. Dietziastrain X: a newly described actinomycete isolated from confluent and reticulate papillomatosis. *Br J Dermatol.* 2005;153(4):825–7.
- Sau CP, Lupto GP. Reticulated truncal pigmentation. Confluent and reticulated papillomatosis of Gougerot Carteaud. *Arch Dermatol.* 1988;124(8):1272–5.
- Montemarano AD, Hengge M, Sau P, Welch M. Confluent and reticulated papillomatosis: response to minocycline. *J Am Acad Dermatol.* 1996;34(2 Pt 1):253–6.

Author biography

Sujata Panda, Consultant Pathologist

Shilpa Padhi, Tutor

Deepika Sahu, Tutor

Shushruta Mohanty, Assistant Professor  <https://orcid.org/0000-0002-3122-6892>

Cite this article: Panda S, Padhi S, Sahu D, Mohanty S. Confluent and reticulated papillomatosis (CARP) of gougeret and carteaud. *Indian J Pathol Oncol* 2023;10(2):219-221.