

Content available at: <https://www.ipinnovative.com/open-access-journals>

Indian Journal of Pathology and Oncology

Journal homepage: www.ijpo.co.in

Case Report

Collision tumor of ovary – Case report

Mukilarasi K R^{1,*}, Kavita V¹, Kavitha A¹

¹Lister Metropolis, Chennai, Tamil Nadu, India



ARTICLE INFO

Article history:

Received 08-02-2023

Accepted 06-06-2023

Available online 17-06-2023

Keywords:

Collision tumor

Mucinous cystadenoma

Mature cystic teratoma

ABSTRACT

Collision tumors are rare neoplasms defined by the presence of two distant tumors in the same organ without any histological intermixing. Each component of the collision tumor occur coincidentally and no connection is found between the tumors. Our case is a collision tumor of ovary composed of mature cystic teratoma and Mucinous cystadenoma.

This is an Open Access (OA) journal, and articles are distributed under the terms of the [Creative Commons Attribution-NonCommercial-ShareAlike 4.0 License](https://creativecommons.org/licenses/by-nc-sa/4.0/), which allows others to remix, tweak, and build upon the work non-commercially, as long as appropriate credit is given and the new creations are licensed under the identical terms.

For reprints contact: reprint@ipinnovative.com

1. Introduction

Collision tumors are rare neoplasms defined by the presence of two distant tumors in the same organ without any histological intermixing.¹ These tumors have been described in other organs such as liver, kidney, brain, lung, stomach, esophagus and bone but their occurrence in ovary is rare.² The nature of these collision tumors can be benign- benign, benign- malignant and malignant-malignant. Mature cystic teratoma has been one component in many collision tumors of ovaries that has been reported.³ Our case is a collision tumor of ovary composed of Mature cystic teratoma and Mucinous cystadenoma.

2. Case History

A 39-year-old female, P2L2 with regular menstrual cycle, presented to the hospital with abdominal distension and abdominal discomfort for a period of 7 months. Her general condition was fair. Abdominal examination revealed soft palpable mass in the right iliac fossa and hypogastric region. The patient was proceeded with tumor markers and Ultrasound investigations. ROMA index which measures CA 125, and HE 4 showed 2.2% which is a low risk for

ovarian epithelial cancers.

Abdominal and transvaginal ultrasound was done which revealed a cystic mass measuring 230 mm x 180 mm x 120 mm. Right ovarian cystectomy with right salpingectomy was done for the patient and the sample was received in our histopathology department.

We received a partially cut open cyst measuring 18 x 15 x 10 cms. The capsule was intact. The cut surface showed multiple locules filled with mucinous material with focal irregular areas. Cut surface of one locule showed pultaceous material and hair follicles. Other locules showed mucinous material. Multiple bits were given from all the areas and examined under microscope.

Microscopic examination showed ovarian parenchyma with a cyst lined by skin with adnexal structures and is focally lined by mucus secreting columnar epithelium. Focally stroma shows ganglion cells and foci of calcification. Sections from other cystic locules showed cyst wall lined by a single layer of bland cuboidal to columnar epithelium with basally placed nuclei with bland ovarian stroma.

* Corresponding author.

E-mail address: mukilpath@gmail.com (Mukilarasi K R).

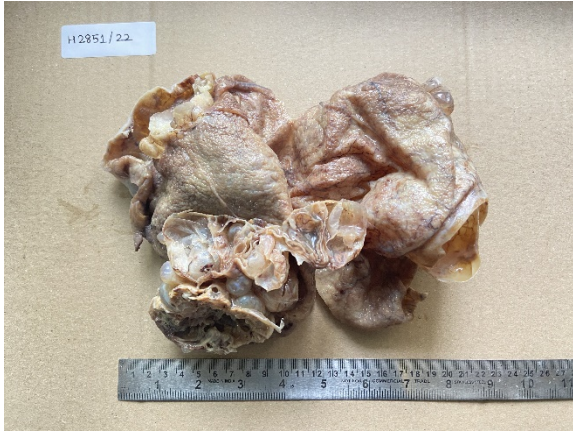

Fig. 1: Gross image of the ovarian cyst shows multiloculated cyst filled with mucin

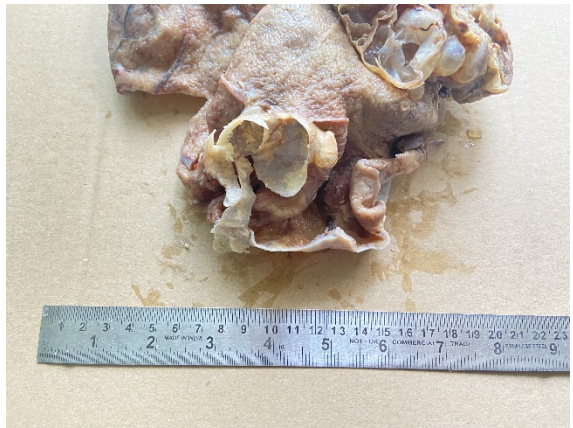

Fig. 2: Gross image shows a multiloculated cyst. One locule is filled with keratinous material

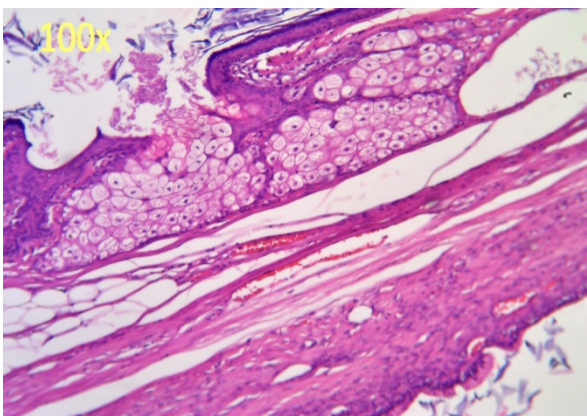


Fig. 3: Sections from multiloculated cyst lined by skin and adnexal structures

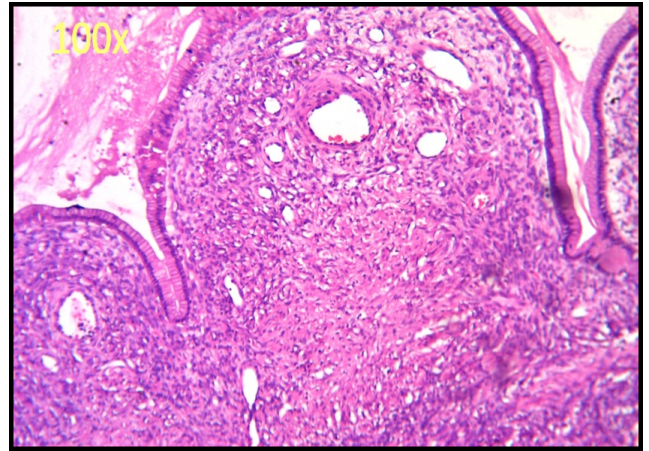


Fig. 4: Microscopy of the multiloculated cyst lined by mucin secreting columnar epithelium

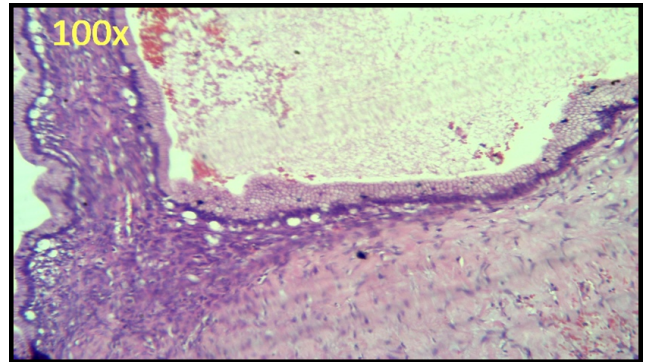


Fig. 5: Microscopy of the multiloculated cyst lined by mucin secreting columnar epithelium

3. Discussion

Collision tumors are two tumors with different histological subtype occurring in the same organ.⁴ Each component of the collision tumor occur coincidentally and no connection is found between the tumors. The collision tumor of mucinous cystadenoma and mature cystic teratoma is the most commonly encountered one⁴ like in our case, where we had a single locule which showed the features of teratoma and all other locules which showed features of mucinous cystadenoma.

The ovarian teratomas are the commonest germ cell tumors which are benign in nature and are composed of matured tissue representing at least 2 embryonic layers (ectoderm, endoderm and mesoderm) and the most commonly excised ovarian tumors. Their occurrence is seen mostly in younger women. Mucinous cystadenoma is a benign ovarian epithelial tumor that is composed of glands lined by columnar epithelial cells without complexity or cytologic atypia.⁵

Other combination of collision tumor reported includes, Mature cystic teratoma with other epithelial ovarian tumors like mucinous cystadenocarcinoma,⁶ serous cystadenocarcinoma,⁷ choriocarcinoma and cystadenoma,⁸ sarcoma and mucinous tumor.⁹

The exact pathogenesis for this tumor co-existence is not clearly understood. However many hypothesis have been put forward to understand this.

1. The occurrence of two distinct histological subtype tumors can purely be coincidence as they may originate from the neighbouring tissues.^{10,11}
2. When there is a simultaneous proliferation of two different cell lines.¹²
3. The two distinct tumors in the collision tumor may have a common pluripotent precursor stem cell, from which they originated.¹²
4. Can be due to a carcinogenic agent that may interact with different tissues, inducing different tumors.^{10,11}
5. Alteration in the microenvironment, such as angiogenesis and inflammation, by the primary tumor could facilitate the growth of a second primary tumor.^{13,14}

Diagnosis of collision tumors are purely based on the post-operative histopathological diagnosis. Sometime preoperatively radiology can give clues such as, the presence of solid and cystic component in ovarian tumors, but which cannot rule out other solid and cystic neoplasm of the ovaries.

4. Conclusion

Though rare it is necessary to be aware of collision tumors, the combination of tumors that exists as the appropriate treatment can be given to the patient.

5. Source of Funding

None.

6. Conflict of Interest


None.

References

1. Sharan JP, Dorothy LF, Nayak SR, Arun R, Deepika B. Collision tumor of ovary: A rare entity. *Int J Innov Res Dev.* 2014;3(7):424–7.
2. Priyanka B, Pranab D. Bilateral Serous adenocarcinoma of Ovary coexisting with mature cystic teratoma- Case report and review of literature. *Ann Pathol Lab Med.* 2015;2(2):71–4.
3. Pepe F, Panella M, Pepe G, Panella P, Pennisi F, Arikian S. Dermoid cysts of the ovary. *Eur J Gynaecol Oncol.* 1986;7(3):186–91.
4. Singh AK, Singh M. Collision tumours of ovary: a very rare case series. *J Clin Diagn Res.* 2014;8(11):FD14–6.
5. Ravikanth R. A rare case of collision tumor: Massive mucinous cystadenoma and benign mature cystic teratoma arising in the same ovary. *CHRISMED J Health Res.* 2017;4(3):201.
6. Joshi CV, Enver T. Plasticity revisited. *Curr Opin Cell Biol.* 2002;14(6):749–55.
7. Cabibi D, Martorana A, Cappello F, Barresi E, Gangi CD, Rodolico V. Carcinosarcoma of monoclonal origin arising in a dermoid cyst of ovary: a case report. *BMC Cancer.* 2006;6:47.
8. Ozaki Y, Shindoh N, Sumi Y. Choriocarcinoma of the ovary associated with mucinous cystadenoma. *Radiat Med.* 2001;19(1):55–9.
9. Prat J, Scully RE. Sarcomas in ovarian mucinous tumors: a report of two cases. *Cancer.* 1979;44(4):1327–31.
10. Nirenberg A, Ostor AG, Quinn MA. Collision tumor: serous adenocarcinoma and steroid cell tumor of the ovary. *Pathology.* 1992;24(2):60–2.
11. Cohen A, Geller SA, Horowitz I, Toth LS, Werther JL. Experimental models for gastric leiomyosarcoma: the effects of N-methyl-N'-nitro-N-nitrosoguanidine in combination with stress, aspirin, or sodium taurocholate. *Cancer.* 1984;53(5):1088–92.
12. Mayur B, Kanthan CS, Kanthan R. Collision tumor of the colon – colonic adenocarcinoma and ovarian granulosa cell tumor. *World J Surg Oncol.* 2007;5:118.
13. Caroli E, Salvati M, Rocchi G, Frati A, Cimatti M, Raco A. Post-traumatic intracranial meningiomas. *Tumori.* 2003;89(1):6–8.
14. Louis DN, Ramesh V, Gusella JF. Neuropathology and molecular genetic of neurofibromatosis 2 and related tumours. *Brain Pathol.* 1995;15(2):163–72.

Author biography

Mukilarasi K R, Pathologist  <https://orcid.org/0000-0001-9725-9884>

Kavita V, Pathologist  <https://orcid.org/0000-0002-3514-9249>

Kavitha A, Consultant Pathologist

Cite this article: Mukilarasi K R, Kavita V, Kavitha A. Collision tumor of ovary – Case report. *Indian J Pathol Oncol* 2023;10(2):201-203.