



## Case Series

## Versatility of facial artery musculomucosal flap in medium sized defects following ablation of oral cancers - A case series

Shweta Sabu<sup>1,\*</sup>, Reshma Gafoor<sup>1</sup>, Sandeep Vijay<sup>2</sup>, Aswin Mullath<sup>1</sup>, Linu Thomas<sup>3</sup><sup>1</sup>Dept. of Oral and Maxillofacial Surgery, KMCT Dental College, Calicut, Kerala, India<sup>2</sup>Malabar Cancer Research Centre, Thalassery, Kerala, India<sup>3</sup>Dept. of Oncology, Malabar Cancer Research Centre, Thalassery, Kerala, India

## ARTICLE INFO

## Article history:

Received 16-03-2023

Accepted 20-05-2023

Available online 17-06-2023

## Keywords:

FAMM

Regional flaps

Pedicled flap

Reconstruction

## ABSTRACT

Facial artery musculomucosal flaps (FAMM) are frequently utilised to restore medium-sized abnormalities after surgical removal of oral malignancies. This case series provides an overview of how patients are chosen for FAMM flap surgery, the operative anatomy, the surgical procedure, and the benefits of FAMM flap in reconstruction.

This is an Open Access (OA) journal, and articles are distributed under the terms of the [Creative Commons Attribution-NonCommercial-ShareAlike 4.0 License](https://creativecommons.org/licenses/by-nc-sa/4.0/), which allows others to remix, tweak, and build upon the work non-commercially, as long as appropriate credit is given and the new creations are licensed under the identical terms.

For reprints contact: [reprint@ipinnovative.com](mailto:reprint@ipinnovative.com)

## 1. Introduction

A common option for reconstruction in cases of oral cancer is the facial artery musculomucosal flap. A flap is required to restore the form and function of a tumour after surgical excision. The decision of employment of flaps should be based on the nature and size of defect post surgical excision. Regional pedicled flaps like the infrahyoid flap, supraclavicular flap, or facial artery musculomucosal (FAMM) flap, have been documented to be more frequently in use in recent years, according to the literature.

Pribaz et al. first described the FAMM Flap in 1992 by merging the principles of the buccal flap and nasolabial flap. The facial artery serves as the basis for the musculomucosal flap. With a large arc of rotation, the facial artery musculomucosal flap offers vascularized full-thickness mucosal restoration.<sup>1</sup> The FAMM flap can be either inferiorly or superiorly based.

In this case series, an overview of the surgical anatomy, surgical procedure, prevalent indications, and benefits of

the flap are presented using data from a retrospective observational study of 7 patients who underwent FAMM flap reconstruction at Malabar Cancer Centre

## 1.1. Patient details

FAMM flap was done for 7 patients during a period of 6 months from September 2021 to February 2022 at Malabar Cancer Centre.

Table 1: Overview of the cases

S No	Age/Sex	Diagnosis	T Stage	N Stage
1	61/M	CA Floor of mouth	T2	N0
2	70/M	CA Tongue	T3	N0
3	70/M	CA Lower alveolus	T2	N0
4	74/M	CA Tongue	T2	N0
5	29/F	CA Floor of mouth	T2	N0
6	45/M	CA Tongue	T1	N0
7	65/F	CA Tongue	T2	N0

\* Corresponding author.

E-mail address: [shwetasadu1996@gmail.com](mailto:shwetasadu1996@gmail.com) (S. Sabu).

### 1.2. Surgical anatomy

The buccal mucosa, submucosa, buccinator muscle, and the superficial layer of the orbicularis oris muscle are all components of the FAMM flap; an intraoral cheek flap. Inferiorly based FAMM flaps are pedicled on the facial artery. Superiorly based FAMM flaps are pedicled on the angular artery. The facial artery is preserved on the entire length of the flap which is attached to the buccinator muscle. A submucosal plexus ensures venous drainage, therefore the facial vein is typically not included in the flap. To maintain adequate venous drainage through the submucosal venous plexus, the base of the pedicle should be at least 1.5 cm.

### 1.3. Surgical technique

Following resection of tumor and neck dissection, facial artery musculomucosal flap was harvested. Selective neck dissection was done for all cases since all the cases discussed were node negative cases.

The flap was marked on the buccal mucosa. Anteriorly, it was drawn 1 cm posterior to the oral commissure.<sup>2</sup> The orifice of the Stensen's duct limits the posterior extension of the flap. The flap's 2 cm base was situated inferiorly over the region of the second and third molar teeth (to include submucosal venous). The length of the flap is decided based on the size of the defect.

#### Identification of facial artery<sup>3</sup>

##### 1. Distal identification of the facial artery:

The facial artery was discovered deeper to the buccinator muscle after the incision through the mucosa, submucosa, and buccinator muscle. It was tied off and cut distally.

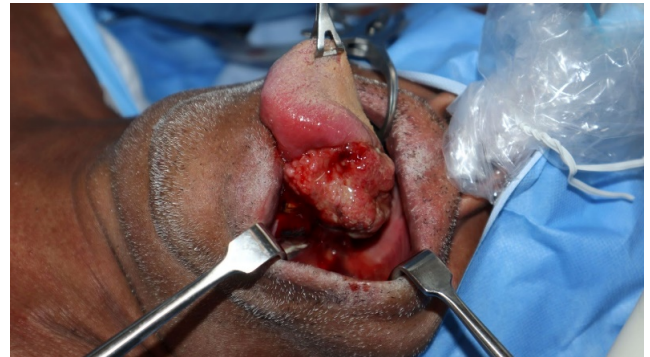
##### 2. Anterior identification of the facial artery:

The superior labial artery is located by making an incision through the buccinator muscle, submucosa, and mucosa 1 cm lateral to the oral commissure. To prevent distorting of the oral commissure with primary closure of the donor site defect, there must be a 1-cm margin between the commissure and the flap.<sup>4</sup> The alveolar crest was accessed by the flap's anterior incision. In the event of floor of mouth deformities, the flap's base was then dissected on a subperiosteal plane above the alveolar crest. The facial artery was then located by retrogradely following the superior labial artery.

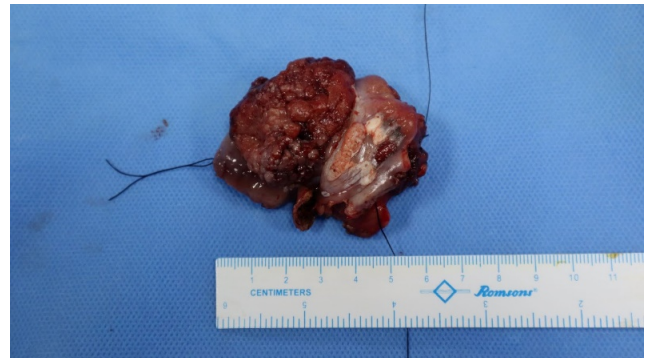The buccinator muscle and the layer beneath the facial artery were also elevated by the flap (Figure 4). The facial artery was retained connected to the tissues below along the full flap's length.

In certain instances, the flap was also islanded to prevent rotation over the lower alveolus. Once the flap was harvested, rotation of the flap or tunnelling beneath the mandible ensures the extensibility of flap to the defect site and it was stabilised with interrupted sutures

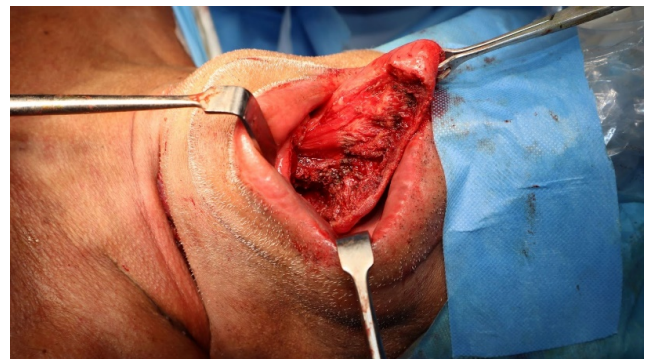
(Figure 5)(Figure 8) The donor site is either closed with buccal pad of fat or primarily.



**Fig. 1:** CA of tongue



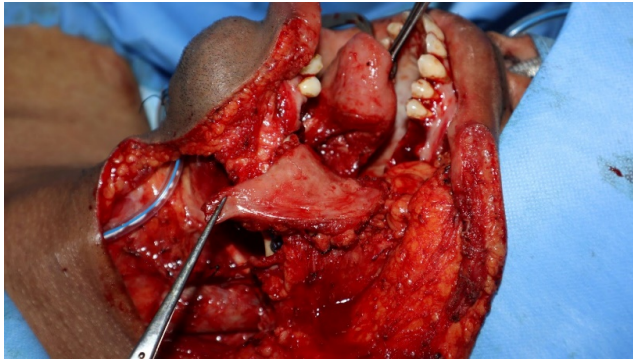
**Fig. 2:** Excision of tumor



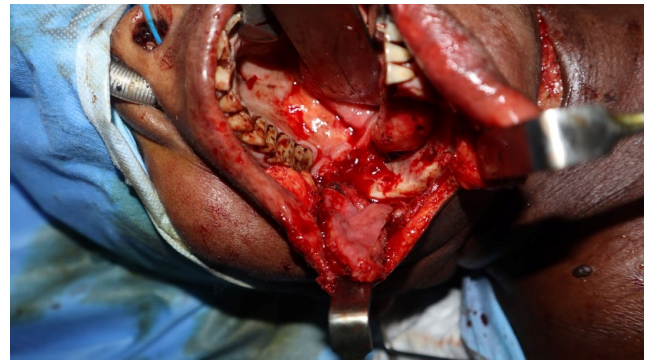
**Fig. 3:** Primary defect site

## 2. Results

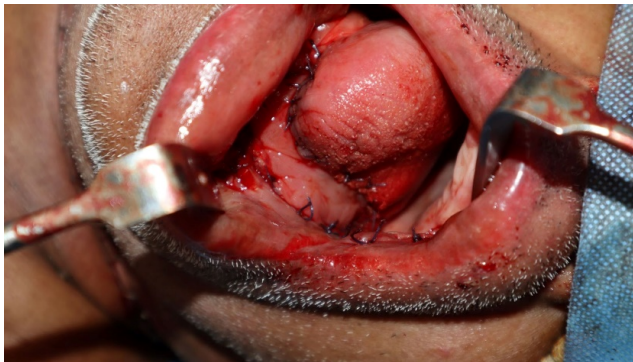Six out of seven flaps healed with no complications. Debridement was used to treat terminal marginal necrosis that appeared on one flap. There was no signs of flap failure noted in any of the cases.



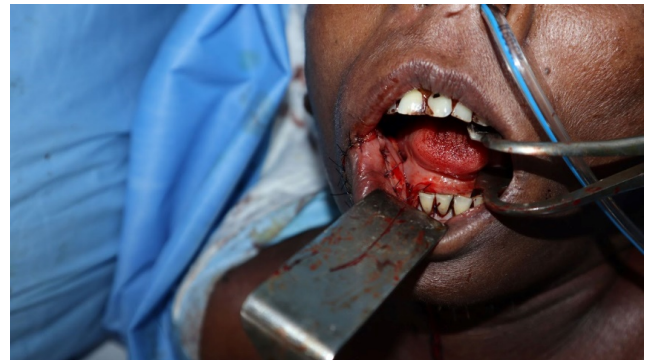**Fig. 4:** FAMM flap elevation



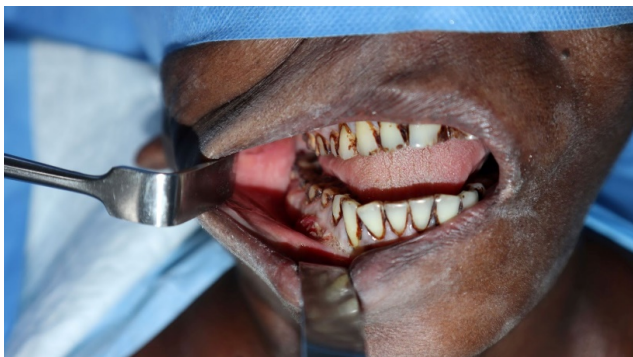**Fig. 8:** Elevation of FAMM Flap



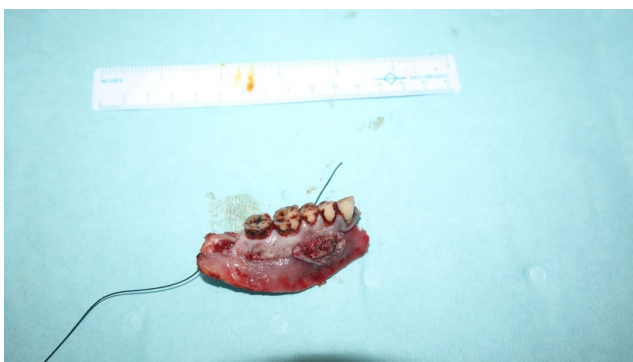**Fig. 5:** Post reconstruction with FAMM flap



**Fig. 9:** Post reconstruction with FAMM flap



**Fig. 6:** CA of lower alveolus



**Fig. 7:** Excision of tumor

### 3. Discussion

An intraoral musculomucosal flap based on the facial artery orientated in the vertical plane, anterior to the parotid duct, was described by Pribaz et al. in 1992. This flap offered two key benefits:<sup>5</sup>

1. The flap's vertical placement made it possible for it to be longer and have a greater arc of rotation.
2. The surgeon was able to base the flap either inferiorly or superiorly due to the facial artery's path and its continuation as the angular artery.

The buccinator myomucosal neurovascular flap, which is posteriorly based and supplied by the buccal artery, and the buccinator myomucosal reversed-flow arterial island flap (BAMM), which is superiorly based and supplied by the lateral nasal artery, a terminal branch of the facial artery, were both described by Zhao et al. in 1999.<sup>6</sup> The acronym buccinator myomucosal reversed-flow arterial island flap (BAMM), which has been used in the literature for the past ten years, is similar to FAMM. In a comprehensive evaluation of FAMM flaps, Giudice G et al. claimed that all BAMM flaps that had the buccal pedicle identified were classified as FAMM.<sup>7</sup>

The preservation of the facial pedicle during neck dissection is a crucial factor to take into account when

preparing for FAMM flap repair. In T1N0, T2N0, and T3N0 patients, we have used a FAMM flap to rebuild the primary defect. Three of the seven flaps were island-based. All the flaps were inferiorly based.

Joshi et al reported a series of 17 cases; all of the flaps experienced varied degrees of venous congestion, which later subsided on its own after conservative treatment.<sup>8</sup> Benjamin et al reported a series of 21 patients for evaluating the functional outcome following FAMM reconstruction. He noted significant venous congestion in the recipient site for tongue reconstruction.<sup>9</sup>

According to our observations after 7 cases of FAMM flap reconstruction, every flap survived without any failure. Debridement was used to treat terminal marginal necrosis in one of the flaps, which eventually underwent granulation leading to healing.

A group of 16 patients who had FAMM flap reconstruction as opposed to nasolabial flap were compared by Janardhan et al. Due to its similar tissue matching and lack of external facial scarring, he came to the conclusion that the FAMM flap is a superior alternative to the nasolabial flap.<sup>10</sup> FAMM flap is rather thick flap with a harvestable surface area of up to 24 square centimetres. It is ideally suited for repair of medium-sized lesions in T1 and T2 instances because of its greater arc of rotation, excellent vascularity, and other qualities indicated.

In our experience through 7 cases of FAMM flap reconstruction, all flaps survived without any failure. One of the flap encountered terminal marginal necrosis which was managed with debridement and it healed later through granulation

Janardhan et al compared a series of 16 patients with FAMM flap reconstruction over nasolabial flap. He concluded that FAMM flap is a better alternative to nasolabial flap due to its analogous tissue matching and no external facial scarring.<sup>10</sup> FAMM is a relatively thick flap that can be harvested with an area of up to 24 square centimetre.<sup>9</sup> Due to its longer arc of rotation and excellent vascularity and other mentioned attributes it is well suited for reconstruction of medium-sized defects in T1 and T2 cases in our experience.

#### 4. Conclusion

A trustworthy local flap for the restoration of medium-sized lesions is the facial artery musculomucosal flap (FAMM Flap). When a bigger (medium-sized) oral tongue defect needs to be repaired, a FAMM flap is a great solution since it can be used to ensure a satisfactory functional outcome without adding undue morbidity to the donor site or lengthening the healing process.

#### 5. Source of Funding

None.

#### 6. Conflict of Interest

None.

#### References

1. Patel U, Hartig G, Hanasono M, Lin D, Richmon J. Locoregional Flaps for Oral Cavity Reconstruction: A Review of Modern Options. *Otolaryngol Head Neck Surg.* 2017;157(2):201–9.
2. Jowett N, Hadlock TA, Sela E, Toth M, Knecht R, Lörincz BB. Facial mimetic, cosmetic, and functional standardized assessment of the facial artery musculomucosal (FAMM) flap. *Auris Nasus Larynx.* 2017;44(2):220–6.
3. Ayad T. Facial artery musculomucosal (FAMM) flap. *Oper Tech Otolaryngol Head Neck Surg.* 2019;30:112–9.
4. Janardhan D, George CK, Thomas S, Iype EM, Varghese BT, George NA. Island NLF or Island FAMM Flap in Reconstruction of Oral Malignancy Defects? *Indian J Surg Oncol.* 2020;11(2):188–91.
5. Pribaz JJ, Meara JG, Wright S, Smith JD, Stephens W, Breuing KH. Lip and Vermilion Reconstruction with the Facial Artery Musculomucosal Flap. *Plast Reconstr Surg.* 2000;105(3):864–72.
6. Zhao Z, Li S, Yan Y, Li Y, Yang M, Mu L, et al. New Buccinator Myomucosal Island Flap: Anatomic Study and Clinical Application. *Plast Reconstr Surg.* 1999;104(1):55–64.
7. Giudice G, Fragola R, Nicoletti G, Cervino G, Pedullà E, Zerbinati N. Facial Artery Myomucosal Flap vs. Islanded Facial Artery Myomucosal Flap Viability: A Systematic Review. *Appl Sci.* 2021;11(9):4202.
8. Joshi A, Rajendraprasad J, Shetty K. Reconstruction of intraoral defects using facial artery musculomucosal flap. *Br J Plast Surg.* 2005;58(8):1061–6.
9. Benjamin M, Aliano K, Davenport T, Frank D. Functional Outcomes Regarding Facial Artery Musculomucosal Flap for Reconstruction of Partial Glossectomy Defects. *Ann Plast Surg.* 2020;85(S1):76–9.
10. Janardhan D, George C, Thomas S, Iype E, Varghese B, George N. Island NLF or Island FAMM Flap in Reconstruction of Oral Malignancy Defects? *Indian J Surg Oncol.* 2020;11(2):188–91.

#### Author biography

**Shweta Sabu**, Post Graduate Student  <https://orcid.org/0000-0002-3934-712X>

**Reshma Gafoor**, Post Graduate Student  <https://orcid.org/0000-0002-0899-9352>

**Sandeep Vijay**, HOD

**Aswin Mullath**, Assistant Professor  <https://orcid.org/0000-0002-5662-4491>

**Linu Thomas**, Oncosurgeon

**Cite this article:** Sabu S, Gafoor R, Vijay S, Mullath A, Thomas L. Versatility of facial artery musculomucosal flap in medium sized defects following ablation of oral cancers - A case series. *Indian J Pathol Oncol* 2023;10(2):170-173.