

Content available at: <https://www.ipinnovative.com/open-access-journals>

Indian Journal of Pathology and Oncology

Journal homepage: [www.ijpo.co.in](http://www.ijpo.co.in)

## Original Research Article

## Histopathological spectrum of testicular lesions in a tertiary care hospital

Shikha Sharma<sup>1</sup>, Sarita Asotra<sup>1,\*</sup>, U. K. Chandel<sup>1</sup><sup>1</sup>Indira Gandhi Medical College & Hospital, Shimla, Himachal Pradesh, India

## ARTICLE INFO

## Article history:

Received 15-09-2022

Accepted 14-10-2022

Available online 14-12-2022

## Keywords:

Testes

Testicular lesions

Seminoma

Mixed germ cell tumor

## ABSTRACT

**Introduction:** Testicular tumors are relatively rare and comprise 1% of all male cancers worldwide with peak prevalence in the age group 15-35 years. Testicular lesions have a varied histomorphological spectrum and are largely categorized as non-neoplastic and neoplastic lesions.

**Aim and Objective:** To study the incidence of testicular lesions, to study the histomorphological spectrum of testicular lesions including non-neoplastic as well as neoplastic lesions and to determine age-wise distribution, laterality and clinical presentation in testicular lesions.

**Materials and Methods:** The present study is an observational study, carried out in the Pathology Department of Indira Gandhi Medical college, a tertiary care hospital in the northern India, over a duration of two years i.e from June 2020 to May 2022. A total of 52 radical orchidectomy and testicular biopsies were studied for gross and microscopic findings.

**Results:** 45 orchidectomy specimens and 7 testicular biopsies were studied. Out of these, 42 cases were non neoplastic and 10 were neoplastic. Maximum number of patients presented in the 2<sup>nd</sup> & 4<sup>th</sup> decade of life. Undescended testis was the most common non-neoplastic lesion (17/42;40.47%), followed by testicular torsion (12/42;28.57%). Seminoma was the most common neoplastic lesions (50%), followed by Mixed Germ Cell Tumors (20%) and Non-Hodgkin lymphoma (20%) and a single case of yolk sac tumor (10%). Clinically, most of the patients presented with scrotal swelling (58.53%). Right testis was involved more commonly (32/52;61.53%).

**Discussion and Conclusion:** Testicular cancers represent 10.5% of all male reproductive cancers in India. Germ cell tumors accounted for highest percentage of cases with a commonest subtype of seminoma followed by mixed germ cell tumors. Histopathologic examination can help in accurately diagnosing and determining the prognosis of these rare tumor and tumor like lesions of testis.

This is an Open Access (OA) journal, and articles are distributed under the terms of the [Creative Commons Attribution-NonCommercial-ShareAlike 4.0 License](https://creativecommons.org/licenses/by-nc-sa/4.0/), which allows others to remix, tweak, and build upon the work non-commercially, as long as appropriate credit is given and the new creations are licensed under the identical terms.

For reprints contact: [reprint@ipinnovative.com](mailto:reprint@ipinnovative.com)

## 1. Introduction

Testicular tumors are relatively rare and comprise 1% of all male cancers worldwide<sup>1</sup> with peak prevalence in the age group 15-35 years.<sup>2</sup> As incidence of testicular tumors is high among young adults of reproductive age, it is believed that high estrogen levels in-utero may contribute to development of testicular cancers.<sup>3</sup> A reverse trend in comparison to the general observation has been

seen with the testicular cancers where the incidence decreases with increasing age.<sup>4</sup> Testicular lesions have a varied histomorphological spectrum and are largely categorized as non-neoplastic and neoplastic lesions. Non-neoplastic lesions comprise cryptorchid testis, testicular torsion, testicular atrophy, epididymo-orchitis, abscesses, epidermoid cysts, infertility, malakoplakia and vasculitis. Tuberculosis, atypical mycobacteriosis, leprosy, syphilis, sarcoidosis and crohn's disease can also involve testis. 2016 WHO classification of testicular tumors introduced several updates to the previous 2004 classification system.

\* Corresponding author.

E-mail address: [drshikha2307@gmail.com](mailto:drshikha2307@gmail.com) (S. Asotra).

Several entities, including germ cell tumors, sex cord-stromal tumors, tumors containing both germ cells and sex-cord stromal cells, a miscellaneous group of testicular tumors and paratesticular tumors were updated in the 2016 classification.<sup>5</sup> Recently there has been a radical revision in the 2016 WHO classification, especially to germ cell tumors.<sup>6</sup> Known risk factors for developing testicular tumor include a family history of testicular tumor in a first degree relative, infertility, cryptorchidism, Klinefelter's syndrome, birth weight, gestational age, inguinal hernia and some uncommon factors like trauma and hormones.<sup>7,8</sup> Thus, a combination of genetic, and environmental factors contributes to the etiology of testicular tumors. Despite advances in radiological and newer techniques in tumor marker assays, histopathological examination of orchidectomy specimens and testicular biopsies, by enlarge, anchor the diagnosis of testicular tumors.<sup>4</sup>

## 2. Aim and Objectives

1. To study the incidence of testicular lesions.
2. To study the histomorphological spectrum of testicular lesions including non-neoplastic as well as neoplastic lesions.
3. To study age-wise distribution, laterality and clinical presentation in testicular lesions.

## 3. Materials and Methods

The present study is an observational study, carried out in the Pathology Department of Indira Gandhi Medical college, a tertiary care hospital in the northern India, over a duration of two years i.e from June 2020 to May 2022. A total of 52 radical orchidectomy and testicular biopsies were studied for gross and microscopic findings. Clinical details like age, laterality, family history, history of risk factors, and serum markers of the patients were recorded from the patient record section of the hospital and by talking to the patients directly wherever possible. All slides and requisition forms were reviewed and the clinical details, macroscopic and microscopic details were analyzed and different parameters like percentage, mean were calculated using SPSS software. Informed consent was taken from the patients and ethical clearance was taken from the ethical committee of Indira Gandhi Medical College, Shimla.

### 3.1. Inclusion criteria

1. All tumors and tumor like lesions of the testes were included in the study and were categorised according to the 2016 WHO classification of testicular tumors.

### 3.2. Exclusion criteria

1. Therapeutic orchidectomies for prostate cancer, recurrent tumors and tumors occurring secondary to

radiation induced damage were excluded from the study.

## 4. Results

The present study comprised of total 52 cases. 45 orchidectomy specimens and 7 testicular biopsies were studied. Out of these, 42 cases were non neoplastic and 10 were neoplastic.

The youngest patient was a 6-month-old male child while the oldest was 78 years old. Maximum number of patients presented in the 2<sup>nd</sup> & 4<sup>th</sup> decade of life. Among neoplastic lesions, the youngest patient was 9 years old and oldest was 75 years old. The mean age for non-neoplastic lesions was 33.32 years and for neoplastic lesions was 33.40 years. (Table 1, Table 2)

Histologically, among non-neoplastic testicular lesions (42/52;80.76%), undescended testis was the most common diagnosis (17/42;40.47%), followed by testicular torsion (12/42;28.57%). Undescended testis and testicular torsion thus constituted most of the non-neoplastic testicular lesions (29/42;69.04%). Atrophic testis was found in 5/42(11.90%) cases in the present study. Inflammatory lesions included non-specific epididymo-orchitis, tubercular epididymo-orchitis and organised abscess comprising 3/42(7.14%), 1/42(2.38%) and 2/42(4.76%) cases. Single case (1/42;2.38%) of calcinosis cutis was also found in the present study along with a single case of testicular trauma (1/42;2.38%). (Table 4) Most of the non-neoplastic lesions were found in the 2<sup>nd</sup> decade of life (12/42;28.57%).

Among neoplastic lesions (10/52;19.23%), in the present study, 8(80%) were germ cell neoplasms, 2;(20%) were NHL. Among the germ cell tumors, 5(62.5%) cases were seminomas and 3(37.5%) cases were non-seminomatous germ cell tumors. Among non-seminomatous germ cell neoplasms, 2 were mixed germ cell tumors (Immature teratoma + Embryonal carcinoma and Seminoma + Yolk Sac Tumor+ Mature Teratoma) and 1 was malignant non-seminomatous germ cell tumor (Yolk Sac Tumor). (Table 3) Most of testicular neoplasms were seen in the 3<sup>rd</sup> and 4<sup>th</sup> decade of life (6/10;60%), 1 case each in the 1<sup>st</sup> & 5<sup>th</sup> decade and 2 cases in the 8<sup>th</sup> decade of life.

Clinically, most of the patients presented with scrotal swelling (58.53%), empty scrotum (40.47%) pain (36.53%), fever (11.53%) and tenderness (7.69%).

Right testis was involved more commonly (32/52;61.53%) than left testis (20/52;38.46%). Bilateral testicular involvement was not seen in any of the cases.

Tumor markers were done, revealing elevated AFP in the single case of YST and in 3 seminoma cases. One case of seminoma also revealed hcg elevation.

**Table 1:** Showing age-wise distribution of various non-neoplastic testicular lesions

Tumor type-lesion	0-10	11-20	21-30	31-40	41-50	51-60	61-70	71-80	Total
Undescended testis	1	5	3	3	4	1	0	0	17
Torsion	0	2	1	3	4	1	0	1	12
Atrophic testis	0	2	0	1	1	0	1	0	5
Epididymo-orchitis	0	1	1	1	0	0	0	0	3
Tubercular epididymo-orchitis	0	1	0	0	0	0	0	0	1
Organized abscess	0	1	1	0	0	0	0	0	2
Calcinosis cutis	0	0	0	1	0	0	0	0	1
Trauma	0	0	0	1	0	0	0	0	1
Total	1	12	6	10	9	2	1	1	42

**Table 2:** Showing age-wise distribution of various neoplastic testicular lesions

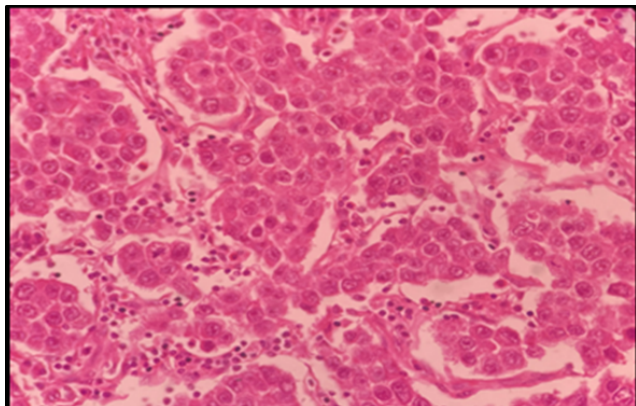
Tumor type	0-10	11-20	21-30	31-40	41-50	51-60	61-70	71-80	Total
Seminoma	0	0	1	3	1	0	0	0	5
MGCT									
Seminoma+YST+Mature teratoma	0	0	1	0	0	0	0	0	1
Immature teratoma+Embryonal Ca	0	0	1	0	0	0	0	0	1
YST	1	0	0	0	0	0	0	0	1
NHL	0	0	0	0	0	0	0	2	2
Total	1	0	3	3	1	0	0	2	10

**Table 3:** Showing distribution of testicular tumors

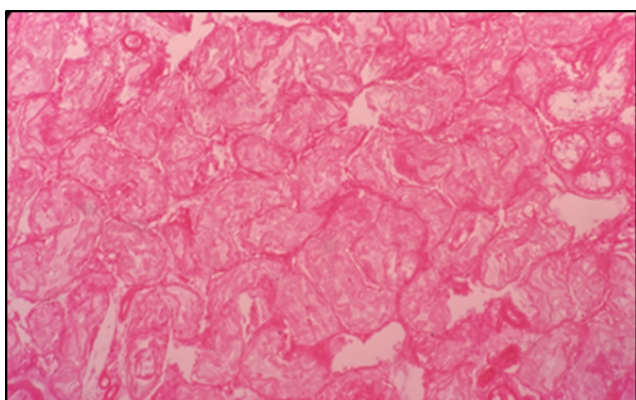
Tumor Type	No. of cases	%
seminoma	5	50%
MGCT	2	20%
YST	1	10%
NHL	2	20%
Total	10	100%

**Table 4:** Shows distribution of tumor like lesions

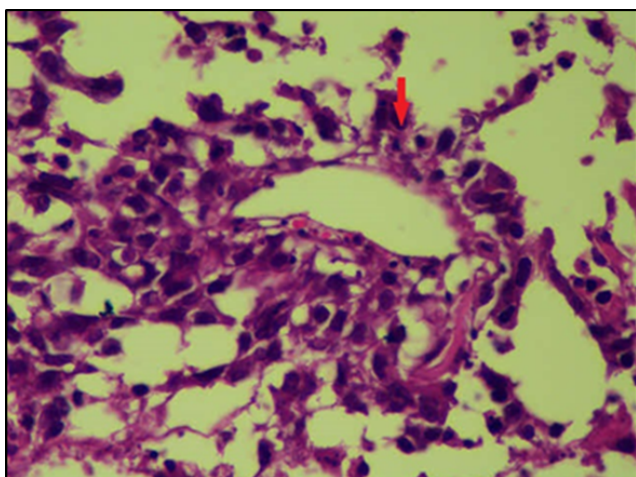
Tumor-like lesion	No of cases	%
Undescended testes	17	40.47%
Torsion	12	28.57%
Atrophic testes	5	11.90%
Epididymo-orchitis	3	7.14%
Tubercular epididymo-orchitis	1	2.38%
Organised abscess	2	4.76%
Calcinosis cutis	1	2.38%
Trauma	1	2.38%
Total	42	100%



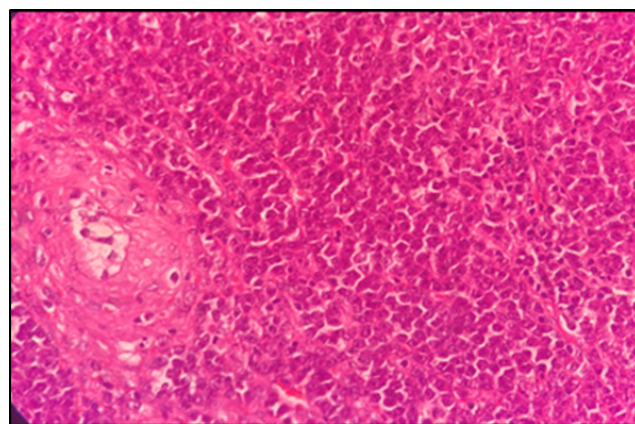
**Fig. 1:** Lobules of polygonal tumor cells with prominent nucleoli, separated by fibrous septae with lymphocytic infiltrate



**Fig. 2:** Showing small tubules with thickened basement membranes and absence of any germ cells in atrophic testis



**Fig. 3:** Schiller-Duval body in YST.(arrow)



**Fig. 4:** Showing diffuse infiltrate of anaplastic tumor cells in the interstitium surrounding atrophic seminiferous tubules. Testicular NHL

## 5. Discussion

Testicular cancers represent 10.5% of all male reproductive cancers in India.<sup>9</sup> Various studies have been done to access the incidence of neoplastic and non-neoplastic testicular lesions. Our study was also an attempt to do so. In the present study, 19.23% lesions turned out to be malignant and 80.76% were benign. This was in concordance to the studies done by Reddy H et al, Patel MB et al and Sharma et al.<sup>10–12</sup> Sanjay M et al<sup>13</sup> however, revealed slightly variable results as compared to the present study, with 28.07% (16/57) cases being neoplastic and remaining 82.54% (41/57) being tumor like lesions. Testicular swelling was the chief complaint in 86.53% patients in the present study. This was also in concordance to studies done by Reddy H et al., Patel MB et al., Sharma et al. and Sanjay et al.<sup>10–13</sup> Right sided testis was more commonly involved in the present study. Similar findings were seen in Patel MB's and Sharma M's studies'.<sup>11,12</sup> However, similar was not the case in the study done by Reddy H et al.<sup>10</sup> cryptorchidism was the most common (17/42;40.47%) non-neoplastic lesion in the present study, followed by testicular torsion (12/42;28.57%). Our findings were similar to study done by Sharma et al.<sup>4</sup> However, these findings were not comparable with the previous studies<sup>10,11,14</sup> where torsion was the most common non-neoplastic lesion. Cryptorchidism is the single most important risk factor associated with testicular cancer with 10% of all testicular cancer patients having history of cryptorchidism. Although we found 17 cases of undescended testis, none of them showed neoplastic focus and also none of the cases of testicular neoplasms had history of undescended testis. Our finding is in concordance with Reddy H et al and Sharma et al.<sup>10,12</sup> The incidence of non-neoplastic lesions was higher in the 2nd decade of life in the present study. This was in comparison to the study done by Sharma et al<sup>12</sup> but was not comparable with the results given by Reddy et al. and Abdulkadir et

al.<sup>10,15</sup> These variations could be because of demographic reasons and because of the vast histopathological spectrum of benign lesions of testicular origin.

Similar to the previous studies, testicular tumors were rare in the present study as well. Incidence of neoplastic testicular lesions was 19.23% in the present study. Most of the neoplastic lesions were seen in the 3rd and 4th decade of life, which was similar to the findings of various studies.<sup>10,16</sup> Mostofi and Price<sup>17</sup> described that germ cell tumors constitute more than 94% and stromal tumors consist of 3% of testicular tumors. In the present study, germ cell tumors formed the main bulk, representing about 80% of all testicular cancers. This was in concordance to the study done by various authors,<sup>10,12,18</sup> however no stromal tumors were reported in the present study. Seminoma was the most common histological type encountered in the present study (5/10,50%) with mean age of 37.6 years. This was in comparison to the study done by Sanjay M et al and Chakrabarti et al.<sup>13,16</sup> Pratap VK et al. and Reddy et al reported mean age of 41.25 years and 40 years respectively.<sup>12,19</sup> In young adults, seminoma, embryonal carcinoma, teratoma, and teratocarcinoma are common but seminoma is more common in the fourth decade whereas spermatocytic seminoma and lymphoma occur in the elderly. In the present study as well, seminoma was seen most commonly in the 4th decade. Among non-seminomatous germ cell tumors, 2 mixed germ cell tumors (20%) and 1 Yolk Sac tumor (10%) were reported in the present study, with mean age of 17.33 years, which was in close comparison to the findings of Sanjay M et al.<sup>13</sup> Embryonal carcinoma and teratoma are more frequently encountered combination of mixed germ cell tumors constituting about 24% of all testicular tumors. In the present study, we reported 1 case having a mixture embryonal carcinoma and teratoma while other combination found was of teratoma with YST and Seminoma. Non-seminomatous tumours are known to present in younger age than seminomatous type, which was the case in the present study. The youngest patient with neoplastic lesion, in the present study, was diagnosed yolk sac tumor, was 9 years old. 2 cases of Non-Hodgkin Lymphoma were reported in the present study with mean age of 75.5 years. Primary malignant lymphomas of testis are rare and constitute about 5% of all testicular neoplasm. In present study, other than germ cell tumor, lymphomas were the next most common tumor constituting about 20% cases. These findings are in comparison with Chakrabarti et al.<sup>16</sup> Sanjay M et al. reported 11.11% cases of lymphoma in their study. Reddy et al<sup>10</sup> and Sharma et al<sup>12</sup> did not report any case of testicular lymphoma in their respective studies.

## 6. Conclusion

Germ cell tumors accounted for highest percentage of cases with a commonest subtype of seminoma followed by mixed

germ cell tumors. Patients diagnosed with testicular tumors were mostly in 3<sup>rd</sup> and 4<sup>th</sup> decade. Right side laterality was prevalent. Testicular tumors and tumor like lesions have similar presentation in the form of scrotal swelling and pain. The incidence of testicular neoplasm still remains low in India which is reflected by the scarcity of studies in published literature. Histopathologic examination can help in accurately diagnosing and determining the prognosis of these rare tumor and tumor like lesions of testis.

## 7. Source of Funding

None.

## 8. Conflict of Interest


None.

## References

1. Purdue MP, Devesa SS, Sigurdson AJ, McGlynn KA. International patterns and trends in testis cancer incidence. *Int J Cancer*. 2005;115(5):822–7.
2. Liu S, Wen SW, Mao Y, Mery L, Rouleau J. Birth cohort effects underlying the increasing testicular cancer incidence in Canada. *Can J Public Health*. 1999;90(3):176–80.
3. Shanmugalingam T, Soultati A, Chowdhury S, Rudman S, Hemelrijck MV. Global incidence and outcome of testicular cancer. *Clin Epidemiol*. 2013;5:417–27.
4. Sharma M, Mahajan V, Suri J, Kaul K. Histopathological spectrum of testicular lesions- A retrospective study. *Indian J Pathol Oncol*. 2017;4(3):437–41.
5. Al-Obaidy KI, Idrees MT, Muhammad T. Testicular Tumors: A Contemporary Update on Morphologic, Immunohistochemical and Molecular Features. *Adv Anat Pathol*. 2021;28(4):258–75.
6. Moch H, Amin MB, Berney DM, Compérat EM, Gill AJ, Hartmann A, et al. The 2022 World Health Organization Classification of Tumours of the Urinary System and Male Genital Organs-Part A: Renal, Penile, and Testicular Tumours. *Eur Urol*. 2022;82(5):458–68.
7. Assi T, Rassy M, Nassereddine H, Sader-Ghorra C, Abadjian G, Ghosn M, et al. Distribution of Testicular Tumors in Lebanon: A Single Institution Overview. *Asian Pac J Cancer Prev*. 2015;16(8):3443–6.
8. Chakrabarti PR, Dosi S, Varma A, Kiyawat P, Khare G, Matreja S. Histopathological Trends of Testicular Neoplasm. *J Clin Diagn Res*. 2016;10(6):16–8.
9. Takiar R, Kumar S. Pattern of reproductive cancers in India. *Asian Pac J Cancer Prev*. 2014;15:599–603.
10. Reddy H, Chawda H, Dombale VD. Histomorphological analysis of testicular lesions. *Indian J Pathol Oncol*. 2016;3(4):558–63.
11. Patel MB, Goswamy HM, Parikh UR, Mehta N. Histopathological study of testicular lesions. *Gujarat Medical Journal*. 2015;70:41–6.
12. Sharma M, Mahajan V, Suri J, Kaul KK. Histopathological spectrum of testicular lesions- A retrospective study. *Indian J Pathol Oncol*. 2017;4(3):437–41.
13. Sanjay M, Sushma HM. Histomorphological spectrum of tumor and tumor like lesions of testis and paratesticular structures - A cross sectional study. *Indian J Pathol Oncol*. 2016;3(4):528–34.
14. Abba K, Tahir MB, Dogo HM, Nggada HA. Testicular and Paratesticular Non- Neoplastic lesions in University of Maiduguri Teaching Hospital: A 10-year Retrospective Review. *Bo Med J*. 2016;13(1):39–44.
15. Abdulkadir A, Sanusi HM, Alhaji SA. Histopathological pattern of testicular lesions in Kano, Northwestern Nigeria. *Niger J Surg*. 2019;25(2):158–62.

16. Chakrabarti PR, Dosi S, Varma A, Kiyawat P, Khare G. Histopathological Trends of Testicular Neoplasm: An Experience over a Decade in a Tertiary Care Centre in the Malwa Belt of Central India. *J Clin Diagn Res.* 2016;10(6):16–8.
17. Mostofi KF, Price EB. Tumors of the male genital system. Atlas of Tumor Pathology, Fascicle 7, Series 2. Armed Forces Institute of Pathology; 1973. p. 1186–1200.
18. Assi T, Rassy M, Nassereddine H, Sader-Ghorra C, Abadjian G, Ghosn M, et al. Distribution of Testicular Tumors in Lebanon: A Single Institution Overview. *Asian Pac J Cancer Prev.* 2015;16(8):3443–6.
19. Pratap VK, Agarwal S. Testicular neoplasm. *Indian J Cancer.* 1971;p. 40–53.

### Author biography

**Shikha Sharma**, Resident  <https://orcid.org/0000-0003-1208-729X>

**Sarita Asotra**, Associate Professor

**U. K. Chandel**, Professor

**Cite this article:** Sharma S, Asotra S, Chandel UK. Histopathological spectrum of testicular lesions in a tertiary care hospital. *Indian J Pathol Oncol* 2022;9(4):306-311.