

Content available at: <https://www.ipinnovative.com/open-access-journals>

Indian Journal of Pathology and Oncology

Journal homepage: [www.ijpo.co.in](http://www.ijpo.co.in)

## Case Report

# Primary hepatic neuroendocrine tumor with sarcoid like granulomas: A case report

Pankaj Kumar<sup>1,\*</sup>, Sunil Kumar<sup>2</sup>, Kim Vaiphei<sup>1</sup>, Rajender Kumar<sup>1</sup>

<sup>1</sup>Dept. of Histopathology, Postgraduate Institute of Medical Education and Research, Chandigarh, India

<sup>2</sup>Dept. of Nuclear Medicine, Postgraduate Institute of Medical Education and Research, Chandigarh, India



### ARTICLE INFO

#### Article history:

Received 14-07-2022

Accepted 21-07-2022

Available online 26-08-2022

#### Keywords:

Neuroendocrine tumor

Sarcoid like reaction

DOTA- PET

Granuloma

### ABSTRACT

**Introduction:** Primary hepatic neuroendocrine tumor (PHNET) is a rare entity comprising 0.3% of all neuroendocrine tumors. Tumors coexisting with granulomas are occasionally noted with malignancies in the lymph nodes draining the tumor or within the primary tumor itself. Tumor-related sarcoid reactions are noted only in carcinomas and its association with a NET has been extremely rare.

**Case Presentation:** We report a case of PHNET in a 63-year male who presented with various comorbidities who was incidentally detected with a liver space-occupying lesion (SOL). Contrast enhanced CT scan of the abdomen revealed a well-defined exophytic mass in the liver involving segment 6. Subsequently, 68Ga DOTANOC PET/CT scanning revealed somatostatin receptor-expressing well-defined lesion measuring 5.1 x 5.0 cm in segment 6 (SUV MAX 19). A diagnosis of either a primary or a metastatic neuroendocrine tumor was made and non-anatomical wedge resection of the tumor was done with a detailed exploration of the abdominal cavity to look for a primary focus that did not reveal any other lesion or mass. Histologically, the tumor was confirmed to be a Neuroendocrine Tumor along with the presence of tumor-related sarcoid like granulomas in the adjoining hepatic parenchyma.

**Conclusion:** Diagnosis of a PHNET requires a combination of a negative abdominal survey at the time of the operative procedure, pathologic evaluation of specimen, and a negative imaging workup for extrahepatic NET in both the pre and postoperative settings.

This is an Open Access (OA) journal, and articles are distributed under the terms of the [Creative Commons Attribution-NonCommercial-ShareAlike 4.0 License](https://creativecommons.org/licenses/by-nc-sa/4.0/), which allows others to remix, tweak, and build upon the work non-commercially, as long as appropriate credit is given and the new creations are licensed under the identical terms.

For reprints contact: [reprint@ipinnovative.com](mailto:reprint@ipinnovative.com)

## 1. Introduction

Neuroendocrine tumor (NET) constitutes 1-2% of all gastrointestinal tumors. The liver is involved frequently as a metastatic focus.<sup>1</sup> Primary hepatic neuroendocrine tumor (PHNET) is a rare entity comprising 0.3% of all neuroendocrine tumors.<sup>2</sup> Edmondson reported the first case in 1958.<sup>2</sup> Since these tumors constitute only a small proportion of NET, the approach to diagnosis and management is not well established. With the surgical approach as the primary modality of treatment, overall, 5 and 10 years survival rates are 78% and 73% respectively.<sup>2,3</sup>

Tumors coexisting with granulomas are occasionally noted with malignancies in the lymph nodes draining the tumor or within the primary tumor itself. Tumor-related sarcoid like granuloma requires the presence of compact non-caseating granuloma without clinical features of systemic sarcoidosis.<sup>4</sup> The tumor-related sarcoid reaction occurs in only 4% of carcinomas and its association with a NET has been reported only once in a pancreatic NET.<sup>5</sup> We report a case of PHNET in a 63-year male who presented with various comorbidities who was incidentally detected with a liver space-occupying lesion (SOL).

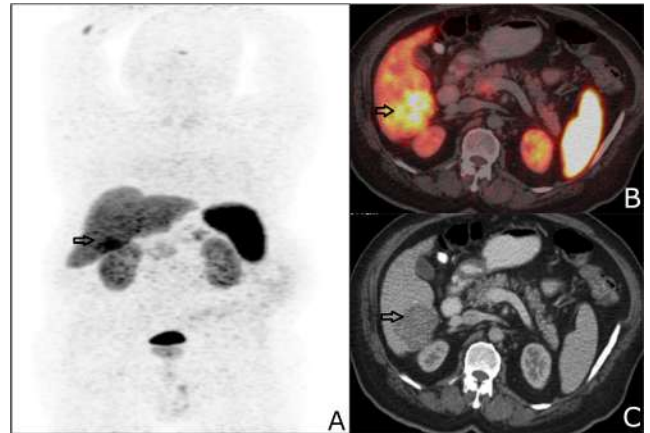
\* Corresponding author.

E-mail address: [bsc.pankaj@gmail.com](mailto:bsc.pankaj@gmail.com) (P. Kumar).

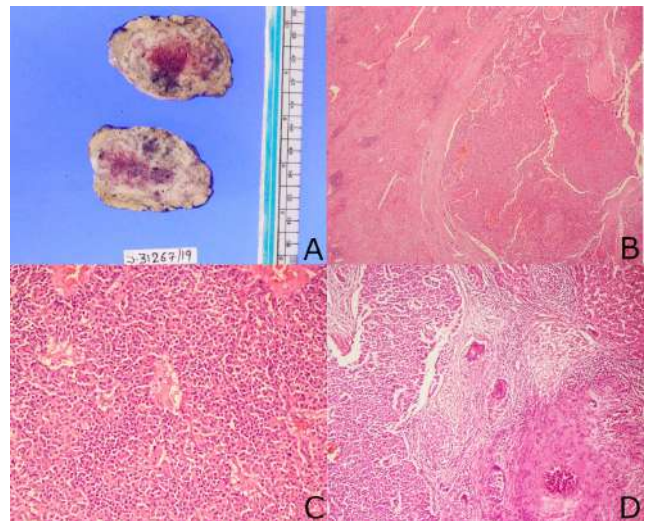
## 2. Case Report

A 63-year male was on follow-up for essential hypertension, Type 2 diabetes mellitus, and subclinical hypothyroidism, presented with acute problems related to acute coronary ischemia and heart failure. On routine examination, he was found to have mild hepatomegaly with no palpable spleen and ascites. There was no significant family history. His routine laboratory investigation profiles of haemogram, renal, and liver function tests were within normal limits. Serum amylase 48 U/L, Serum gastrin 12 pgM, CEA 1.88 ng/ml, AFP 1.21 ng/ml, TSH 6.57 mIU/L, T3 1.15  $\mu\text{g/dl}$ , T4 8.87  $\mu\text{g/dl}$ , GH 0.38 ng/ml, RBS 170 mg/dl, FBS- 103 mg/dl, IGF1 257.6 ng/ml, Basal insulin 7.84, C Peptide- 15.94 ng/ml and HIAA (24 hour urinary)- 2mg/hr. Contrast enhanced CT scan of the abdomen revealed a well-defined exophytic mass in the liver measuring 4.9  $\times$  5.1 cm involving segment 6. Subsequently patient underwent 68Ga DOTANOC PET/CT scanning revealed a somatostatin receptor-expressing well-defined lesion measuring 5.1  $\times$  5.0 cm in segment 6 (SUV MAX 19). No other abnormal somatostatin receptor-expressing focus in the body were noted. A diagnosis of either a primary or a metastatic neuroendocrine tumor was made and the patient was taken up for surgery. A non-anatomical wedge resection of the tumor was done. A detailed exploration of the abdominal cavity to look for a primary focus did not reveal any other lesion or mass. The post-operative period was uneventful and on follow-up, the patient has no evidence of recurrence radiologically and clinically to date.

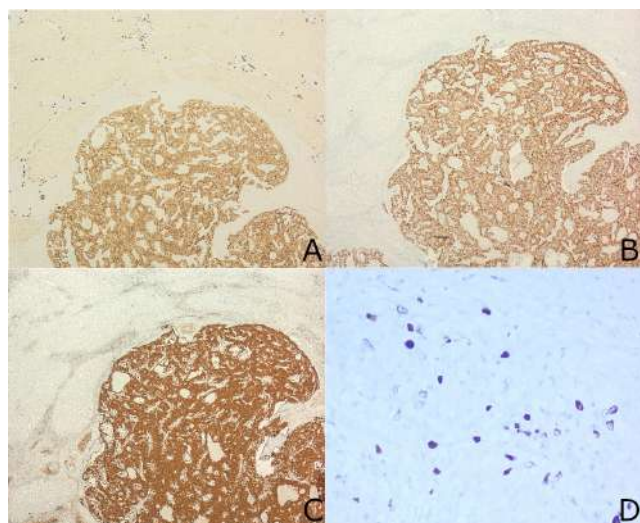
The wedge resected specimen measured 6x4x1.5 cm and the capsular aspect showed a greyish white nodule. On serial slicing the tumor was sub-capsular in location, measuring 5.2x4x4 cm. Cut surface showed a brownish tumor with areas of congestion giving a variegated appearance with internal septations and areas of hemorrhages. Surrounding liver parenchyma was unremarkable. On histology, the tumor was observed to be poorly circumscribed. Tumor cells showed organoid, trabeculae, and cord patterns of arrangement with intervening delicate capillary network and hyalinised fibrous septae. The tumor cells were polygonal in shape with monomorphic round nuclei with stippled chromatin, inconspicuous nucleoli, and scant to moderate pale eosinophilic cytoplasm. Mitosis was 4 per 10 high power field (hpf). The advancing edge of the tumor showed multiple well-formed compact epithelioid cell granulomas with multinucleated Langhan type of giant cells. The surrounding liver parenchyma showed maintained lobular architecture, portal tracts with minimal lymphomononuclear cell infiltrate. Immunohistochemistry showed tumor cells positive for cytokeratin (Cell Marque, 1:300), synaptophysin (Cell Marque, 1:300), Chromogranin A (Dako, 1:200), and CD56 (Dako, 1: 80), however negative for HepPar 1 (Dako, 1: 300). The Ki 67 index was 10% in the highest proliferative areas.



**Fig. 1:** A): Maximum intensity projection (MIP) images show focal tracer uptake in the liver; B) and C): Transaxial fused 68Ga DOTANOC PET/CT and corresponding axial CT images respectively showing somatostatin receptor-expressing lesion in segment VI of the liver



**Fig. 2:** A): Gross specimen shows well-circumscribed fleshy and soft to firm tumor with variegated appearance and areas of hemorrhage; B): On histology, the tumor is poorly circumscribed and is arranged in organoid and trabeculae; C): The tumor cells are relatively monomorphic with round nuclei, stippled chromatin, inconspicuous nucleoli, and scant to moderate eosinophilic cytoplasm; D): Surrounding hepatic parenchyma shows compact epithelioid cell granulomas, multinucleated giant cells, and fibrosis



**Fig. 3:** A): Immunohistochemistry show tumor positive for cytokeratin, chromogranin; B): and synaptophysin; C): D): Ki 67 index shows nearly 10% proliferative index

### 3. Discussion

PHNET is a very rare tumor with less than 200 cases reported to date.<sup>6</sup> Rarity could be explained by the fact NETs arising from neuro-ectodermal cells, which migrate from the neural crest during embryogenesis are not found in the liver routinely.<sup>7</sup> Various hypotheses have been postulated to explain the pathogenesis of PHNETs, one of the possibilities is that they originate from ectopic pancreatic or adrenal tissues within the liver.<sup>8,9</sup> Another postulation is the chronic inflammation in the biliary system may initiate intestinal metaplasia, which predisposes to the development of neuroendocrine tumors.<sup>7</sup> According to previous literature, PHNETs are more common in women in the 4th and 5th decades of life.<sup>3</sup> These tumor are slow-growing and non-functional though rarely they may present with carcinoid syndrome<sup>10</sup> and jaundice due to mass effect.<sup>11</sup> Right lobe involvement has been reported more frequently and is often solitary (76.6%).<sup>3</sup> Close differential diagnosis of these tumors remains other more common liver lesions like hydatid cyst, hepatocellular carcinoma, cholangiocarcinoma, and other metastatic carcinomas. Serum level of chromogranin A and 24-hour urine HIAA (5-hydroxyl indoleacetic acid) show promising sensitivity and specificity in diagnosing NET. CgA can be used for monitoring carcinoma recurrence. Serum markers like CEA, CA19–9, and AFP are not specific for PHNECs<sup>12</sup>.

Radiological investigations like USG, CT, and MRI are of low sensitivity imaging modality as PHNETs are hypervascular tumor like metastatic NETs to the liver.<sup>10</sup> 68Ga DOTA peptide PET/CT is a highly useful imaging modality in the diagnosis and staging of NETs with a sensitivity and specificity of 92% and 98% respectively.<sup>13</sup>

Grossly, NETs are mostly solitary, circumscribed with a soft consistency, and may show necrosis. Histologically, PHNETs show an insular, acinar, trabecular, nested, or mixed pattern of growth. The cells show round nuclei with characteristic salt and pepper chromatin. The intense cytoplasmic granularity as seen in gut NETs is not found in hepatic primaries and would suggest metastasis from the occult primary. Even if morphological features suggest neuroendocrine carcinoma, hepatocellular carcinoma needs to be excluded as the growth patterns overlap. The diagnosis can be confirmed on immunohistochemistry as a neuroendocrine tumor is positive for synaptophysin, CD 56, chromogranin, and cytokeratins, which are however negative for hepatocytic markers like arginase and hepPar1. On the basis of proliferative activity, NETs are graded as G1 (< 2 mitosis/2 mm<sup>2</sup> or ki-67 proliferation index <3%), G2 (2-20 mitosis/2 mm<sup>2</sup> or a Ki-67 index of 3-20%) or G3 (>20 mitosis/2 mm<sup>2</sup> or Ki-67 index >20%). Hepatic NETs can be WHO grade G1 or G2, G3 NETs have not been reported in the liver yet.<sup>14</sup>

Surgical resection of the tumor with negative margins is the preferred treatment modality as up to 85% of tumors are resectable.<sup>11</sup> 5 year survival after surgery is as good as 74-78%.<sup>15</sup> For unresectable tumors, liver transplantation and TACE (transcatheter arterial chemoembolization) are the alternative modalities.<sup>11</sup>

The relationship between sarcoidosis/sarcoid-like reaction and the solid malignant tumor is less frequent with most commonly described in lung adenocarcinoma.<sup>16</sup> Hematological malignancies like non-Hodgkin's lymphoma and Hodgkin's lymphoma are mainly associated with sarcoidosis/sarcoid-like reaction. In nearly 76% of cases, sarcoidosis precedes the diagnosis of neoplasm. However, individuals without any clinical signs of systemic sarcoidosis, regional lymph nodes draining malignant tumor, the primary tumor itself, and even non-regional tissues may show compact non-caseating epithelioid cell granulomas. The sarcoid-like reaction occurs with an average frequency of 4% in carcinoma, 7% in non-Hodgkin's lymphoma, and 14% in Hodgkin's disease. The mechanism for sarcoid like granulomas represents T-cells mediated immune response to the tumor antigens.<sup>5,16</sup>

### 4. Conclusion

PHNET is a rare tumor with vague clinical presentation and radiological features. Diagnosis of a PHNET requires a combination of a negative abdominal survey at the time of the operative procedure, pathologic evaluation of specimen, and a negative imaging workup for extrahepatic NET in both the pre-and postoperative settings. Surgery with negative margins is the preferred treatment modality. Given that the recurrence rate is high despite complete surgical resection (19.8%), close follow-up is of paramount importance.

## 5. Source of Funding

None.

## 6. Conflict of Interest

None.

## References

1. Modlin IM, Sandor A. An analysis of 8305 cases of carcinoid tumors. *Cancer*. 1997;79(4):813–29.
2. Edmonson H. Tumor of the liver and intrahepatic bile duct. *Atlas Tumor Pathol*. 1958;7(25):105–9.
3. Lin CW, Lai CH, Hsu CC, Hsu CT, Hsieh PM, Hung KC, et al. Primary hepatic carcinoid tumor: a case report and review of the literature. *Cases J*. 2009;2(1):90.
4. Brincker H. Interpretation of Granulomatous Lesions in Malignancy. *Acta Oncol*. 1992;31(1):85–9.
5. Mastroroberto M, Berardi S, Fraticelli L, Pianta P, Ercolani G, Cancellieri A, et al. Sarcoidosis and Sarcoid-Like Reaction Associated with Pancreatic Malignancy: Are You Able to Read a Riddle. *J Pancreas (Online)*. 2012;13(4):454–7.
6. Geramizadeh B, Kashkoe A, Malekhosseini SA. Liver Metastasis of Gastrointestinal Neuroendocrine Tumors: A Single Center Experience. *Hepat Mon*. 2016;16(5):e37293.
7. Hsueh C, Tan XD, Gonzalez-Crussi F. Primary hepatic neuroendocrine carcinoma in a child. Morphologic, immunocytochemical, and molecular biologic studies. *Cancer*. 1993;71(8):2660–5.
8. Alpert LI, Zak FG, Werthamer S, Bochetto JF. Cholangiocarcinoma: a clinicopathologic study of five cases with ultrastructural observations. *Hum Pathol*. 1974;5(6):709–28.
9. Gravante G, DeLiguori NC, Overton J, Manzia TM, Orlando G. Primary carcinoids of the liver: a review of symptoms, diagnosis, and treatments. *Dig Surg*. 2008;25(5):364–8.
10. Wang LX, Liu K, Lin GW, Jiang T. Primary hepatic neuroendocrine tumors: comparing CT and MRI features with pathology. *Cancer Imaging*. 2015;15(1):13.
11. Deluzio MR, Barbieri AL, Israel G, Emre S. Two cases of primary hepatic neuroendocrine tumors and a review of the current literature. *Ann Hepatol*. 2017;16(4):621–9.
12. Yang K, Cheng YS, Yang JJ, Jiang X, Guo JX. Primary hepatic neuroendocrine tumors: multi-modal imaging features with pathological correlations. *Cancer Imaging*. 2017;17(1):20. doi:10.1186/s40644-017-0120-x.
13. Ambrosini V, Campana D, Tomassetti P, Fanti S. 68Ga-labelled peptides for diagnosis of gastroenteropancreatic NET. *Eur J Nucl Med Mol Imaging*. 2012;39(1):52–60.
14. Nagtegaal ID, Odze RD, Klimstra D, Paradis V, Rugge M, Schirmacher P. WHO Classification of Tumours Editorial Board. The 2019 WHO classification of tumors of the digestive system. *Histopathology*. 2020;76(2):182–8.
15. Knox CD, Anderson CD, Lamps LW, Adkins RB, Pinson CW. Long-term survival after resection for primary hepatic carcinoid tumor. *Ann Surg Oncol*. 2003;10(10):1171–5.
16. Brincker H. Sarcoid reactions in malignant tumors. *Cancer Treat Rev*. 1986;13(3):147–56.

## Author biography

**Pankaj Kumar**, Senior Resident  <https://orcid.org/0000-0003-1471-8075>

**Sunil Kumar**, Senior Resident  <https://orcid.org/0000-0003-3810-3649>

**Kim Vaiphei**, Professor  <https://orcid.org/0000-0002-6647-9320>

**Rajender Kumar**, Professor  <https://orcid.org/0000-0001-5098-5707>

**Cite this article:** Kumar P, Kumar S, Vaiphei K, Kumar R. Primary hepatic neuroendocrine tumor with sarcoid like granulomas: A case report. *Indian J Pathol Oncol* 2022;9(3):292-295.