



Case Report

Hodgkin lymphoma of skin masquerading as inflammatory breast carcinoma - A rare case report

Sakthidasan Chinnathambi P^{1,*}, Bharath Kumar¹

¹Dept. of Pathology, ESIC Medical College Hospital, Hyderabad, Telangana, India



ARTICLE INFO

Article history:

Received 22-06-2022

Accepted 05-07-2022

Available online 26-08-2022

Keywords:

Hodgkin lymphoma

Breast

Carcinoma

Skin

ABSTRACT

Hodgkin's Lymphoma is a B- Cell neoplasm occurring in lymph nodes and extra-nodal sites. Among the latter, skin involvement is a rare phenomenon with a very low incidence rate. Cutaneous involvement of Hodgkin's Lymphoma may have varied clinical presentations from erythematous papules to ulcers. However, a thorough search in histology shows the classic RS cells which are diagnostic of Hodgkin's lymphoma, but this needs a high degree of suspicion. Presentation of Hodgkin Lymphoma, in an elderly female patient of 60 years of age bearing erythematous skin changes over breast which made a clinical suspicion of inflammatory breast carcinoma, is presented here.

This is an Open Access (OA) journal, and articles are distributed under the terms of the [Creative Commons Attribution-NonCommercial-ShareAlike 4.0 License](https://creativecommons.org/licenses/by-nc-sa/4.0/), which allows others to remix, tweak, and build upon the work non-commercially, as long as appropriate credit is given and the new creations are licensed under the identical terms.

For reprints contact: reprint@ipinnovative.com

1. Introduction

Occurrence of Hodgkin's lymphoma (HL) in skin, is a rare phenomenon. Diagnosis of HL in skin over breast, requires a higher degree of suspicion. One such case of skin lesion bearing the features of HL, but masqueraded clinically as an inflammatory breast carcinoma, is being presented below.

2. Case Report

An elderly female patient of 60 years of age came to surgical oncology clinic, with chief complaint of lump in the left breast for one month. The breast lump was of sudden onset, rapidly progressing to attain the present size. History of loss of appetite and unquantifiable weight loss was noticed. There was no history of pain, fever, nipple discharge or recent nipple retraction. The right breast and axilla were unremarkable. No history of swelling elsewhere in the body. No past history of similar swelling in the breast. There was a painful swelling in the left axilla 6 months ago for which

excision biopsy was done which revealed features of acute lymphadenitis. No history of any other surgeries in the past. No significant family history.

On general examination, patient was well nourished and well-built. On inspection, right breast appeared to be normal and pendulous. Left breast was spherical and diffusely enlarged involving all the quadrants. It was situated at a higher level than the right. Skin over the left breast was erythematous, thick and shiny with peau-de-orange appearance, involving 3/4ths of the breast and extending up to the axillary tail. There was a round skin nodule of size 2 cm at the axillary tail region. Linear scar of previous surgery measuring 4cm was noted in the axilla with puckering of surrounding skin. There were multiple nodules all along the lower end of the scar largest being 2cm. Nipple was flat, dry with loss of lustre and there was no discharge from the nipple. No cracks or fissures noted over the areola. There was no edema in arm or no supraclavicular fullness. On palpation, left breast was warmer than the right and there was no definitive lump noted. Entire breast was fixed to the underlying pectoralis muscles, but not to the chest wall. Skin over the breast

* Corresponding author.

E-mail address: sakthidasanmbbs@gmail.com (S. Chinnathambi P).

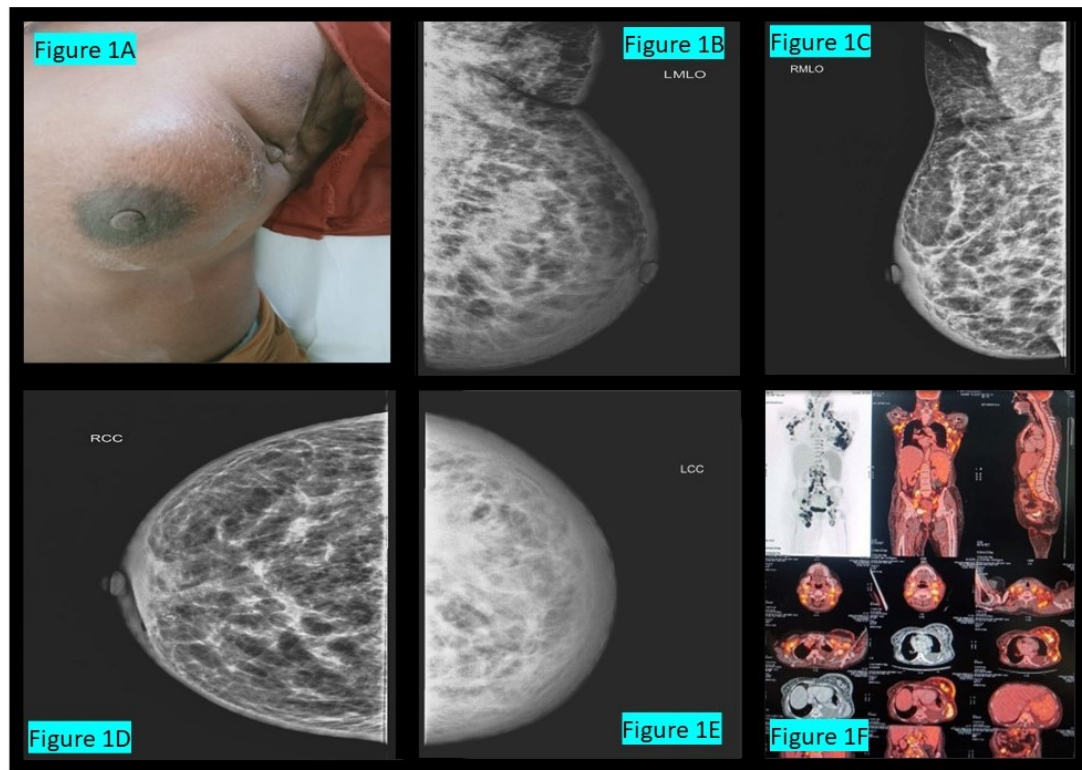


Fig. 1: **A:** Clinical photograph of the breast lesion; **B:** Mammogram picture showing mediolateral oblique view of left breast; **C:** Mammogram picture showing mediolateral oblique view of right breast; **D:** Mammogram picture showing craniocaudal view of right breast; **E:** Mammogram picture showing craniocaudal view of left breast; **F:** Picture showing Whole body FDG PET uptake scan at various organs

was thick and non-pinchable. Scar nodules were hard and fixed. There was no nipple discharge with gentle squeezing. On palpation of axillae, there were multiple, mobile and discrete, non-tender lymph nodes noted in left axilla and left supraclavicular region, largest of which measuring 2.5 cm. Right breast, axilla, arm, and supraclavicular region was normal. Considering these findings, a provisional clinical diagnosis of inflammatory breast carcinoma was rendered, with a stage of cT4dN3M0. Clinical image of the lesion is showed in (Figure 1 A) exhibiting prominent peau-de-orange appearance along with erythematous changes in skin over the breast tissue, with an adjacent linear scar in axilla. The patient was later worked up for mammography, USG of breast and whole body FDG PET scan. Mammography favoured Inflammatory Breast carcinoma. Mammography images are highlighted in (Figure 1 B-E). PET-CT showed FDG uptake in breast, supra and infra diaphragmatic nodes, left pleural space, spleen and bone marrow, thereby confirming mammographic findings as Inflammatory Breast Carcinoma (Figure 1 F)

A 5mm thick biopsy was taken from the skin over left breast and submitted for routine histopathological processing. Microscopic examination revealed an unremarkable epidermis with focal increase of melanin

pigmentation in basal layer. There was mild vacuolar degeneration noted at the dermo-epidermal interface. Dermis showed a diffusely infiltrative lesion composed of individually scattered atypical cells with areas of necrosis. On higher magnification the cellular lesional areas were found to be harbouring small lymphocytes admixed with large bi-nucleated Reed Sternberg (RS) cells with round to oval enlarged owl eye nuclei, bearing large pink nucleoli and moderate clear to amphophilic cytoplasm. Also noted are mononuclear RS cells (Hodgkin cells) with enlarged nuclei, prominent pink nucleoli bearing moderate cytoplasm, and occasional mummified RS cells scattered in the sections. Interestingly there were no obvious increase of eosinophils in background. There was no clear-cut demarcation of deep reticular dermis and sub-cutis, as the entire sub epithelial tissue was populated by these cells. (Figure 2 A-C). Immunostains performed with an automated IHC analyzer revealed RS cells highlighted by CD 15 and CD30 in a bright membranous staining pattern.(Figure 3 A,B) Other markers were employed such as estrogen receptor, progesterone receptor, Her2neu all of which showed negative staining, thus ruling out an epithelial neoplasm of native breast tissue. Ki67 index was high with 80% positivity in proliferative cells of dermis.

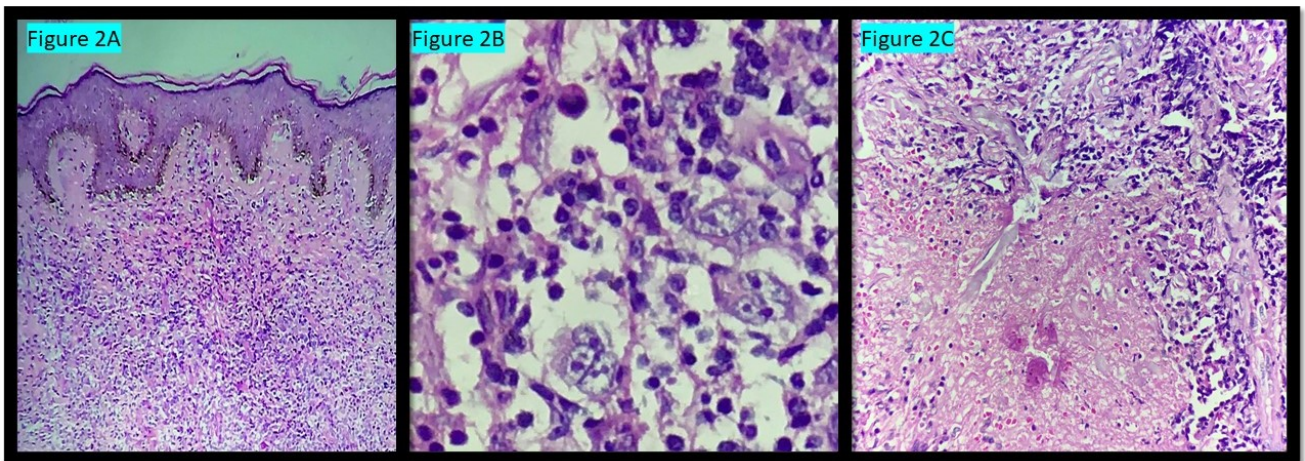


Fig. 2: **A:** Hodgkin's lymphoma involving skin [H&E, 4X]; **B:** Hodgkin's lymphoma involving skin, showing RS cells [H&E, 40X]; **C:** Hodgkin's lymphoma involving skin, showing foci of necrosis [H&E, 10X]

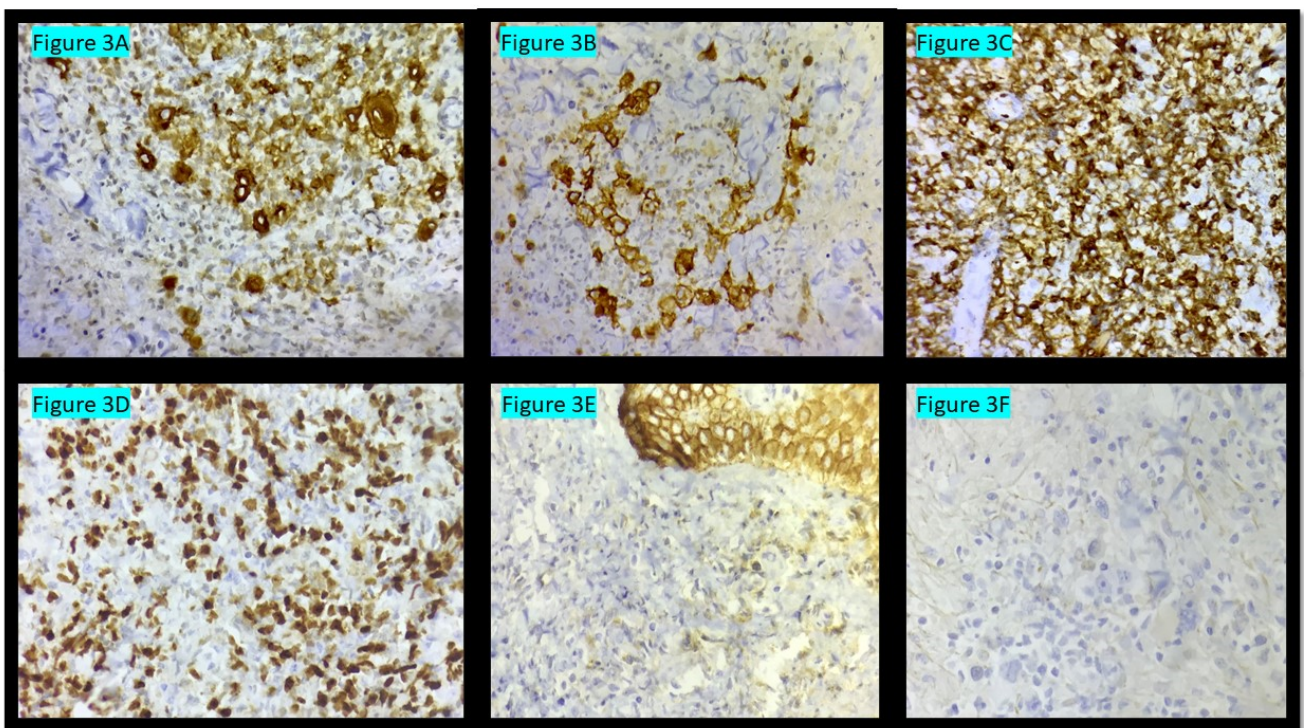


Fig. 3: **A:** Hodgkin's lymphoma involving skin, RS cells showing positivity for CD 15 antibody [IHC 40X]; **B:** Hodgkin's lymphoma involving Skin, RS cells showing positivity for CD 30 antibody [IHC 40X]; **C:** Hodgkin's lymphoma involving skin, showing negativity for CD 45 antibody in RS cells but positive in normal lymphoid cells [IHC 10X]; **D:** Hodgkin's lymphoma involving skin, showing 80% positivity for Ki-67 antibody [IHC 10X]; **E:** Hodgkin's lymphoma involving skin, showing positive control of EMA staining epidermis, but negative for RS Cells [IHC 10X]; **F:** Hodgkin's lymphoma involving skin, showing negativity for estrogen receptor [IHC 10X]

EMA stain showed positivity only in the overlying normal epidermis and few adnexal structures. Leucocyte Common Antigen (LCA) was negative in neoplastic lymphoid cells. (Figure 3 C-F)

3. Discussion

Incidence of HL in skin is very rare, accounting to 0.5 – 3.5%.¹ In skin, HL may present as papules, nodules, erythematous lesions and even as ulcers.^{2–4} Classical HL can be diagnosed by the prominence of bi-nucleated RS cells, as in this case. In the absence of bi-nucleated RS cells, it can be detected by mononuclear RS Cells albeit which may pose difficulty. This problem can be alleviated by the Immuno-histochemical stains which can pick up the neoplastic RS cells, but this needs a high degree of suspicion.⁵ In the present case, eosinophils were not observed as prominent as one used to see in a Hodgkin's Lymphoma involving lymph node.

According to White & Patterson, who reported a series of 16 patients of Hodgkin Lymphoma with skin involvement, HL spreads to skin through 3 possible routes, viz., retrograde lymphatic spread (11/16), direct extension (3/16) and hematogenous spread (2/16).⁶ Prognosis depends on the extent of spread, with limited spread responding well to early chemotherapy, while the prognosis is dismal with extensive spread. Other patterns of involvement are isolated cutaneous disease, which has an indolent behavior and very rarely as a paraneoplastic cutaneous vasculitis form, which responds well to chemotherapy.⁷ Lyapichev et al. reported a case of Hodgkin lymphoma involving skin, with a rare expression of CD3 in addition to markers for classical Hodgkin lymphoma.⁸

4. Conclusion

Hodgkin's Lymphoma may present as skin lesion, which in breast, can masquerade as an inflammatory breast carcinoma. An owl's eye is required to spot on the RS Cells, which can pave way for a treatment regimen with-out

surgery, but with a cure.

5. Source of Funding

None.


6. Conflict of Interest

None.

References

- Goyal S, Biswas A, Puri T, Gupta R, Muzumder S, Julka PK. Different faces of cutaneous Hodgkin's disease. *Indian J Dermatopathol Diagn Dermatol*. 2014;1(2):79–82.
- Sioutos N, Kerl H, Murphy SB, Kadin ME. Primary cutaneous Hodgkin's disease. Unique clinical, morphologic, and immunophenotypic findings. *Am J Dermatopathol*. 1994;16(1):2–8.
- Massaro F, Ferrari A, Zendri E, Zanelli M, Merli F. Atypical cutaneous lesions in advanced-stage Hodgkin lymphoma: A case report. *World J Clin Cases*. 2019;7(17):2513–8.
- Brahimi M, Attaf F, Arabi A, Bekadja MA. Skin in a Hodgkin lymphoma. *Hematol Oncol Stem Cell Ther*. 2013;6(2):68–70.
- Hsia CC, Howson-Jan K, Rizkalla KS. Hodgkin lymphoma with cutaneous involvement. *Dermatol Online J*. 2009;15(5):5.
- White RM, Patterson JW. Cutaneous involvement in Hodgkin's disease. *Cancer*. 1985;55(5):1136–45.
- Simon Z, Tarr T, Tóth L, Szucs G, Illés A. Cutaneous vasculitis as an initiating paraneoplastic symptom in Hodgkin lymphoma. *Rheumatol Int*. 2008;28(7):719–23.
- Lyapichev KA, You MJ. Unusual presentation of classic Hodgkin lymphoma. *Blood*. 2019;133(5):502.

Author biography

Sakthidasan Chinnathambi P, Assistant Professor
 <https://orcid.org/0000-0002-2914-4433>

Bharath Kumar, Senior Resident

Cite this article: Chinnathambi P S, Kumar B. Hodgkin lymphoma of skin masquerading as inflammatory breast carcinoma - A rare case report. *Indian J Pathol Oncol* 2022;9(3):288-291.