

Content available at: <https://www.ipinnovative.com/open-access-journals>

Indian Journal of Pathology and Oncology

Journal homepage: www.ijpo.co.in

Case Report

A unique case of HCC presenting as oral cancer

Mahesh Kalloli¹, Ankit Gupta^{1,*}, Rashmi S Patil¹,
Chenchulakshmi Vasudevan², Sanjiti Madan³

¹Dept. of Surgical Oncology, KLES Dr. Prabhakar Kore Hospital & MRC, Belagavi, Karnataka, India

²Dept. of ENT Head and Neck Surgery, Jawaharlal Nehru Medical College, Belagavi, Karnataka, India

³Dept. of Oral and Maxillofacial Surgery, KLES Dr. Prabhakar Kore Hospital & MRC, Belagavi, Karnataka, India



ARTICLE INFO

Article history:

Received 14-06-2022

Accepted 30-06-2022

Available online 26-08-2022

Keywords:

HCC

Hepatocellular carcinoma

Oral cavity metastasis

ABSTRACT

Recently developing countries showing growing trend in hepatocellular carcinoma cases. Hepatocellular carcinoma metastasis to oral cavity is uncommon finding. Most common site for mets is lung, breast, kidney. Data on HCC metastasis to oral cavity is limited. We present here one such rare case of HCC metastasis to oral cavity. Awareness about the entity helps in early diagnosis and management that leads to better prognosis and good quality of life to patient.

This is an Open Access (OA) journal, and articles are distributed under the terms of the [Creative Commons Attribution-NonCommercial-ShareAlike 4.0 License](https://creativecommons.org/licenses/by-nc-sa/4.0/), which allows others to remix, tweak, and build upon the work non-commercially, as long as appropriate credit is given and the new creations are licensed under the identical terms.

For reprints contact: reprint@ipinnovative.com

1. Introduction

There have been few reports of metastasis of hepatocellular carcinoma being found in head and neck region. It has been reported that only 1-3% of oral malignancies are metastatic lesions from distant regions of the body like lung, prostate, kidney, bone and adrenal glands in men and breast, adrenal glands, colorectal system, genital organs in females in decreasing order.¹ Literature shows that metastatic lesions of HCC if found in the oral cavity may point towards an undiagnosed primary malignancy.²⁻⁵ It was Dick et al in 1957 who ever first reported a case of metastasis of HCC to the mandible.⁶ We hereby present a rare case that we came across, at our center, of HCC with its first manifestation being a growth in the mandibular region.

2. Case Report

A 72 years old male patient presented to the department of surgical oncology KLE's Dr Prabhakar Kore hospital

and medical research center, with a complaint of a growth in the posterior aspect of his right jaw since 2 months. The patient had no other comorbidities or previous illness or surgeries. He was a smoker but non-alcoholic. On examination he had an endophytic lesion over the alveolus of the posterior aspect of mandible on right side, extending from the first molar region to the retro-molar trigone area with involvement of lower gingivobuccal sulcus. The growth was 2 X 3.5 cm in size with indurated borders (Figure 1). Patient underwent routine blood investigations and incisional biopsy of the lesion. Routine investigations were normal and biopsy revealed moderately differentiated carcinoma. We went ahead with contrast enhanced CT scan of head and neck which was reported as heterogeneously enhancing lesion involving the posterior 3rd of the mandibular alveolar process infiltrating into the ramus of mandible extending into retromolar trigone measuring 3 X 2 X 3.3 cm (AP*TR*CC) with destruction of outer and inner cortices of involved mandible with involvement of inferior alveolar nerve.

* Corresponding author.

E-mail address: drankitgupta8@gmail.com (A. Gupta).

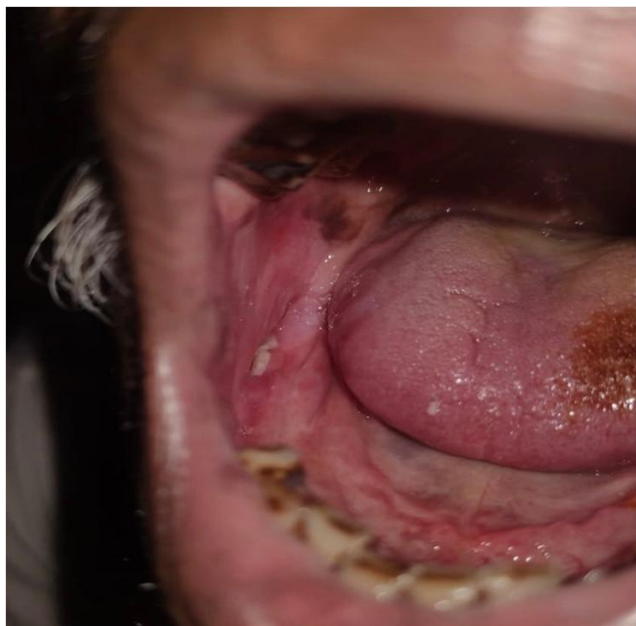

Fig. 1:

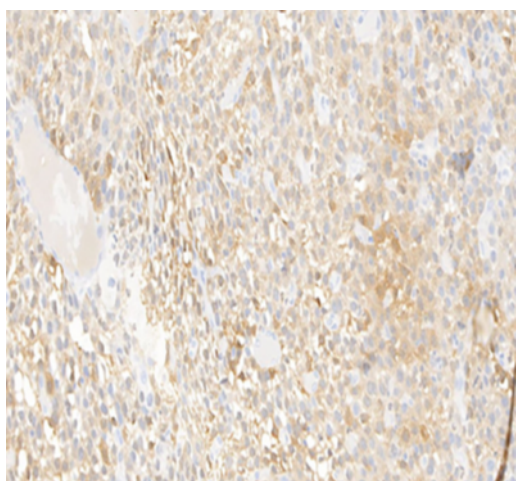


Fig. 2:

Level 1b node noted to be largest measuring 8 X 7 mm, following which he underwent surgery of wide local excision of buccal mucosa lesion with segmental mandibulectomy with right modified radical neck dissection with a PMMC flap reconstruction. The primary specimen was sent for HPE which reported poorly differentiated carcinoma rather than SCC and finally IHC showed adenocarcinoma of hepatic origin as positive for Glypican 3 (Figure 2). At initial presentation patient didn't have history of abdomen pain or any signs or symptoms of hepatic cirrhosis and was negative for HbsAg and HCV. Then the CT scan of abdomen & pelvis was done, which showed liver cirrhosis with mass in 7th and 8th hepatic segments which was ill defined, lobulated and also enhancing, these features were highly suggestive of HCC. Confirmation was done by

FNAC from liver. Alpha fetoprotein levels was raised to 802 ng/ml and the patient was started on tablet Sorafenib 200 mg.

3. Discussion

Hepatocellular carcinoma is a common malignancy worldwide with highest incidence in East Asian population.⁷ In the review by Pires et al most of the cases had the initial presentation as growth in the mandible which was also seen in our case. 71 patients reviewed, mean age was 62 ± 12 , commonly occurring in males. Most common site in oral cavity is mandible followed by gingiva.⁵ The same was seen in our case. In the literature two pathways have been reported leading to metastasis of liver cancer to oral cavity. The first pathway is through hematogenous route in which tumour reaches circulation by invasion of hepatic artery or portal venous branches.⁸ It is a common route to metastasis to lungs and then to oral cavity. Another mechanism of metastasis is via Batson's plexus that is a paravertebral venous anastomosis which in turn forms a bypass of inferior caval, pulmonary and portal venous circulation.^{9,10} This mechanism is the common way for bony metastasis without involving lungs and is also likely in our case. The mandibular posterior part and RMT area are common for distant metastasis to oral cavity because of high vascularity and also the blood flow slows down here and allows metastatic cells to deposit.¹⁰ Though prognosis of patients with HCC has improved recently but with distant metastasis it is unsatisfactory. Usually the patients with the distant metastasis of oral cavity die within 2 years of diagnosis.⁵ Our patient is still under treatment and on regular follow up.

4. Conclusion

This case report describes a unique presentation of a metastatic lesion of HCC to oral cavity. Although metastasis to oral cavity is rare, it should be kept in mind as one of the differential diagnoses especially among patients with positive hepatitis serology. A detailed history regarding liver diseases and about bleeding tendency of the lesion must be elicited, to ensure accurate diagnosis and prompt treatment while assuring an improved quality of life for the patients.

5. Source of Funding

Nil.

6. Conflicts of Interest

The authors declare no conflicts of interest.


References

- Hirshberg A, Leibovich P, Buchner A. Metastases to the oral mucosa: analysis of 157 cases. *J Oral Pathol Med.* 1993;22(9):385–90.


2. Meyer I, Shklar G. Malignant tumors metastatic to mouth and jaws. *Oral Surg Oral Med Oral Pathol.* 1965;20:350–62.
3. Hirshberg A, Buchner A. Metastatic tumours to the oral region. An overview. *Eur J Cancer B Oral Oncol.* 1995;31B(6):355–60.
4. Chin A, Liang TS, Borislow AJ. Initial presentation of hepatocellular carcinoma as a mandibular mass: case report and review of the literature. *Oral Surg Oral Med Oral Pathol Oral Radiol Endod.* 1998;86(4):457–60.
5. Pires FR, Sagarra R, Corrêa ME, Pereira CM, Vargas PA, Lopes MA. Oral metastasis of a hepatocellular carcinoma. *Oral Surg Oral Med Oral Pathol Oral Radiol Endod.* 2004;97(3):359–68.
6. Dick A, Mead SG, Mensh M, Schatten WE. Primary hepatoma with metastasis to the mandible. *Am J Surg.* 1957;94(6):846–50.
7. Yoshimura Y, Matsuda S, Naitoh SI. Hepatocellular carcinoma metastatic to the mandibular ramus and condyle: report of a case and review of the literature. *J Oral Maxillofac Surg.* 1997;55(3):297–306.
8. Batson OV. The function of the vertebral veins and their role in the spread of metastases. *Ann Surg.* 1940;112(1):138.
9. Waal R, Buter J, Waal IVD. Oral metastases: report of 24 cases. *Br J Oral Maxillofac Surg.* 2003;41(1):3–6.
10. Alison MR, Lovell MJ. Liver cancer: the role of stem cells. *Cell Prolif.* 2005;38(6):407–21.

Author biography

Mahesh Kalloli, Associate Professor  <https://orcid.org/0000-0002-3591-5863>

Ankit Gupta, Fellow  <https://orcid.org/0000-0002-7711-6488>

Rashmi S Patil, Senior Resident  <https://orcid.org/0000-0002-1503-5201>

Chenchulakshmi Vasudevan, Resident  <https://orcid.org/0000-0002-8127-9706>

Sanjiti Madan, Resident  <https://orcid.org/0000-0001-5526-6357>

Cite this article: Kalloli M, Gupta A, Patil RS, Vasudevan C, Madan S. A unique case of HCC presenting as oral cancer. *Indian J Pathol Oncol* 2022;9(3):271-273.