

Content available at: <https://www.ipinnovative.com/open-access-journals>

Indian Journal of Pathology and Oncology

Journal homepage: www.ijpo.co.in

Case Report

Unusual presentation of calcinosis cutis: A diagnostic dilemma

Pooja Jain^{1,*}, Shalini Trivedi¹, Udita Singhal¹, Rohit Kumar²

¹Dept. of Pathology, ESIC Hospital & Dental College, New Delhi, India

²Dept. of Biochemistry, Sanjay Gandhi Memorial Hospital, GNCT, New Delhi, India



ARTICLE INFO

Article history:

Received 22-04-2022

Accepted 04-05-2022

Available online 28-05-2022

Keywords:

Calcinosis cutis

Scrotum

Unusual

Dystrophic calcification

Eyelid

calcium

ABSTRACT

Calcinosis cutis is a rare disorder with abnormal deposition of insoluble amorphous calcium salts under the epidermis in various parts of the body. This syndrome is divided into four types. Here we described two cases of calcinosis cutis at rare sites which were misdiagnosed clinically. In the first case, a 12 years old male child presented with a grey-white nodule in the left upper eyelid, and in the second case, 27 years old man presented with solitary growth on his left scrotum. In both cases, the Provisional diagnosis was misleading. On histopathological examination, a confirmatory diagnosis of Calcinosis cutis was made.

This is an Open Access (OA) journal, and articles are distributed under the terms of the [Creative Commons Attribution-NonCommercial-ShareAlike 4.0 License](https://creativecommons.org/licenses/by-nc-sa/4.0/), which allows others to remix, tweak, and build upon the work non-commercially, as long as appropriate credit is given and the new creations are licensed under the identical terms.

For reprints contact: reprint@ipinnovative.com

1. Introduction

Calcinosis cutis is a rare disorder first described by Virchow in 1855 characterized by abnormal deposition of insoluble amorphous calcium salts under the epidermis in various parts of the body.¹ This syndrome is described into four types: dystrophic calcification, metastatic calcification, idiopathic calcification, and iatrogenic calcification.² The dystrophic type presents in damaged and devitalized tissue. Patients usually had Hyperthyroidism along with calcium and phosphate metabolism disturbance.² Here we described two cases of calcinosis cutis at rare sites.

2. Case 1

A 12-year-old male child presented in the eye department of our hospital with a chief complaint of a grayish mass on the lateral aspect of the left upper eyelid for one year. He gave a history of trauma one and a half years back with a pencil tip while playing. It was neglected & no major treatment was taken at that time.

On physical examination, no other masses were found in any other part of his body. On ocular examination, visual acuity was normal in both eyes. In the left eye, a grayish pigmentation was noted just below the eyebrow of around 6 mm which is not associated with any signs of redness. On palpation, a firm consistency was felt. The mass was non-tender and non-pulsatile. The rest of the examination of the eye was within normal limits. Based on history and Physical examination, a provisional diagnosis of the post-traumatic retained foreign body left upper eyelid was made. Serum calcium-phosphorus and other routine laboratory investigations were within normal limits.

Excision of the nodule was done under local anesthesia. The nodule was removed in-to. It was 8 mm in size (Figure 1). The mass was sent for histopathological examination. Histopathological findings showed the stratified squamous epithelium with underlying dermis showed a large area of calcification. The area was surrounded by fibrous tissue and a few chronic inflammatory cells. All these features were suggestive of calcinosis cutis (Figure 2). On follow up no recurrence was noted and the child has normal visual acuity.

* Corresponding author.

E-mail address: drpoojajain83@gmail.com (P. Jain).

3. Case 2

A 27-year-old man presented in surgical OPD with a complaint of solitary growth of 3X3X1 cm on his left scrotum for 3-4 years, with the complaint of irritation and heaviness. History of manipulation of the swelling was also present. There was no history of itching, burning sensation, ulceration, or discharge. The swelling did not interfere with urination or sexual activities. The growth started as a small lesion on the right side of the scrotum but was increasing in size. There is neither history of any systemic illness nor any family history.

On physical examination, a solitary lesion of about 3 × 3 × 1 cm involving the scrotum was noticed. The skin surrounding the nodules, testis, and penis was normal on palpation. The swelling was painless and firm inconsistently. On laboratory examinations, the following were found to be within normal limits: serum calcium, phosphorus, parathyroid hormone, and vitamin D hormone levels; uric acid; alkaline phosphatase; and lipid profile. Based on clinical features and physical examination, a diagnosis of sebaceous cyst of the scrotum was made. The swelling was excised under local anesthesia. His postoperative period was unremarkable and no evidence of recurrence during a six-month follow-up period. The cut section of nodular swelling showed solid white to bluish homogenous areas. Histopathological examination shows skin tissue lined by keratinized stratified squamous epithelium. The underlying dermis had granules and globules of basophilic calcified material along with foreign body giant cell reaction to calcium showing numerous histiocytes and multinucleated giant cell areas of fibrosis and calcification (Figure 3 a,b)

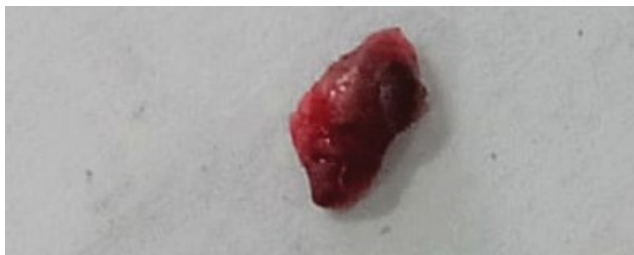

Fig. 1: Nodule removed in-toto (8 mm in size)

4. Discussion

As per our knowledge, this case report is one of the few case reports of Calcinosis cutis published in the literature. Samara et al,³ reported a case of idiopathic calcinosis cutis in the upper eyelid. Malik et al⁴ reported a case with idiopathic bilateral subepidermal calcific nodules in both eyelids. In idiopathic form, it may mimic molluscum⁵ or solitary verrucae nodule.⁶ Idiopathic calcinosis cutis of the tarsus of the upper eyelid in a patient

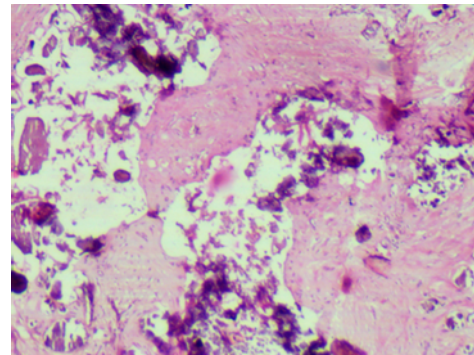


Fig. 2: Granules and globules of basophilic calcified material

with Rheumatoid arthritis with normal serum calcium levels has been reported.⁷ It has been seen to have an association with disorders like dermatomyositis, systemic lupus erythematosus, or systemic sclerosis.⁸ Eyelid, palpebral and bulbar calcifications also have been noted in patients with inflammation, systemic hyperparathyroidism, and hyperphosphatemia.^{9,10} In our case serum calcium and phosphate levels were within normal limits and no other cause could be found except a clearly defined history of trauma at that exact point. Investigations should be done to exclude any underlying pathology, especially in idiopathic cases. No standard treatment has been recommended for the removal or reduction of the lesion of calcinosis cutis.^{8,11} Colchicine, warfarin, bisphosphonates, probenecid, and diltiazem have been used with varying degrees of success.¹¹ Surgical excision is the treatment of choice.⁷

Though there have been reports on idiopathic calcinosis cutis of the scrotum. ICCS is a benign, mostly asymptomatic, condition, however, it appears early, patients generally present during the second to third decade of life. Delayed presentation is due to the absence of any symptoms for long period. The disease presents as slow-growing yellowish nodules in the scrotum, single to multiple in numbers, with varying sizes. Lewinski et al. were the first to describe that Calcinosis Cutis may be associated with itching or may rupture with the discharge of chalky material.¹² The first review was provided by Shapiro et al.¹³ Lewinski¹² is also credited with the introduction of the term idiopathic calcinosis of the scrotum. The clinical features of a few case series with five or more cases reported until now are compared in Table 1.

ICCS is a clinical and histological diagnosis. The confirmation is always done by histopathology. A nodular lesion in the scrotum has several differential diagnoses which include steatocystoma multiforme, angiokeratoma, lipomata, fibromata, and lymphangioma circumscriptum.¹⁵ Calcified sebaceous cyst would make a difficult differential clinically. To label the condition as idiopathic, the presence of calcification elsewhere must be ruled out. A thorough biochemical and hormonal profile would help delineate the

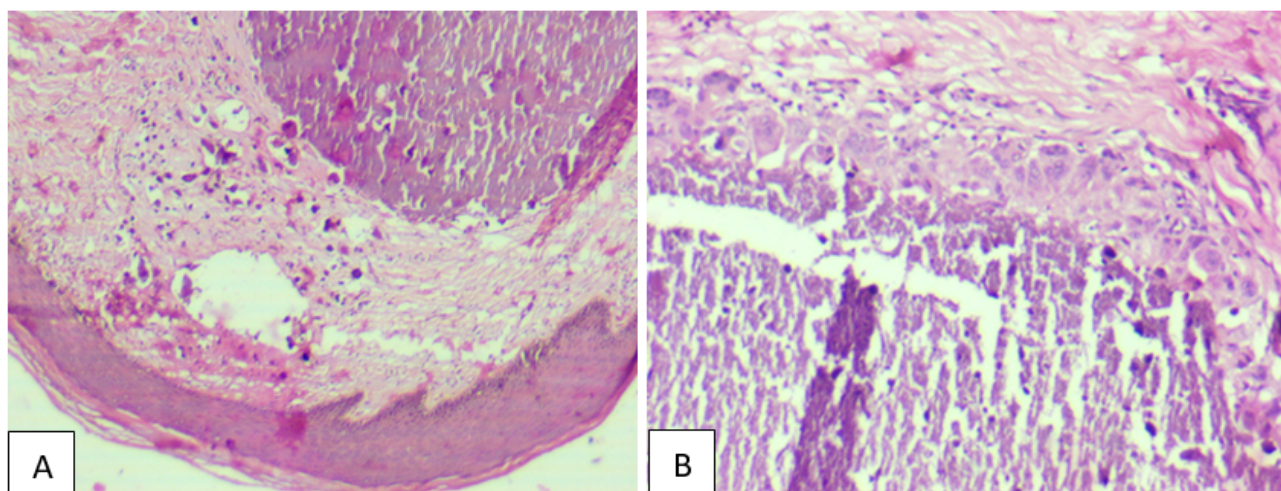


Fig. 3: Skin tissue lined by keratinized stratified squamous epithelium; **a:** The underlying dermis had granules and globules of basophilic calcified material (**a,b**) along with foreign body giant cell reaction to calcium showing numerous histiocytes and multinucleated giant cell, areas of fibrosis, and calcification All these features are suggestive of calcinosis cutis

Table 1: Clinical features of idiopathic calcinosis cutis of the scrotum from various case reports

Authors	Shapiro et al. ¹³	Akosa et al. ¹⁴	Gormally et al. ¹⁵	Angola et al. ¹⁶
No. of cases	13	5	11	20
Mean age of presentation	47.3	39.6	27	37
No. of nodules	variable	1 to 36	4-10 (two cases)	variable
Size range of nodules	1 mm to 3 cm	Not stated	Up to 2 cm (2 cases)	0.5 to 3.5 cm
Clinical Symptoms	Itching (5/13) Asymptomatic (2/13) discharge (4/13)	Asymptomatic (4/5) Discharge (1/5)	Itching & discharge (1/2) Asymptomatic (1/2)	Asymptomatic (16/20) discharge (4/20)
Hyperparathyroidism	Present	absent	present	present
Provisional Diagnosis	Sebaceous cyst (8/13) Cyst (1/13) Not mentioned (3/13)	Sebaceous cyst	Not mentioned	Sebaceous cyst
Calcification in other body areas	absent	absent	absent	absent

cause. If the condition is truly idiopathic, the laboratory investigations unequivocally fall within normal limits. Not one particular diagnostic modality is helpful. Fine-needle aspiration cytology, ultrasonography, and X-ray have been ordered with limited usefulness.¹⁶ As the condition is benign and mostly asymptomatic, the treatment is for aesthetic purposes, unless the nodules start discharging or become itchy. Excision followed by scrotal reconstruction is the treatment of choice. It leaves a good cosmetic result with low chances of recurrence. Even the smallest nodule must be removed to prevent a recurrence.

5. Conclusion

This is one of the very few case reports of post-traumatic calcinosis cutis affecting the eyelid which is a rare site for involvement. ICCS is a benign condition, which remains

mostly asymptomatic. It presents as progressive multiple nodules of varying numbers and sizes. At both sites, a histopathological evaluation reveals areas of calcification. The cause is either dystrophic calcification of cysts or idiopathic. Excision is the treatment of choice.

6. Source of Funding

None.

7. Conflict of Interest

The authors declare no conflict of interest.

References

- Reiter N, El-Shabrawi L, Leinweber B, Berghold A, Aberer E. Calcinosis cutis: Part I. Diagnostic pathway. *J Am Acad Dermatol.* 2011;65(1):1–12.

2. Valenzuela A, Chung L. Calcinosis: pathophysiology and management. *Curr Opin Rheumatol*. 2015;27(6):542–8.
3. Samaka RM, Al-Madhani A, Hussian SO, Oman J Ophthalmol. Subepidermal calcified nodule in upper eyelid: A case report and review of the literature. *Oman J Ophthalmol*. 2015;8(1):56–8.
4. Malki SA, Al-Faky YH, Al-Rikabib AC. Bilateral subepidermal calcified nodules of the eyelid. *Saudi J Ophthalmol*. 2011;25(1):81–3.
5. Nguyen J, Jakobiec FA, Hanna E, Aaron F. Subepidermal calcified nodules of the eyelid. *Ophthalmic Plast Reconstr Surg*. 2008;24(6):494–5.
6. Nico MM, Bergonesi FN. Subepidermal calcified nodule: report of two cases and review of the literature. *Paediatr Dermatol*. 2001;18(3):227–9.
7. Jun I, Kim SE, Lee SY, Kim GJ, Yoon JS. Calcinosis Cutis at the Tarsus of the Upper Eyelid. *Korean J Ophthalmol*. 2011;25(6):440–2.
8. Boulman N, Slobodin G, Rozenbaum M. Calcinosis in rheumatic diseases. *Semin Arthritis Rheum*. 2005;34(6):805–12.
9. Ferry AP. Subepidermal calcified nodules of the eyelid. *Am J Ophthalmol*. 1990;109(1):85–8.
10. Ghanchi F, Ramsay A, Coupland S, Coupland S, Barr D, Lee WR. Ocular tumoral calcinosis. A clinicopathologic study. *Arch Ophthalmol*. 1996;114(3):341–5.
11. Dutz J. Treatment options for the cutaneous manifestations of systemic sclerosis. *Skin Therapy Lett*. 2000;6(1):3–5.
12. Lewinski HM. Lymphangiome der Haut mit Verkalkem Inhalt. *Arch Pathol Anat*. 1883;91:371–5.
13. Shapiro L, Platt N, Torres-Rodriguez VM. Idiopathic calcinosis of the scrotum. *Arch Dermatol*. 1970;102(2):199–204.
14. Akosa AB, Gilliland EA, Ali MH, Khoo CT. Idiopathic scrotal calcinosis: a possible etiology reaffirmed. *Br J Plast Surg*. 1989;42(3):324–7.
15. Gormally S, Dorman T, Powell FC. Calcinosis of the scrotum. *Int J Dermatol*. 1992;31(2):75–9.
16. Andola S, Tandon T, Patil A. Clinical-epidemiological, the cytological and histopathological study of idiopathic calcinosis cutis of the scrotum. *J Clin Diagn Res*. 2017;11(11):EC01–4.

Author biography

Pooja Jain, Chief Medical Officer  <https://orcid.org/0000-0002-4635-0132>

Shalini Trivedi, Specialist and HOD

Udita Singhal, Associate Professor

Rohit Kumar, Medical Officer

Cite this article: Jain P, Trivedi S, Singhal U, Kumar R. Unusual presentation of calcinosis cutis: A diagnostic dilemma. *Indian J Pathol Oncol* 2022;9(2):169-172.