



Case Report

Benign collision tumour of the parotid gland – A rare case report

Ronald Anto¹, Suresh Mani^{1*}, Amey Baitule², Rajiv C Michael¹

¹Dept. of Head and Neck Surgery, Christian Medical College, Vellore, Tamil Nadu, India

²Dept. of Pathology, Christian Medical College, Vellore, Tamil Nadu, India



ARTICLE INFO

Article history:

Received 15-03-2022

Accepted 25-03-2022

Available online 28-05-2022

Keywords:

Collision tumor

Pleomorphic adenoma

Warthin's tumor

Parotid gland

ABSTRACT

Diagnostic pathology in parotid gland (PG) is extremely versatile, due to the diversity, aetiology and histogenesis of PG tumors. Synchronous tumors (either hybrid or collision) are described as two or more distinct neoplasms arising in the same anatomical location, either malignant or benign. We present a case of parotid swelling diagnosed to be Warthin's tumor (WT) preoperatively which turned out to be a Pleomorphic adenoma – Warthin's collision tumor. This rare type of collision tumor, was managed successfully by surgery with close follow-up. We aim to enlighten surgeons and pathologists about this rare condition to make them familiar about the difficulties in diagnosis and management of the tumor.

This is an Open Access (OA) journal, and articles are distributed under the terms of the [Creative Commons Attribution-NonCommercial-ShareAlike 4.0 License](https://creativecommons.org/licenses/by-nc-sa/4.0/), which allows others to remix, tweak, and build upon the work non-commercially, as long as appropriate credit is given and the new creations are licensed under the identical terms.

For reprints contact: reprint@ipinnovative.com

1. Introduction

Parotid gland (PG) neoplasms constitute only 3% of head and neck tumors and of that synchronous unilateral multiple neoplasms are even more rare and constitute only 0.5% of all PG tumors.¹ Collision tumors represent neoplasms that arise in different locations to coalesce in a specific area whereas hybrid tumors constitute different tumors in a single neoplasm within the same terrain.² To add, no definite acceptable hypotheses for the occurrence of these rare synchronous collision tumors in the same gland have been postulated which makes pathological diagnosis of these unique neoplasms challenging.³ In the present study, we report a collision tumor of two benign neoplasms, which is a unique challenging pathological entity.

2. Case Report

A 44-year-old hypertensive and diabetic gentle man, and a known smoker for past 20 years, came with the complaints

of gradually progressive swelling below right ear for 5 years with no other associated complaints. His facial nerve function was normal. On examination, a 4x5 cm firm to hard, mobile, non-tender swelling was noted just below the right ear lobule in the parotid region.

He had non-contrast computed tomography (CT) films done elsewhere which showed a well-circumscribed single lobulated lesion with a cystic component confined to the superficial lobe of right PG (Figure 1). Preoperative diagnosis of WT was made in FNAC since oncocytic cells and lymphocytes were noted. He underwent a superficial parotidectomy after an informed written consent. Intra operatively, a 3x4cm cystic lesion was noted in the superficial lobe of the right PG. The tumor was excised completely without any spillage and preserving all branches of the facial nerve.

Postoperative gross histopathological examination revealed bosselated, greenish myxoid cut surface with intervening foci of yellowish-white islands with no necrosis. On microscopy, a circumscribed, encapsulated tumor composed of an intimate admixture of epithelial, myoepithelial, myxoid and fibromyxoid stroma and nests

* Corresponding author.

E-mail address: msuresh.doc@gmail.com (S. Mani).

and islands of bland cells. The epithelial component was arranged in strands, anastomosing cords and tubules by an inner cuboidal epithelial cell and an outer layer of myoepithelial cells which blended into the adjacent chondromyxoid stroma (Figure 2 A). There were large areas of cystic degeneration, cholesterol clefts and foreign body giant cell reaction with cyst lined by bilayer oncocytic epithelium, inspissated secretions and scanty lymphoid stroma (Figure 2 B). In other sections, a layer of cuboidal lined the cystic spaces with attenuated oncocytic cells underneath, which were huge aggregates and sheets of lymphoid stroma. Mitotic activity was inconspicuous no evidence of malignancy was noted in the sections analysed. Thus, with the combined picture of benign salivary gland tumor with features of both PA and WT, a diagnosis of Collision tumor is made. Patient was monitored with close followup and no recurrence was noted after 2 years.

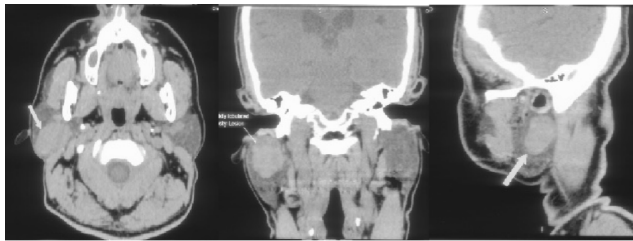


Fig. 1: Pre-operative non-contrast CT showing a well-circumscribed single lobulated lesion with cystic component confined to the superficial lobe of right parotid gland. (white arrow) (Axial, coronal and sagittal views in order)

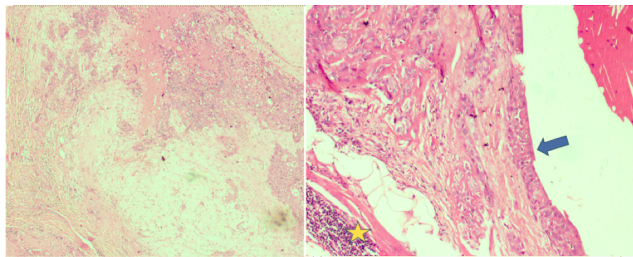


Fig. 2: Histopathological pictures of **A:** Pleomorphic adenoma, with myxoid and fibromyxoid stroma and nests and islands of bland cells. **B:** Warthin's tumour, with cyst lined by bilayered oncocytic epithelium (blue arrow), inspissated secretions and scanty lymphoid stroma (yellow star)

3. Discussion

Collision neoplasms are postulated to be coalescence of two separate pathologically distinctive tumors at a certain locale.⁴ The cause for occurrence of these rare tumors is not clearly defined. It is postulated that, in the initial stages, the two tumors would have existed as two separate, non-colliding tumors, and in the course of time, the

two components would have invaded each other.⁵ Costa proposed three hypotheses for the existence of collision tumors. First hypothesis is that, a carcinogen would cause two different neoplasms in two adjacent histologically distinct tissues. The second hypothesis is the possibility of horizontal recruitment, in which carcinomas, composed of host cells, are induced at the site of transplantation of a malignant neoplasm. The final proposal is the conductive mechanism where a long-standing tumor creates an environment that favours the genesis of second tumor at adjacent site.⁵

WTs manifest in older men as slow growing PG mass, bilateral in 10% of cases and also the most common tumor to manifest as multiple lesions and as collision predominantly with other malignant tumors.⁶ In the present study, FNAC revealed oncocytic and lymphocytic cells in a proteinaceous background, and thus a conclusion of WT was arrived. PG tumors especially WT can pose problems in preoperative cytological diagnosis, due to the varied presentation of tumors in cytological analysis.⁷

Our patient had a CT films done elsewhere, an FNAC suggested WT and clinically the lesion was mobile, hence we did not do any further imaging studies. Magnetic resonance imaging (MRI) is the preferred modality of imaging in PG tumors. Small lesions and synchronous tumors that are in close proximity or in collision could not be clearly distinguished even in MRI.² On imaging, small PA appears as well-defined lesion with homogenous enhancement whereas large PA appears lobulated with hemorrhagic and necrotic areas.⁶ WT appears boggy on palpation because of fluid cystic spaces. On CT, a well-circumscribed lesion with associated cystic and hypodense areas.^{2,6,7} In the present case, a single well-circumscribed homogenous swelling was noted in the superficial lobe of the right PG and a clear delineation between the two tumors could not be made out preoperatively.

On reviewing published reports, combination of two benign tumours on unilateral PG is extremely rare.⁸ In benign and malignant combination, WT is the most common type followed by PA on benign side where as Mucoepidermoid carcinoma (MEC) is most common type followed by acinic cell carcinoma on malignant counterpart. The most popular histological combination of neoplasms is WT and MEC.⁹ Other benign tumors, such as sebaceous lymphadenoma and myoepithelioma, and malignant tumors, such as adenocarcinoma, squamous cell carcinoma, carcinoma ex-pleomorphic adenoma and salivary ductal carcinoma, have been reported.^{9,10}

In our case both the tumors were benign. The role of imaging and FNAC is controversial in collision tumors. Clinician should suspect malignancy based on clinical features. An ultrasound guided FNAC from suspicious solid areas of the tumor may help us in diagnosing a malignant tumor combination. The oncological safety of conservative

surgical procedures like adequate parotidectomy and extracapsular excision in collision tumor is controversial.

The role of frozen section in a suspicious malignant tumor needs to be studied prospectively to know the magnitude of the malignant combination. Non-surgical management of WT such as careful observation should be reconsidered where collision tumors are suspected. Although a handful of case reports have been reported on a combination of malignant collision/hybrid tumours, this present report is one of the very few reported cases of combination of benign PG collision tumours. The surgeon should be aware of rare collision tumors of the salivary glands, so that they can be diagnosed preoperatively when there is a clinical suspicion on evaluation. A close follow-up is advocated to monitor the probability of recurrence and early intervention if diagnosed.

4. Source of Funding

None.

5. Conflict of Interest

The authors declare no conflict of interest.

References

- Atay G, Cabbarzade C, Gedikoğlu G, Hoşal A. Hybrid carcinoma of the parotid gland: ductal carcinoma and myoepithelial carcinoma. *Kulak Burun Bogaz İhtis Derg.* 2014;24(1):46–9.
- Horisk N, Stephenson E, Sayers C, Reid J. Incidental finding of synchronous pleomorphic sali-vary adenoma and Warthin's tumour within a parotid gland. *BMJ Case Rep* 2019; 12(4): . 2019;12(4):e228675.
- Curry JL, Petruzzelli GJ, McClatchey KD, Lingen MW. Synchronous benign and malignant salivary gland tumors in ipsilateral glands: a report of two cases and a review of literature. *Head Neck.* 2002;24(3):301–6.
- Takeda Y, Yamamoto H. Oral collision carcinoma: Salivary duct carcinoma of minor salivary gland origin and squamous cell carcinoma of the oral mucosa. *J Oral Sci.* 1999;41(3):129–31.
- Sarbia M, Katoh E, Borchard F. Collision tumor of squamous cell carcinoma and leiomyoma in the esophagus. *Pathol Res Pract.* 1993;189(3):364–2.
- Thoeny HC. Imaging of salivary gland tumours. *Cancer Imaging.* 2007;7(1):52–62.
- Fernandes H, D'souza CRS, Khosla C, George C, Katte L, Katte NH. Role of FNAC in the Preoperative Diagnosis of Salivary Gland Lesions. *J Clin Diagn Res.* 2014;8(9):FC01–3.
- Gnepp DR, Schroeder W, Heffner D. Synchronous tumors arising in a single major salivary gland. *Cancer.* 1989;63(6):1219–24.
- ška AOC, Bruzgielewicz A, Wójcikiewicz EO. Synchronous multiple unilateral parotid gland tumors of benign and malignant histological types: case report and literature review. *Braz J Otorhinolaryngol.* 2019;85(3):388–92.
- Zeebregts CJ, Mastboom WJ, Noort GV. synchronous tumours of the unilateral parotid gland: rare or undetected? *J Craniomaxillofac Surg.* 2003;31:62–68.

Author biography

Ronald Anto, Fellow in Head and Neck Surgery

Suresh Mani, Assistant Professor  <https://orcid.org/0000-0002-0945-1225>

Ameey Baitule, Assistant Professor

Rajiv C Michael, Professor and HOD

Cite this article: Anto R, Mani S, Baitule A, Michael RC. Benign collision tumour of the parotid gland – A rare case report. *Indian J Pathol Oncol* 2022;9(2):153-155.