

Content available at: <https://www.ipinnovative.com/open-access-journals>

Indian Journal of Pathology and Oncology

Journal homepage: www.ijpo.co.in

Case Report

A rare collision tumor of ovary – Mucinous cystadenoma with adult granulosa cell tumor

Neema K^{1,*}, Geetha K¹¹Dept. of Pathology, Government Medical College, Kannur, Kerala, India

ARTICLE INFO

Article history:

Received 19-10-2021

Accepted 14-01-2022

Available online 14-02-2022

Keywords:

Adult granulosa cell tumor

Collision tumor

Mucinous cystadenoma

Ovary

ABSTRACT

Though collision tumors have been reported earlier like serous cystadenoma and mature cystic teratoma, combination of mucinous cystadenoma and adult granulosa cell tumor is rarely reported in the literature. Collision tumors lack the histological cellular intermingling which is seen in composite tumors. Both involve two morphologically and immunohistochemically distinct neoplasms coexisting within a single organ. Mucinous cystadenoma is a benign cystic surface epithelial tumor of ovary. Granulosa cell tumor (GCT) is a low grade malignancy arising from sex cord stromal cells of ovary and need a close follow up for recurrences which may be late. Here we present a case of 50 year old female who presented with lower abdominal pain. Patient underwent staging laparotomy and ovarian specimen sent for histopathological examination, where it was diagnosed as mucinous cystadenoma coexisting with adult granulosa cell tumor. This case report emphasis upon the fact that multiloculated cyst have to be extensively examined grossly, so as not to miss any solid component which might have a bearing on prognosis of the patient. Here the association of mucinous cystadenoma and granulosa cell tumor need close follow up of patient.

This is an Open Access (OA) journal, and articles are distributed under the terms of the [Creative Commons Attribution-NonCommercial-ShareAlike 4.0 License](https://creativecommons.org/licenses/by-nc-sa/4.0/), which allows others to remix, tweak, and build upon the work non-commercially, as long as appropriate credit is given and the new creations are licensed under the identical terms.

For reprints contact: reprint@ipinnovative.com

1. Introduction

Both composite and collision tumors involve two morphologically and immunohistochemically distinct neoplasms coexisting within a single organ, however collision tumors lack the histological cellular intermingling seen in composite tumors. Granulosa cell tumor and mucinous cystadenoma are independent tumor arising from sex cord stromal cells and surface epithelium of ovary. Here we present a case of 50 year old lady presenting with a complex cystic ovarian mass which is diagnosed as collision tumor of ovary (mucinous cystadenoma with adult granulosa cell tumor).

2. Case Presentation

50 year old female presented with lower abdominal pain since 5 months. On per abdomen examination 20 weeks size gravid uterine size, mass was felt which is hard in consistency, motility restricted. On per speculum examination cervix appears normal. Per vaginal examination showed hard mass felt through anterior fornices. USG abdomen and pelvis showed a large right adnexal cyst with septations, 13x10cm with internal echoes, vascular flow seen in wall s/o complex ovarian cystic mass. CA125-16.3. staging laparotomy was done which showed right ovarian mass. Left ovary and uterus normal. Diagnosis was confirmed by histopathological examination of cystic mass. Grossly (Figure 1) right ovary enlarged to 15x10cm, multiloculated with clear fluid, capsule intact. Solid areas seen in the cystic cavity. Microscopy showed

* Corresponding author.

E-mail address: neemajithin1993@gmail.com (Neema K).

multiple cystic spaces of varying sizes separated by fibrous stroma. Cyst are lined by mucin filled tall columnar epithelium with basal nuclei. Solid area is composed of predominantly small cells arranged as sheets, thin cords. Cells show eosinophilic cytoplasm, small round to oval nuclei many of which show nuclear grooving.

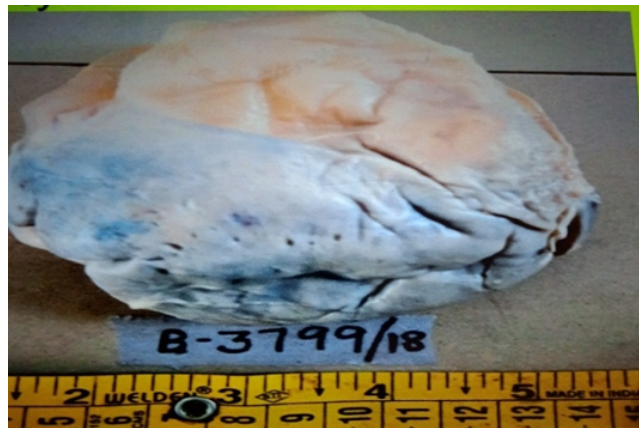

Fig. 1: Ovary enlarged with cut section showing multiloculated cyst with solid areas

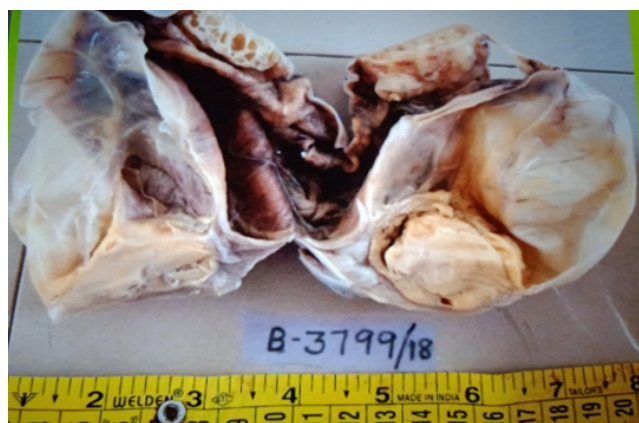

Fig. 2: Ovary enlarged with cut section showing multiloculated cyst with solid areas

3. Discussion

Collision tumors lack the histological cellular intermingling that seen in composite tumors. granulosa cell tumor and mucinous cystadenoma are independent tumor arising from sex cord stromal cells and surface epithelium of ovary.¹ Little is known about the molecular and genetic changes that give rise to GCT (granulosa cell tumor). approximately 97% of adult GCT harbour a somatic missense mutation in the FOXL2 gene (which is absent in Juvenile GCT) represents an exciting advancement in molecular pathways of GCT.² The deficiency of DNA mismatch repair also contributes to

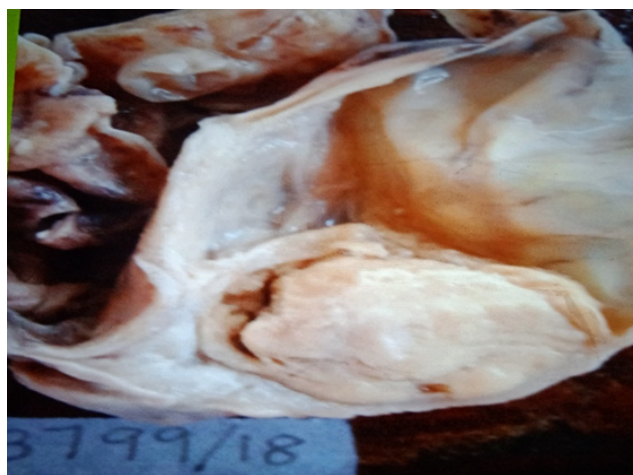

Fig. 3: Shows a well circumscribed yellowish solid lesion within the cyst

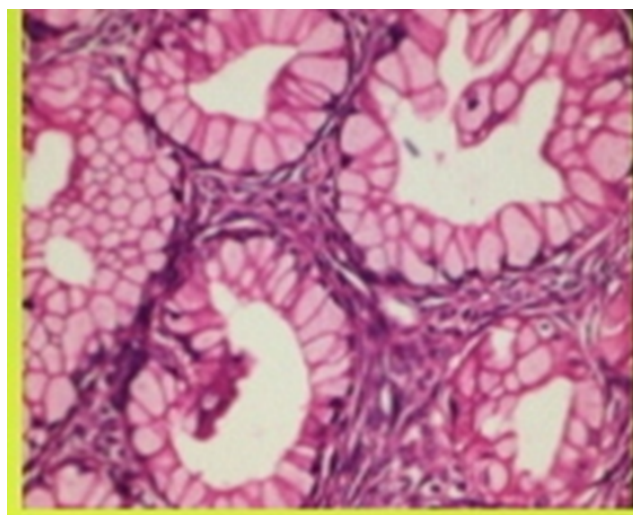


Fig. 4: Microscopy of cystic area showing cystic spaces lined by mucinous epithelium with basal nuclei

the pathogenesis of GCT. Occasionally GCT presents as a small lesion in cystic teratoma which could easily be missed through inadequate sections, so ovaries with mature cystic teratoma should be examined thoroughly for small foci of GCT.³

Mucinous cystadenoma is a benign cystic tumor lined by mucinous gastrointestinal /endocervical epithelium (Figure 4). It usually presents as a multiloculated cystic mass with mucinous secretions. Adult granulosa cell tumor (AGCT) accounts for 1-2% of all ovarian neoplasm and they are known for late recurrences.⁴ microscopically a variety of growth patterns occur, most common pattern is diffuse in which tumor cells grow in sheets (Figure 5). Tumor cells often grow in cords, trabeculae, ribbon, gyriform, nests. A microfollicular pattern (call exner bodies) in which granulosa cells surround small spaces containing

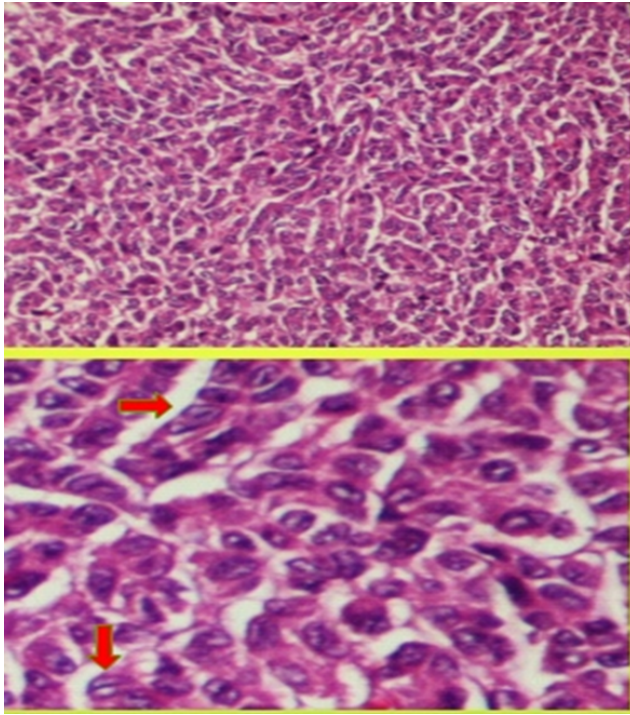


Fig. 5: Microscopy of solid area showing cells arranged in sheets, cords. Cells show eosinophilic cytoplasm, nuclear grooving

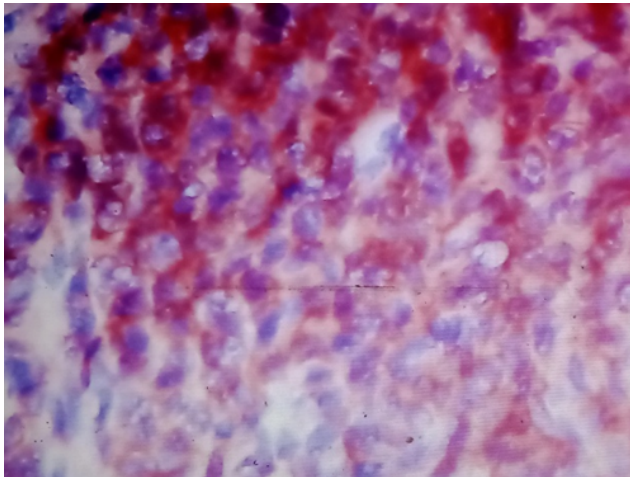


Fig. 6: IHC-CD 56 positivity in granulosa cell tumor

eosinophilic secretions. occasionally large follicles (macro follicular pattern) can be seen. Immunohistochemically, GCT usually exhibit inhibin, calretinin, CD56 (Figure 6),

WT1 positivity.⁵ Collision tumors show histological features of cellular intermingling which is not seen in composite tumors.⁶ In the present case, solid foci showed the features of GCT. GCT tumors are characterised by very indolent course and late recurrences. Hence, this association need close follow up of the patient.

4. Conclusion

In our case report the patient was a 50-year-old lady presenting with lower abdominal pain and imaging showed a large right adnexal mass. This case report is to emphasize upon the fact that multiloculated cyst have to be extensively examined grossly so as not to miss any solid component which might have a bearing on prognosis of the patient.

5. Source of Funding

None.

6. Conflict of Interest

None.

References

1. Bhavani M, Ranjan S. A histopathological study on dual tumors of ovary. *J Dent Med Sci.* 2017;16(12):29-31.
2. Shah SP, Köbel M, Senz J, Morin RD, Clarke BA, Wiegand KC, et al. mutation of FOXL2 in granulosa cell tumors of ovary. *N Engl J Med.* 2009;360(26):2719-29.
3. Subrahmanya NB, Kapadi SN, Junaid TA. Mucinous cystadenoma coexisting with adult granulosa cell tumor in the ovary: is it a composite tumor or heterologous mucinous elements in a granulosa cell tumor? *Int J Gynecol Pathol.* 2011;30(4):386-90.
4. Fletcher CDM. Diagnostic histopathology of tumors. 4th ed. Philadelphia: Elsevier Saunders; 2013.
5. Rosai J. Rosai and Ackerman's Surgical Pathology. 10th ed. India: Elsevier; 2012.
6. Kushida Y, Haba R, Kadota K, Doi T, Ishikawa M, Hirakawa E, et al. Composite mucinous and granulosa cell tumor of ovary. *Pathol Int.* 2005;55(12):797-801.

Author biography

Neema K, Junior Resident  <https://orcid.org/0000-0003-4108-9577>

Geetha K, Professor and HOD

Cite this article: Neema K, Geetha K. A rare collision tumor of ovary – Mucinous cystadenoma with adult granulosa cell tumor. *Indian J Pathol Oncol* 2022;9(1):68-70.