



Content available at: <https://www.ipinnovative.com/open-access-journals>

Indian Journal of Pathology and Oncology

Journal homepage: [www.ijpo.co.in](http://www.ijpo.co.in)



## Original Research Article

# Clinicopathological correlation of p53 expression in benign prostatic hyperplasia and prostate adenocarcinoma

Ganraj Bhat<sup>1</sup>, Mohammed Afroz Ahamed<sup>2</sup>, Neha Saroha<sup>3,\*</sup>, Greeshma Prasad<sup>1</sup>

<sup>1</sup>Dept. of Pathology, M.S. Ramaiah Hospital, Bangalore, Karnataka, India

<sup>2</sup>Dept. of Pathology, District Hospital, Chikmagalur, Karnataka, India

<sup>3</sup>Dept. of Pathology, Mysore Medical College and Research Institute, Mysore, Karnataka, India



## ARTICLE INFO

### Article history:

Received 26-09-2021

Accepted 29-10-2021

Available online 14-02-2022

### Keywords:

p53

Prostate adenocarcinoma

Benign prostatic hyperplasia

## ABSTRACT

**Introduction:** Prostate adenocarcinoma is the 6<sup>th</sup> most common carcinoma in men worldwide. It is usually a cancer of the elderly age group. Benign prostatic hyperplasia is a common cause of urinary incontinence and urine flow symptoms, usually seen in the middle along with elderly age group. In this study we have evaluated the expression of p53 immunohistochemistry (IHC) in prostate adenocarcinoma with benign prostatic hyperplasia along with its diagnostic, treatment and prognostic implications.

**Objectives:** 1. Assessment of clinical and biochemical parameters in patients with benign prostatic hyperplasia (BPH) and prostate adenocarcinoma. 2. To assess p53(IHC) expression in benign prostatic hyperplasia and prostate adenocarcinoma

**Materials and Methods:** The study population comprised of a subset of patients who came to Ramaiah hospital, Bangalore from May 2018 till June 2019, for treatment regarding prostate related symptoms. The clinicodemographic data was collected and prostate biopsies were taken for which histopathological assessment was done. A total of 60 cases comprising of 30 cases of BPH and 30 cases of prostatic adenocarcinoma was subjected to p53 immunohistochemistry. The results were tabulated and statistically analyzed for significance.

**Results:** The present prospective study was conducted on 60 patients with 30 cases (50%) of BPH and 30 cases (50%) of prostatic adenocarcinoma. Based on the tumor differentiation there was 1 case (3.3%) of well differentiated carcinoma, 18 cases(60%) of moderately differentiated carcinoma and 11cases (36.6%) of poorly differentiated carcinomas. We observed an inverse relationship between p53 expression and histological grade. All poorly differentiated carcinoma had higher p53(>50% expression). There was statistically significant difference in expression of p53 between cases of BPH and carcinoma prostate, indicated by P value of <0.05. Among prostate carcinomas p53 had higher expression on those cases with Gleason score 9 and 10.

**Conclusions:** P53 expression directly correlates with Gleason score, while inversely correlating with tumor differentiation of prostate carcinoma cases. The expression of p53 is low in BPH as compared to that of prostate cancers. Hence it can be used as a good diagnostic and prognostic marker in prostate carcinoma.

This is an Open Access (OA) journal, and articles are distributed under the terms of the [Creative Commons Attribution-NonCommercial-ShareAlike 4.0 License](https://creativecommons.org/licenses/by-nc-sa/4.0/), which allows others to remix, tweak, and build upon the work non-commercially, as long as appropriate credit is given and the new creations are licensed under the identical terms.

For reprints contact: [reprint@ipinnovative.com](mailto:reprint@ipinnovative.com)

## 1. Introduction

The p53 tumor suppressor gene is found to be one of the most frequently mutated genes in all human cancers. p53 protein is involved in a myriad of functions crucial to normal cell proliferation, apoptosis, and DNA

\* Corresponding author.

E-mail address: [nehasaroha891@gmail.com](mailto:nehasaroha891@gmail.com) (N. Saroha).

repair.<sup>1,2</sup> Numerous studies<sup>3–11</sup> have been published concerning p53 gene mutation and prostate cancer. Previous studies have shown a low rate of mutation in early stages and association with advanced disease. Many analyses have used immunohistochemistry (IHC) to evaluate p53 gene status. In tumors with p53 mutations, metabolism of p53 protein is abnormal which accumulates in the nucleus and thus allowing its detection. However, positive immunohistochemical detection does not necessarily indicate the presence of a mutation, since the protein can accumulate for other reasons, such as abnormalities in other genes involved in p53 regulation and metabolism.<sup>12</sup> Finally, not all tumors with p53 mutations will have detectable protein; for example, some insertion or deletion mutations could result in a truncated protein not containing the antigenic site recognized by the specific antibody being used.<sup>13,14</sup>

The present study was conducted to find the difference in expression of p53 IHC in BPH and prostate adenocarcinoma.

## 2. Aims and Objectives

1. Assessment of clinical and biochemical parameters in patients with benign prostatic hyperplasia (BPH) and prostate adenocarcinoma.
2. To assess p53 (IHC expression in benign prostatic hyperplasia and prostate adenocarcinoma.

## 3. Materials and Methods

A total of 60 prostate samples received in the histopathology laboratory at M S Ramaiah Hospital from May 2018 to June 2020 were studied. Prostatic trucut biopsies, transurethral prostatic resection (TURP) chips and radical prostatectomy specimens from patients of all ages with benign prostatic hypertrophy or prostatic adenocarcinoma were included in the study. Cases where there was extensive tumour necrosis without sufficient viable tumour for accurate evaluation of the histopathological features for p53 were excluded from the study. The subset taken for the study included 30 benign prostatic hypertrophy and 30 prostatic adenocarcinoma cases.

Pre-treatment serum prostate-specific antigen (PSA) determinations were available for all 60 (100%) patients considered in this study. The detailed clinical history and results of relevant investigations were collected from the patient case files. The trucut biopsies, transurethral prostatic resection (TURP) and prostatectomy specimens were received in the Pathology Department in 10% formalin. In every case the standard protocol for surgical grossing of prostate specimens was followed. After a detailed specimen description, in case of radical prostatectomies, multiple sections were taken from the tumour, surgical margins, seminal vesicles and lymph nodes. After conventional

processing and embedding in paraffin wax, sections of 5µm thickness were cut and stained using haematoxylin and eosin (H&E) for histopathological study. These H&E stained slides were studied for the tumour histology, Gleason grade, and other features as per the standard reporting protocol. In addition, 4µm sections were cut from a paraffin block of tumour tissue and taken on a glass slide coated with adhesive poly-L-lysine for immunohistochemistry (IHC) to evaluate p53 expression.

The technique for IHC included antigen retrieval in citrate buffer in a microwave oven, blocking endogenous peroxidase with 3% hydrogen peroxide, incubating with primary mouse monoclonal antibody against p53 protein (Biogenex), linking with rabbit anti mouse secondary antibody (Biogenex), enzyme labelling with streptavidin-horseradish peroxidase, developing chromogen with deaminobenzidine (DAB) and counterstaining with haematoxylin. Positive and negative controls were run with each batch of slides.

For inclusion in the study, the stained section had to contain identifiable carcinoma or benign prostatic hypertrophy. Sections were evaluated without knowledge of patient outcome. Only nuclear immunoreactivity was considered to represent positive staining. Immunohistochemical staining was scored semi-quantitatively as follows: 0 = was assigned when no staining was observed, 1 = when less than 10% of tumor cell nuclei were reactive, 2 = when more than 10%, but less than 33% of the nuclei stained, and 3 – if more than 33% of the nuclei were stained.

The p53 expression was correlated with the age, PSA levels, Gleason score, histological grade.

### 3.1. Statistical analysis

According to a study titled “p53 expression in prostatic cancer: An immunohistochemical study” done by Al-Nauimy et al, a sample size of 60 cases was included. All quantitative parameters such as age, PSA etc were arranged as frequency tables and other parameters such as correlation between p53 and Gleason score, p53 and histological grade etc were done by t test, ANOVA. A value of  $p < 0.05$  was taken significant.

## 4. Results

The present prospective study was conducted on 60 patients with 30 cases (50%) of BPH and 30 cases (50%) of adenocarcinoma in the department of pathology, M S Ramaiah Medical College and Hospital, Bangalore from May 2018 to June 2020 and following observations were made.

## 5. Observations

The present study showed that age has very low correlation with p53 expression, however average p53 was more among age groups around 70 years with majority of cases between 71 to 75 years. There were only 4 cases with age less than 60 years and 1 case with age above 90 years.

Based on the tumor differentiation there was 1 case (3.3%) of well differentiated carcinoma, 18 cases (60%) of moderately differentiated carcinoma and 11 cases (36.6%) of poorly differentiated carcinomas. We observed an inverse relationship between p53 expression and histological grade. All poorly differentiated carcinoma had higher p53 (>50% expression). In BPH p53 was expressed in all cases but percentage of expression was in the range of 8- 15% as compared to carcinoma where the range of expression was between 20- 70%. There was statistically significant difference in expression of p53 between cases of BPH and carcinoma prostate, indicated by P value of <0.05.

Significant relationship was found between p53 expression and different Gleason scores of prostate carcinoma. In our study Gleason score 9 was the commonest pattern observed in 15 cases (28%), followed by Gleason score 7 in 10 cases (33.3%) and Gleason score of 5 in 2 cases (66.6%). Gleason score of 6,8, 10 were seen in 1 case each. In our study Gleason score 5 was observed as the minimum score. Among prostate carcinomas p53 had higher expression on those cases with Gleason score 9 and 10.

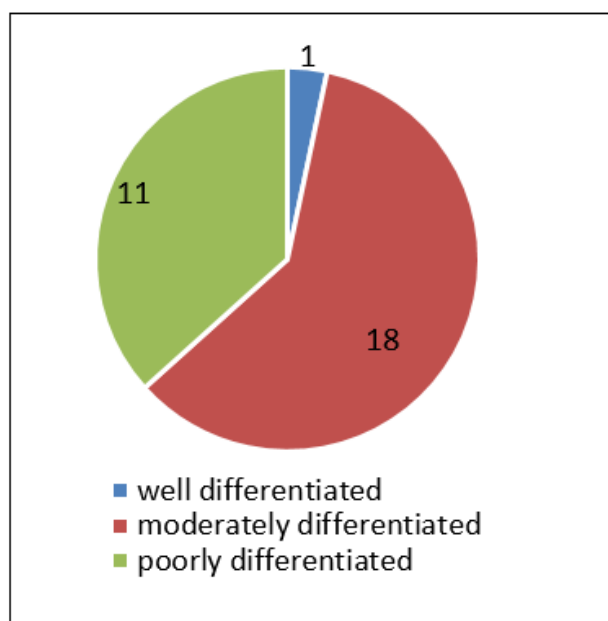
In our study the mean PSA value observed was 28.24ng/ml. The mean PSA value was 3.7ng/ml in BPH and 247.5ng/ml in prostate cancer.

**Table 1:**

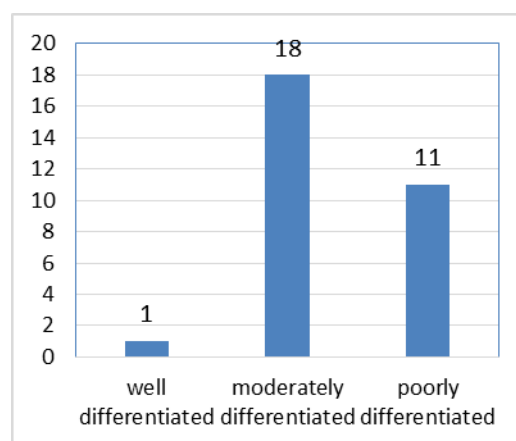
Variables	Mean values
Age	72.8 years
p53% in well differentiated carcinoma	25
p53% in moderately differentiated carcinoma	40.55
p53% in poorly differentiated carcinoma	58.18
PSA values	125.6
Gleasons score	7.96
Gleasons grade	3.7

## 6. Discussion

Prostate cancer is one of the most common solid tumors in Asia. The wide spectrum of biologic behaviour exhibited by prostatic neoplasms poses a difficult problem in predicting the clinical course for the individual patient.<sup>15,16</sup> Histopathology plays a very important role in preoperative and postoperative evaluation of prostate cancers. Although they are slow growing tumors, they vary widely in their aggressiveness.<sup>17</sup> There is an increase in the incidence of prostate neoplasms due to increase in public awareness



Graph 1: Histological grades of prostate carcinoma



Graph 2: p53 expression in varying histological grades of prostate adenocarcinoma

and screening efforts. Traditional prognostic markers such as grade, clinical stage, and pre-treatment prostate-specific antigen (PSA) are of limited prognostic value for individual patient.

Several studies have shown that p53 mutations are frequent in prostate cancer and are associated with advanced disease.<sup>17</sup> In some studies the incidence of p53 has been associated with higher grades of prostate cancers and worse prognosis of the disease.<sup>18</sup>

The p53 is present on the short arm of chromosome 17. The p53 gene is composed of 11 exons and has been highly conserved during evolution. The protein product coded by these exons is a 393-amino acid nuclear phosphoprotein (53 kDa). The allelic losses of p53 gene on the short arm of

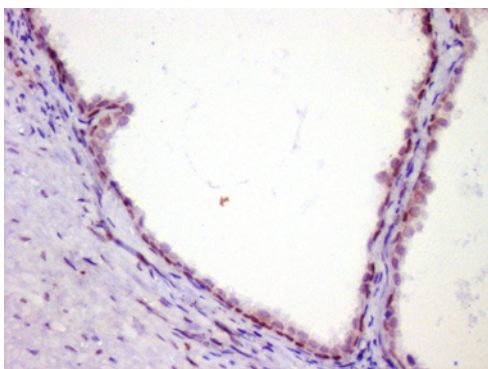
chromosome 17 are common in many human tumors, and the remaining p53 allele in those tumors frequently harbours point mutations. By this process, the normal p53 protein-associated cellular functions are lost from tumor cells and can contribute to oncogenesis in diverse neoplasms.<sup>16,19,20</sup>

The normal or wild type p53 protein has a very short half-life, whereas the altered/mutated protein has a much longer half-life. This property of the mutated p53 protein allows it to be more easily detected by immunohistochemical (IHC) methods.<sup>19</sup>

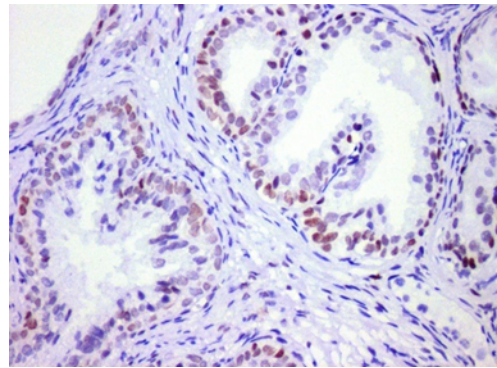
Considering the frequency of p53 mutation in prostate carcinoma and its association with Gleason score and histological grade, this study was done to evaluate the expression of p53 protein in patients with prostate cancer and BPH and its correlation with Gleason score, histological grade, PSA and age.

In this study p53 was expressed in all the cases (100%). However other studies by Moul et al. and Verma et al. reported that p53 was expressed in 69.1% and 66.7% respectively and this discrepancy could be attributed with the number of cases examined, as well as different scoring and cut off values of p53 protein expression. The present study revealed that 93.3% of all cases of carcinoma were of higher Gleason grade(>6 scale). These findings are in accordance with that of Nuaimy et al in which it was observed that 92% cases were of high Gleason grade (>6). On the other hand, 36.6% were diagnosed as poorly differentiated, 60% cases were diagnosed as moderately differentiated type and only one case of that of well differentiated type. These findings are similar to that of Nuaimy et al in which 50.2% cases were diagnosed as poorly differentiated type, 47.8% cases of moderately differentiated and 2% of well differentiated type.

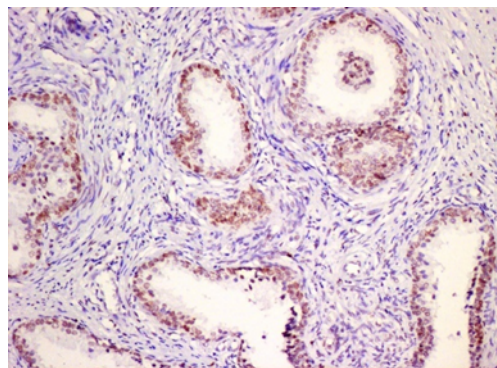
A significant direct relationship was found between p53 expression and different Gleason score of prostate carcinomas ( $p < 0.05$ ). It was highest in Gleason score 9 and 10. These findings are in agreement with that of Verma et al. in which a statistically significant correlation was observed between p53 expression and Gleason score of prostate carcinoma indicated by p value of 0.038.



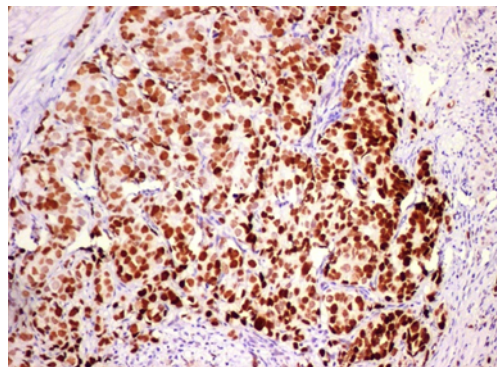
**Fig. 1:** Photomicrograph of BPH showing <10% p53 expression



**Fig. 2:** Photomicrograph of well differentiated prostate cancer showing 10 – 30% p53 expression



**Fig. 3:** Photomicrograph of moderately differentiated prostate cancer showing 30-50% p53 expression



**Fig. 4:** Photomicrograph of poorly differentiated prostate cancer showing > 50% p53 expression

## 7. Conclusion

P53 expression has been found in 100% of prostate carcinoma included in this study. P53 expression was directly correlating with Gleason score, while inversely correlating with tumor differentiation of prostate carcinoma cases. The expression of p53 was very low in BPH as

compared to that of prostate cancers. Hence it can be used as a good diagnostic and prognostic marker in prostate carcinoma. Further prospective clinical studies including long term follow up and molecular genetic analysis need to be undertaken to understand the biology of this IHC marker and to assess their prognostic significance in patients with prostate cancer.

## 8. Limitations

Sample size was less (60 cases). No follow up was done to assess long term prognosis. Some clinicopathological parameters such as local invasion, distal metastasis, lymph node status were not included in our study.

## 9. Source of Funding

None.

## 10. Conflict of Interest

The authors declare no conflict of interest.

## References

- Harris CC, Hollstein M. Clinical implications of the p53 tumor-suppressor gene. *N Engl J Med.* 1993;329(18):1318-27.
- Lane DP. The regulation of p53 function: Steiner Award Lecture. *Int J Cancer.* 1994;57(5):623-7.
- Rubin SJ, Hallahan DE, Ashman CR, Brachman DG, Beckett MA, Virudachalam S, et al. Two prostate carcinoma cell lines demonstrate abnormalities in tumor suppressor genes. *J Surg Oncol.* 1991;46(1):31-6.
- Visakorpi T, Kallioniemi OP, Heikkinen A, Koivulata, Isola J. Small subgroup of aggressive, highly proliferative prostatic carcinomas defined by p53 accumulation. *J Natl Cancer Inst.* 1992;84(11):883-7.
- Bookstein R, Macrogan D, Hilsenbeck SG, Sharkey F, Allred DC. p53 is mutated in a subset of advanced-stage prostate cancers. *Cancer Res.* 1993;53(14):3369-73.
- Navone NM, Troncoso P, Pisters LL, Goodrow TL, Palmer JL, Nichols WW, et al. p53 protein accumulation and gene mutation in the progression of human prostate carcinoma. *J Natl Cancer Inst.* 1993;85(20):1657-69.
- Uchida T, Wada C, Shitara T, Egawa S, Koshihara K. Infrequent involvement of p53 gene mutations in the tumorigenesis of Japanese prostate cancer. *Br J Cancer.* 1993;68(4):751-5.
- Van Veldhuizen P, Sadasivanr, Garcia F, Austenfeld MS, Stephens RL. Mutant p53 expression in prostate carcinoma. *Prostate.* 1993;22(1):23-30.
- Henke RP, Kruger E, Ayhan N, Hubner D, Hammerer P, Huland H. Immunohistochemical detection of p53 protein in human prostatic cancer. *J Urol.* 1994;152(4):1297-301.
- Aprikian AG, Sarkis AS, Fair WR, Zhang ZF, Fuks Z, Cordon-Cardo C. Immunohistochemical determination of p53 protein nuclear accumulation in prostatic adenocarcinoma. *J Urol.* 1994;151(5):1276-80.
- Kallakury BV, Figge J, Ross JS, Fisher HA, Figge HL, Jennings TA. Association of p53 immunoreactivity with high Gleason tumor grade in prostatic adenocarcinoma. *Hum Pathol.* 1994;25(1):92-7.
- Chen YQ, Gao X, Grignon DJ, Sarkar FH, Sakr W, Honn KV. Multiple mechanisms of p53 inactivation in prostatic carcinoma. *Cancer Molec Biol.* 1994;1:357-67.
- Visscher DW, Sarkar FH, Shimoyama RK, Crissman JD. Correlation between p53 immunostaining patterns and gene sequence mutations in breast carcinoma. *Diagn Mol Pathol.* 1996;5(3):187-93.
- Malkin D. Germline p53 mutations and heritable cancer. *Annu Rev Genet.* 1994;28:443-65.
- Mostofi FK. Grading of prostatic carcinoma. *Cancer Chemother Rep.* 1975;59(1):111-7.
- Zambetti DR, Levine AJ. A comparison of the biological activities of wild-type and mutant p53. *FASEB J.* 1993;7(10):855-65.
- Al-Nuaimy WM, Al-Allaf LI, Alnaimi HA. p53 expression in prostate cancer: An immunohistochemical study. *J Med J.* 2011;45:85-95.
- Verma R, Gupta V, Singh J. significance of p53 and Ki-67 expression in prostate cancer. *Urol Ann.* 2015;7:488-93.
- Harris CC, Hollstein M. Clinical implications of the p53 tumor suppressor gene. *N Engl J Med.* 1993;329(18):1318-27.
- Nigro J, Baker SJ, Preisinger AC, Jessup JM, Hostetter R, Cleary K, et al. Mutations in the p53 gene occur in diverse human tumor types. *Nature.* 1989;342(6250):705-8.

## Author biography

**Ganraj Bhat**, Pathologist

**Mohammed Afroz Ahamed**, Pathologist

**Neha Saroha**, Senior Resident

**Greeshma Prasad**, Post Graduate

**Cite this article:** Bhat G, Ahamed MA, Saroha N, Prasad G. Clinicopathological correlation of p53 expression in benign prostatic hyperplasia and prostate adenocarcinoma. *Indian J Pathol Oncol* 2022;9(1):60-64.