

Content available at: <https://www.ipinnovative.com/open-access-journals>

Indian Journal of Pathology and Oncology

Journal homepage: www.ijpo.co.in

Case Report

Verruciform xanthoma in groin – A case report

Nirmala Gaikwad^{1,*}

¹Dept. of Pathology, K.J. Somaiya Medical College, Mumbai, Maharashtra, India



ARTICLE INFO

Article history:

Received 07-05-2021

Accepted 03-09-2021

Available online 23-11-2021

Keywords:

Verruciform xanthoma

Groin

Foam cells

ABSTRACT

Verruciform xanthoma is a rare benign mucocutaneous lesion. Extra oral sites are also reported mainly on vulva, groin, penis and scrotum. Histopathologic diagnosis is diagnostic and confirmative. Histopathology shows subepithelial lipid laden foamy histiocytes associated with hyperkeratosis, parakeratosis, papillomatosis and elongation of rete ridges. Here we report a case of Verruciform xanthoma in groin.

This is an Open Access (OA) journal, and articles are distributed under the terms of the [Creative Commons Attribution-NonCommercial-ShareAlike 4.0 License](https://creativecommons.org/licenses/by-nc-sa/4.0/), which allows others to remix, tweak, and build upon the work non-commercially, as long as appropriate credit is given and the new creations are licensed under the identical terms.

For reprints contact: reprint@ipinnovative.com

1. Introduction

Verruciform xanthoma is an uncommon clinicopathological condition¹ with incidence rate of 0.025- 0.05%,² primarily affecting the oral mucosa. Very few cases are seen and reported in extra oral sites mainly vulva, scrotum, penis and groin. It was first described by Shafer in 1971. Extra oral site in Verruciform xanthoma was first reported by Santacruz in 1979.³ Generally these lesions are clinically diagnosed as papillomas. Histopathology is diagnostic and confirmative of these lesions. Histopathologically characterised by papillomatosis, epidermal hyperplasia with hyperkeratosis, parakeratosis and presence of neutrophils in spinous layers. Presence of numerous foam cells in dermal papillae^{4,5} with elongation of rete ridges.

2. Case Report

73 years old female presented in the outpatient department of our hospital with growth in the right groin, which appeared since one year. Gradually increased to present size. Patient was complaining of itching and bleeding from the

growth since two months. Growth was not painful. When asked about any other similar growth anywhere on the body, only single growth was present. Past medical history, she was an operated case of carcinoma endometrium and completed her chemotherapy cycles. Family history was non-contributory. On physical examination growth was skin covered, well circumscribed. Polypoidal, pedunculated with verrucous surface measuring about 2.0 x 1.8 x 1.0 cm noted in the right groin. Surrounding skin of the growth appeared unremarkable. Surgical excision of growth under local anaesthesia was performed. Specimen was sent to histopathology department for evaluation. The growth from right groin showed polypoidal lesion having papillomatous epithelial hyperplasia with hyperkeratosis, parakeratosis (Figure 1). There was no evidence of atypia or dysplasia in the epithelium. There was exocytosis of neutrophils in the upper layer of epithelium. A dense accumulation of foamy macrophages with lipid laden vacuoles were present throughout the papillary dermis (Figure 2). Based on all these histopathological findings, a diagnosis of Verruciform xanthoma in right groin was made.

* Corresponding author.

E-mail address: dr.nirmala.gaikwad2021@gmail.com (N. Gaikwad).

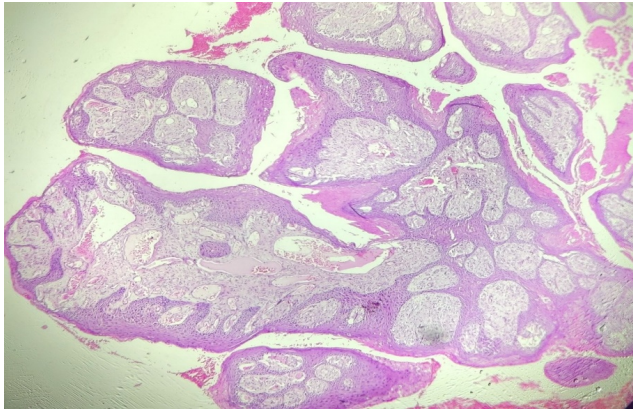


Fig. 1: Photomicrograph showing papillomatosis, hyperkeratosis and parakeratosis. (H & E, 40X)

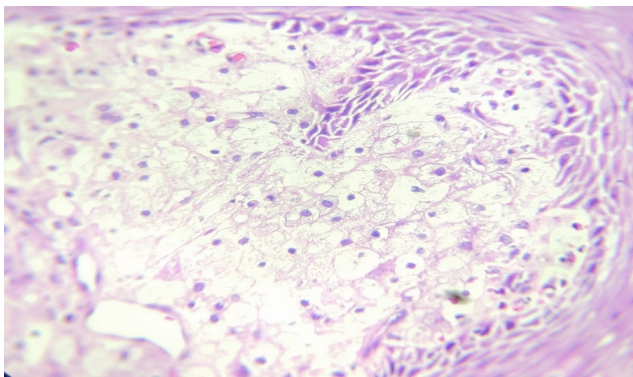


Fig. 2: Photomicrograph showing foaming cells in papillary dermis. (H & E, 400X)

3. Discussion

Verruciform xanthoma is an uncommon entity and very few publications are found in literature. Verruciform xanthoma are commonly seen at oral sites but non oral sites are rare.^{6,7} This may be due to lack of awareness of this condition or reluctance to biopsy of the growth. Usually these lesions are warts or condylomata or papilloma on clinical diagnosis.¹

Verruciform xanthoma usually present as a solitary, sessile or pedunculated lesion with rough or pebbly surface. Generally these lesions are asymptomatic or may be pruritic like in our case. These lesions generally range from 2mm to 2.5 cm in size. They are pale, white or red in colour. These lesions are commonly reported in adults of 40 years and 70 years of age. According to Philipsen et al Verruciform xanthoma are common in males below the age of 50 years and reverse trend was noted in females where lesion was noted in age group above 50 years like in our case 73 years female.²

Verruciform xanthoma occurs as an isolated, solitary lesions in most cases² like in our case. But multiple lesions are also reported. Association of these lesions with other diseases like snuff dipper's keratosis, Pemphigus vulgaris,

lichen sclerosis, CHILD syndrome,⁸ regressive dystrophic epidermolysis bullosa,⁹ seborrheic keratosis,¹⁰ psoriasis,¹¹ carcinoma in situ have been reported. It is also been reported in an immune comprised patient,¹² patients with hypercholesterolemia and hepatitis C virus carriers.¹³ Only one report of its association with systemic lipid storage disease has been reported. Hence it does not seem to be related to any lipid metabolism abnormality.⁸

Verruciform xanthoma have been divided into three groups verrucous, papillary and flat on basis of histomorphological appearance of the epithelial changes.¹ The diagnostic histologic finding of all Verruciform xanthomas, oral and extra oral sites, is the presence of foam cells in the dermal papillae and submucosal space. These foam cells have been shown to have monocyte /macrophage lineage.¹⁴

Due to clinical appearance and histological findings, Verruciform xanthoma closely resembles HPV induced lesions like verrucae and condylomata. Verruciform xanthoma are common in oral and extra oral sites like HPV. HPV infection was thought as the etiological agent. Most authors have not found any evidence for the presence of HPV in these lesions.¹

There is damage to keratinocytes by inciting agent which is followed by degeneration of keratinocytes. These degenerated keratinocytes attract dermal dendrocytes to engulf the debris and these develop into foam cells due to ingestion of lipids from degenerating keratinocytes in the dermal papillae. This pathogenesis of lipid laden macrophages is proposed by Zegarelli.¹⁵

Therapeutic options for Verruciform xanthoma included topical steroids, carbon dioxide laser, cryotherapy, wire-loop electrosectioning and radio therapy. But none of these was completely effective and safe.¹⁶ Surgical excision is the most effective treatment for Verruciform xanthoma to date. The lesion did not reappear after excision in our patient.

4. Conclusion

Verruciform xanthoma can be confused with benign, premalignant and malignant lesions like condylomata accuminata, leucoplakia, verrucous carcinoma.

Warts induced by HPV are almost always multiple. Hence biopsy of solitary lesions in oral and extra oral sites should always be subjected to confirm the diagnosis and to rule out malignancy. The definitive and confirmative diagnosis can be done on histopathological examination.

5. Source of Funding

None.

6. Conflict of Interest

The authors declare no conflict of interest.

References

1. Joshi R, Ovhal A. Verruciform xanthoma: Report of five cases. *Indian J Dermatol.* 2012;57(6):479–82. doi:10.4103/0019-5154.103069.
2. Hegde U, Doddawad VG, Sreeshyla HS, Patil R, Rekha Patil; Verruciform xanthoma: A view on the concepts of its etiopathogenesis. *J Oral Maxillofac Pathol.* 2013;17(3):392–6.
3. Safer WG. Verruciform xanthoma. *Oral Surg.* 1971;31:784–9.
4. Buchner A, Hannsen LS, Merell PW. Verruciform xanthoma of the oral mucosa. Report of five cases and review of the literature. *Arch Dermatol.* 1981;117:563–5.
5. Nowparast B, Howell FV, Rick GM. Verruciform xanthoma. A clinico-pathologic review and report of fifty-four cases. *Oral Surg.* 1981;51:619–25.
6. Damm DD, Fantasia JE. Rough white patch of gingiva. Verruciform xanthoma. *Gen Dent.* 2002;50:378–80.
7. Dorankula SPR, Ramani P, Premkuma P, Anuja, Sherlyn HJ. Verruciform xanthoma of oral cavity- A case report. *J Clin Diagn Res.* 2013;7(8):1799–801.
8. Sah K, Kale AD, Hallikerimath S. Verruciform xanthoma: Report of two cases and review on pathogenesis. *J Oral Maxillofac Pathol.* 2008;12:41–4.
9. Huang JS, Tseng CC, Jin YT, Huang CC, Wong TY, Chen HA, et al. Verruciform xanthoma. Case report and literature review. *J Periodontol.* 1996;67:162–5.
10. Wu YH, Hsiao PF, Lin YC. Verruciform xanthoma like phenomenon in seborrheic keratosis. *J Cutan Pathol.* 2001;33:373–7.
11. Rawal SY, Kalmar JR, Tatakis DN. Verruciform xanthoma: Immunohistochemical characterization of xanthoma cell phenotype. *J Periodontol.* 2001;78:504–9.
12. Hu JA, Li Y, Li S. Verruciform xanthoma of the oral cavity: Clinicopathological study relating to pathogenesis. Report of three cases. *APMIS.* 2005;113(9):629–34.
13. Ide F, Obara K, Yamada H, Mishima K, Saito I, Kusama K. Cellular basis of verruciform xanthoma: Immunohistochemical and ultrastructural characterization. *Oral Dis.* 2008;14:150–7.
14. Philipsen HP, Reichart PA, Takata T, Ogawa I. Verruciform xanthoma: Biological profile of 282 oral lesions based on literature and survey with nine new cases from Japan. *Oral Oncol.* 2003;9:325–36.
15. Zegarelli DJ, Zegarelli-Schmidt E, Zegarelli EV. Verruciform xanthoma: A clinical, light microscopic and electron microscopic study of two cases. *Oral Surg.* 1974;38:725–34.
16. Li Z, Wang Y. Verruciform xanthoma of the thumb. *Indian J Dermatol Venereol Leprol.* 2018;84:67–9.

Author biography

Nirmala Gaikwad, Associate Professor

Cite this article: Gaikwad N. Verruciform xanthoma in groin – A case report. *Indian J Pathol Oncol* 2021;8(4):530-532.