

Omphalomesenteric duct cyst with heterotopic gastric mucosa presenting as persistent umbilical discharge

Abhijeet B Jagtap^{1*}, Harshal S Dhongade²

¹MD Pathology, Consultant Pathologist and Head, Laboratory Services, Apollo Hospitals Nashik

²MD Radiology, Consultant Radiologist, Radiology Services, Apollo Hospitals Nashik

*Corresponding Author:

E-mail: drabij@gmail.com

Abstract

Umbilical discharge in infancy is often attributed to infection or an umbilical granuloma. It is important to investigate if such a discharge is due to an underlying congenital abnormality because corrective surgical intervention may then be required. Umbilical discharge due to underlying cysts and nodules in the early childhood have varied etiology. We present a case of histologically proven omphalomesenteric duct cyst lined by gastric mucosa with late and unique presentation that needed surgical intervention and was treated successfully.

Key words: Umbilical cyst, omphalomesenteric duct cyst.

| Access this article online | |
|--|---|
| Quick Response Code: | Website: www.innovativepublication.com |
|  | DOI: 10.5958/2394-6792.2016.00023.5 |

Introduction

Umbilical discharge due to underlying cysts, polyps and nodules of the umbilical and peri-umbilical region may pose diagnostic dilemma clinically, radiologically and less often histopathologically. Umbilical disorders may result from embryological anomalies. It is important to identify the basic defect and treat it accordingly.

OMD (Omphalomesenteric duct) remnant anomalies are a group of disorders, relatively uncommon but an important cause of umbilical nodule, polyp, obstruction, pain, hernia, persistent discharge or combination of such presentations in neonatal or infantile age group¹.

Subtle persistence and clinical presentation in early childhood as in our case is particularly rare. OMD is an embryological communication between yolk sac and developing midgut. By 10 weeks of gestation it normally regresses forming a fibrous cord that runs from small intestine to umbilicus. If the lumen of the fibrous cord remains unobliterated, it may lead to variety of anomalies as depicted in the **Fig.4**. As many as two percent of the population suffers from these anomalies, commonest being MDv(Meckel diverticulum)². We present here a case of umbilical cyst with persistent serous discharge clinically and histologically proven gastric antral mucosa.

Case Report

2.5 years old male child was referred to our superspecialty clinic for unusual serous discharge through the umbilicus. The child was otherwise asymptomatic. On examination in outpatient department, there was clear serous discharge from the lower part of the umbilicus. Mild erythema in the infraumbilical region was noted. There was no tenderness or mass and no gross congenital anomalies were noted.

Ultrasound examination revealed a small well defined cystic lesion with no internal echoes within. The wall of the cyst was thin and echogenic. There was no obvious connection of the cyst with the underlying bowel loops. The cyst was surrounded by organized debris. An obliterated hypoechoic tract was seen extending from the dome of urinary bladder inferiorly and ending just a few millimeters away from the cystic lesion at the infra-umbilical region probably representing obliterated urachus (**Fig.1**).

Laparoscopic resection of the infra-umbilical cyst was performed and the specimen was received by the laboratory. On gross examination, the specimen showed a whitish mass with attached fibrous cord. Serial sectioning of the mass revealed whitish mucosa. Entire specimen with attached cord was processed and examined microscopically. Histopathological examination revealed a nodule lined by gastric antral type mucosa with muscular wall abruptly ending to form a fibrous cord (**Fig.2&3**). Neither Goblet cells, nor intestinal metaplasia nor dysplasia was noted. There was no ulceration. No heterologous elements were noted. The fibrous cord showed dilated lymphatics. The diagnosis of OMD cyst was made. The patient was declared cured and discharged on prophylactic, local and systemic antibacterial therapy. Follow up after 14 days was unremarkable. There was no discharge, swelling or wound.

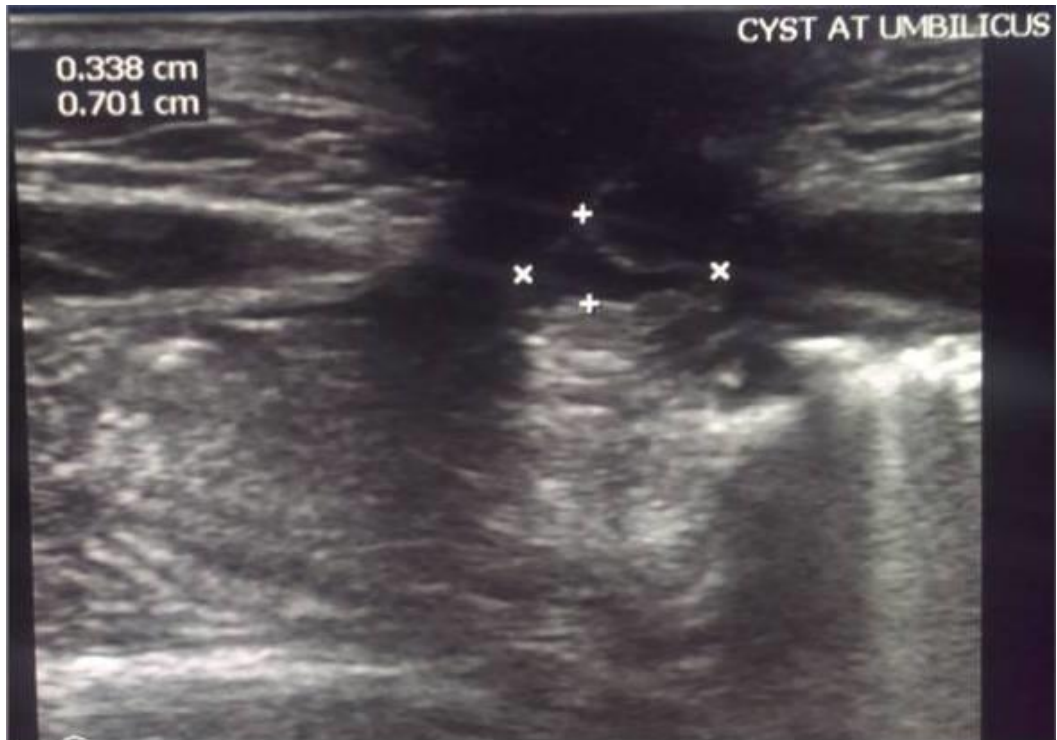


Fig. 1: Ultrasound: Note a small 7x 3.4mm sized well defined cyst with thin and echogenic walls and with no obvious attachment to any intraperitoneal structure. The cyst is surrounded by debris.

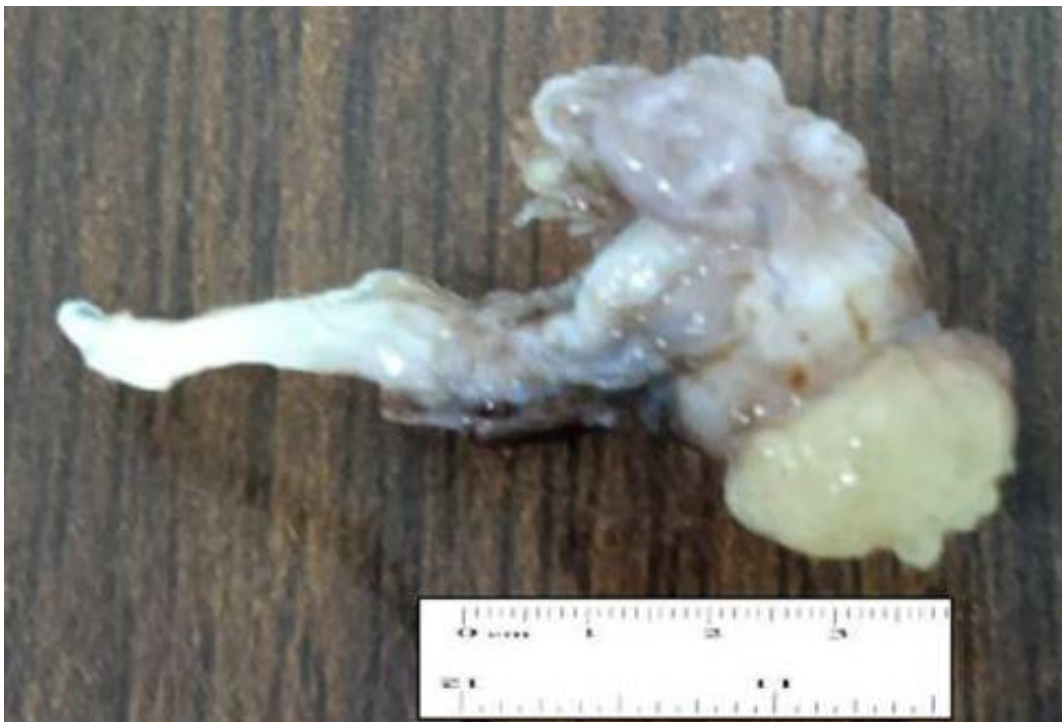

Fig. 2: Gross appearance of the resected OMD cyst: Note the yellowish white, mucosa covered cystic nodule with attached fibrous cord

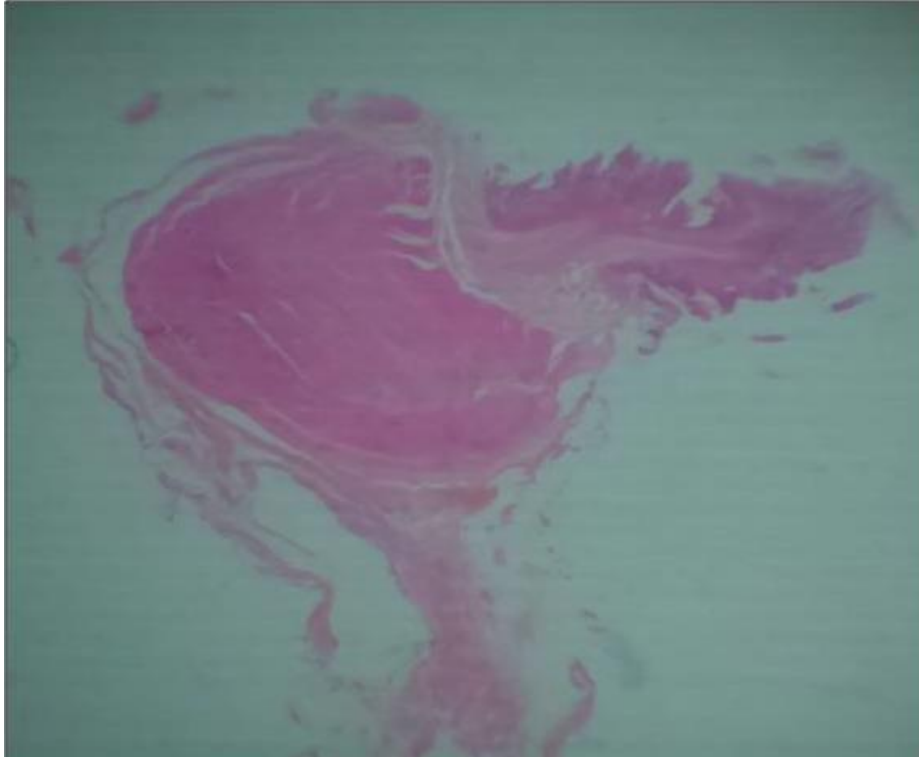


Fig. 3(A): Whole mount section of umbilical nodule: Note the full thickness Gastric antral mucosa and double layered muscularis propria along with fibrous cord.

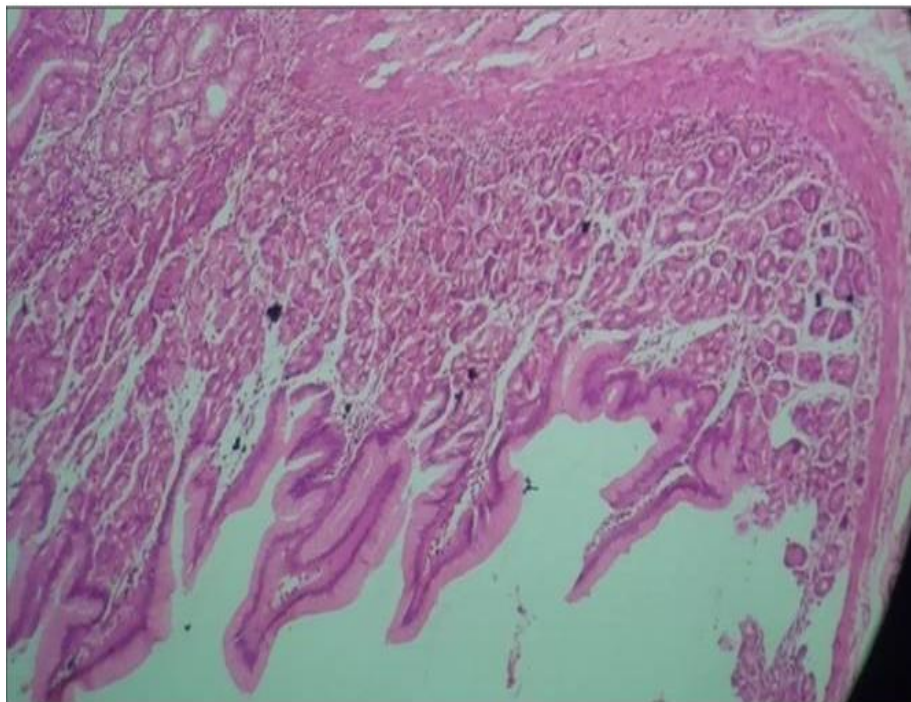


Fig. 3(B) & 3(C): Histology of umbilical nodule: note the Gastric antral epithelium comprised of parietal cells; Note the presence of Brunner glands and absence of Goblet cells.

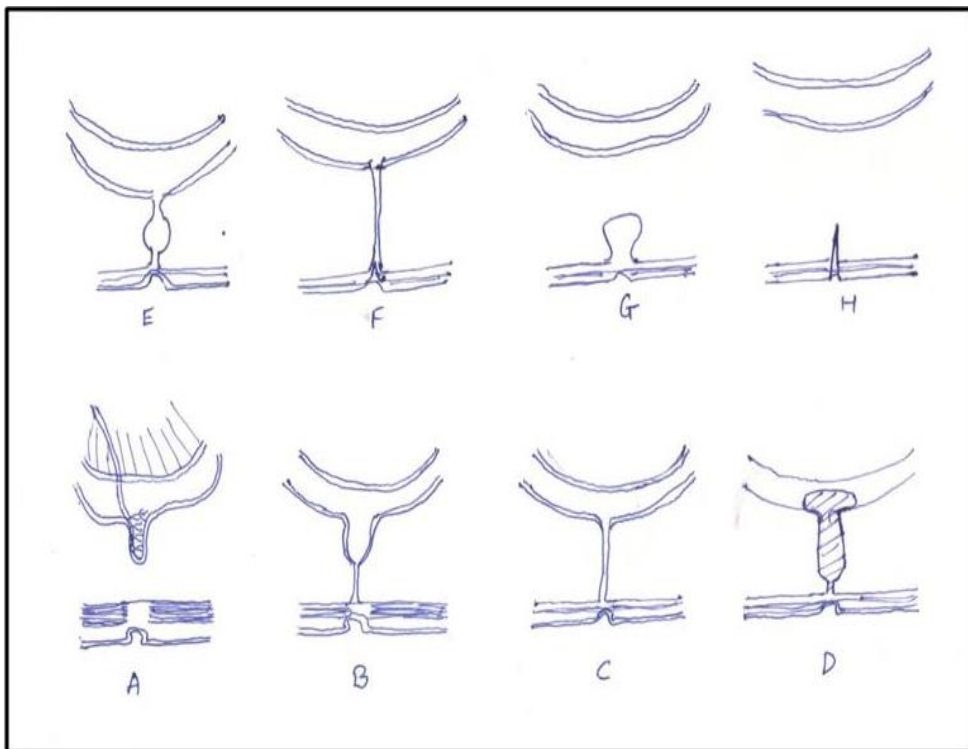
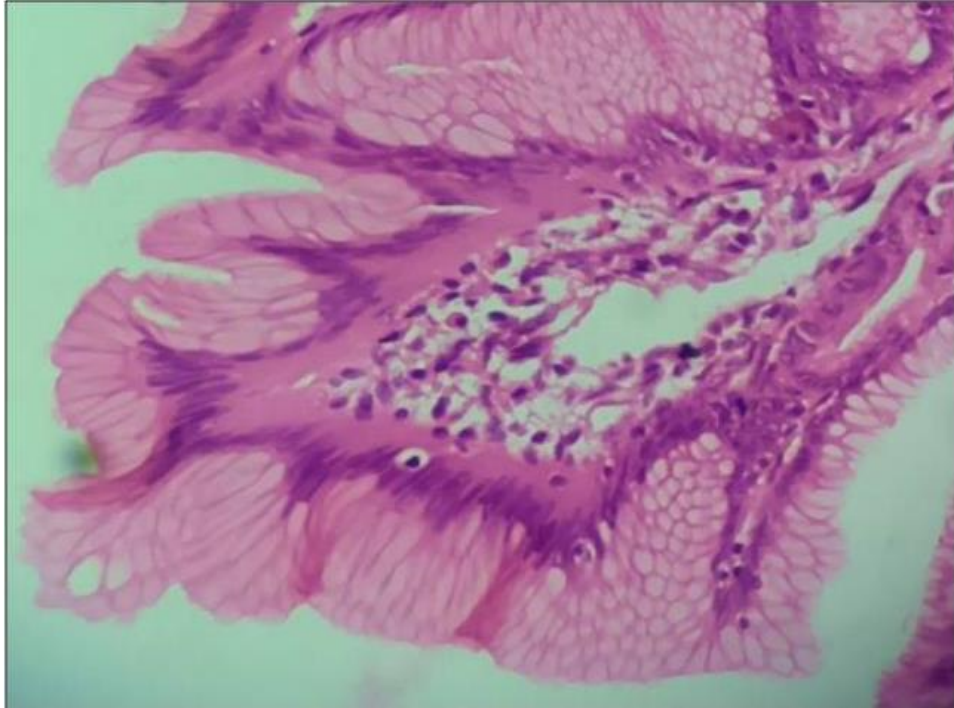


Fig. 4: Omphalomesenteric duct remnants.

- (A) Meckel diverticulum with separate feeding vessel
- (B) Meckel diverticulum attached to posterior surface of anterior abdominal wall by a fibrous cord.
- (C) Fibrous cord attaching ileum to abdominal wall.
- (D) Intestinal-umbilical fistula. Intestinal mucosa extends to skin surface.
- (E) Omphalomesenteric cyst arising in a fibrous cord.
- (F) Umbilical sinus ending in a fibrous cord attaching to the ileum.
- (G, H) Omphalomesenteric cyst and sinus without intestinal attachments.

Discussion

The diagnosis of umbilical discharge rests upon age at presentation, imaging findings and histological correlation. The conditions such as umbilical granuloma, umbilical hernia, persistent urachus, omphalocele may present as nodule, mass or cyst with or without discharge and must be evaluated.

Failure of involution or obliteration of omphalomesenteric duct also termed as vitello-intestinal duct may lead to various anomalies which present as umbilical nodule or cyst with or without discharge as depicted in **Fig.4**. Such remnants are observed in about 2% of the infants^{1,2}. Although most OMD remnants remain silent about 6 to 40% of OMD remnants may become symptomatic due to ulceration, discharge, infection, obstruction or hemorrhage^{3,4,5}. Most of them present within first two years of life. Around 67% OMD remnants develop into MDv and a very few present as Omphalomesenteric cyst¹.

Vane *et al* reported only three cases of Omphalomesenteric cyst in a series of 217 children with OMD remnants⁵. OMD remnants are found more than twice in male children than with female counterpart. OMD remnants in adults are usually asymptomatic.

Review of literature revealed only three case of Omphalomesenteric cyst presenting as umbilical nodule; one in 6 years old female child presenting as umbilical mass, another in 2 year old female child with presenting as umbilical nodule and another female child of 6 months with persistent umbilical discharge⁶.

To best of our knowledge our case is first of a male child over 2 years of age presenting with persistent umbilical discharge as a manifestation of umbilical cyst which histologically showed heterotopic gastric mucosa. Heterotopic mucosa in OMD remnants is known to be present in higher frequency in symptomatic cases. Commonly encountered ectopic tissues are gastric mucosa and pancreatic tissue. Such ectopic gastric mucosa may produce physiologically effective amount of gastric acid producing inflammation and ulceration which in turn may lead to infection of cyst or nodule. Persistence of umbilical discharge despite early interventions such as silver nitrate application warrants ultrasound examination.

Ultrasound examination can help in narrowing the differential diagnosis in such cases⁶. In older children and adults such cysts producing gastric acid may be mistaken for neoplasms^{1,7}. The treatment for all symptomatic OMD remnants especially cysts with imminent complications includes conventional or laparoscopic surgical intervention while those asymptomatic can be followed up⁷.

Conclusion

As discussed earlier, persistent umbilical discharge may be attributed to variety of congenital abnormalities including OMD cyst which is rare but an important cause

of such discharge that can be evaluated and treated in its early course to avoid complications.

Conflict of Interest

There are no conflicts of interests among the authors or with any other individual.

Abbreviations:

MDv: Meckel diverticulum

OMD: Omphalomesenteric duct

References:

1. Sawada F, Yoshimura R, Ito K, Nakamura K, Nawata H, Mizumoto K *et al*. Adult case of an omphalomesenteric cyst resected by laparoscopic-assisted surgery. *World J Gastroenterol* 2006;12:825-827
2. Shaw A: Disorders of the umbilicus in Welch KJ, Randolph JG, Ravitch MM *et al* (eds). *Pediatric Surgery*. (ed 4) Chicago, IL, Year Book Medical Publisher, Inc, 1986; 731-739
3. Ballester I, Betloch I, Pérez-Crespo M, Toledo F, Cuesta L. (2009). Atypical presentation of an omphalomesenteric duct cyst. *Dermatology Online Journal*, 15(6). Retrieved from: <http://escholarship.org/uc/item/1h00t1fp> (Accessed on 20th October 2015).
4. Pacilli M, Sebire NJ, Maritsi D, Kiely EM, Drake DP, Curry JJ, Pierro A. Umbilical polyp in infants and children. *Eur J Pediatr Surg*. 2007;17:397-9.
5. Vane DW, West KW, Grosfeld JL. Vitelline duct anomalies: Experience with 217 childhood cases. *Arch Surg* 1987;122:542-547. doi:10.1001/archsurg.1987.01400170048007.
6. Tamilselvan K, Mohan A, Cheslyn-Curtis S, Eisenhut M. Persistent umbilical discharge from an omphalomesenteric duct cyst containing gastric mucosa. *Case Reports in Pediatrics*, 2012, Article ID 482185, 3 pages, 2012. doi:10.1155/2012/482185.
7. Khan AY, Qureshi MA, Akhtar J. Omphalomesenteric duct cyst in an omphalocele: A rare association. *Pak J Med Sci* 2013;29:866-868.