

## A Case Report on Adenoid Cystic Carcinoma of Uterine Cervix: A Rare Occurrence

Iffat Jamal

MD Pathology, Department Of Pathology,  
Patna Medical College and Hospital, Patna-800004, Bihar  
E-mail: iffatjamal111@gmail.com

### Abstract

Adenoid cystic carcinoma constitutes around 0.5%-2% of all carcinomas of uterine cervix. It usually presents in elderly age group. Very few cases have been reported in young age group. Adenoid cystic carcinoma is a rare variant of adenocarcinoma cervix. It is a locally aggressive tumour which is capable of distant metastasis in its early stage. This is a case report of Adenoid cystic carcinoma of uterine cervix, Stage III that was successfully operated upon and followed by radiotherapy.

**Key words:** Adenoid cystic carcinoma, Adenoid basal carcinoma, adenocarcinoma, metastasis, uterine cervix

Access this article online	
Quick Response Code:	Website: www.innovativepublication.com
	DOI: 10.5958/2394-6792.2016.00022.3

### Introduction

Adenoid Cystic carcinoma is also called cylindroma is most commonly seen in salivary glands and respiratory tracts. Adenoid cystic carcinoma of uterine cervix is found rarely and it resembles Adenoid cystic carcinoma of salivary glands histopathologically. It constitutes 0.5-2% of all carcinomas of cervix. In this case report Adenoid cystic carcinoma of an elderly woman is presented who was treated successfully with no recurrence or metastasis of the tumour.

### Case Report

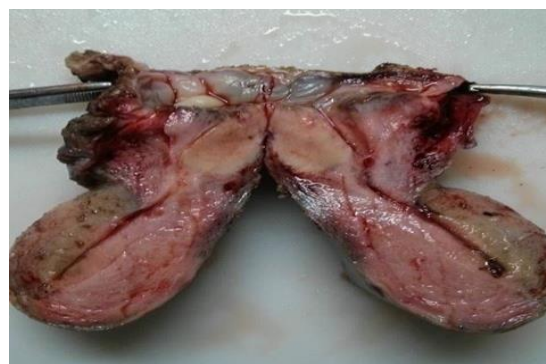A 62 year old elderly woman, Gravida-5, para-4 was admitted to Patna Medical College & Hospital, Patna with complaint of genital bleeding for 10 days. On per speculum examination: The portio had a grayish white cauliflower like growth that infiltrated anterior wall of vaginal fornix. Bimanual and rectal examination revealed that the tumour had infiltrated to both sides of parametrium and left pelvic bone as well.

Cervical punch biopsy was performed and the specimen was sent for histopathological examination. The histological findings showed round nests of basaloid cells that were arranged in cribriform pattern having eosinophilic homogenous secretions.

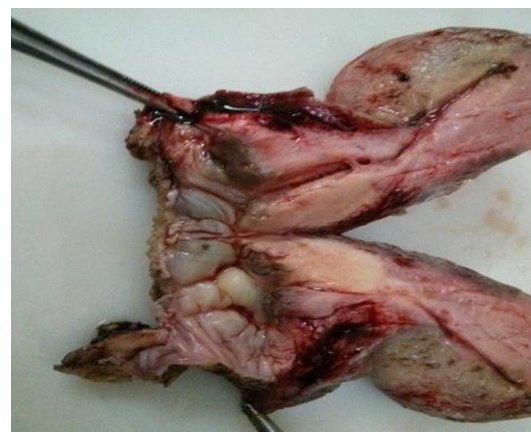Immunohistochemistry was performed that showed that tumour cells were positive for CK17, CK19, Pancytokeratin but were negative for CK14, SMA, S-100.

Chest X-ray, Abdominal imaging, GI endoscopy and cystoscopy revealed no findings of metastasis to other organs or lymph nodes.

Tumour markers like CEA, EMA were within normal limits. Patient was diagnosed to be suffering from Carcinoma Cervix Stage III. The tumour was surgically removed and followed with radiotherapy. On follow up-patient was well without any evidence of recurrence of tumour or any distant metastasis after 5 year of treatment.

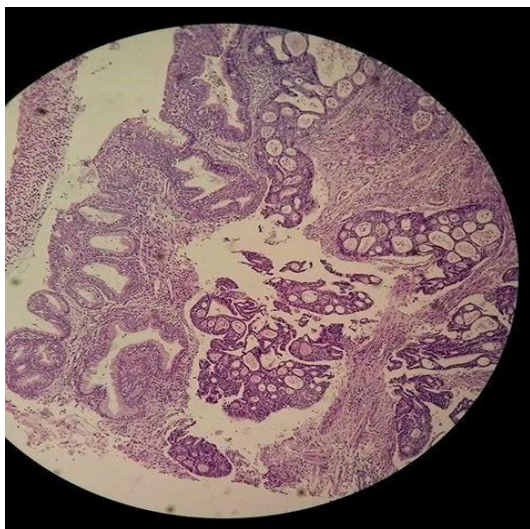


1(A).

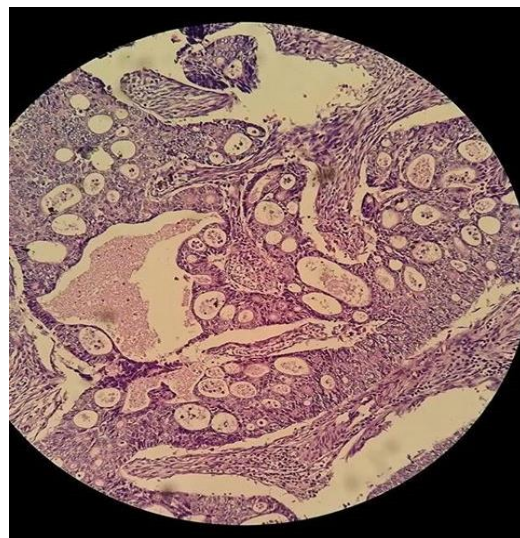


1(B).

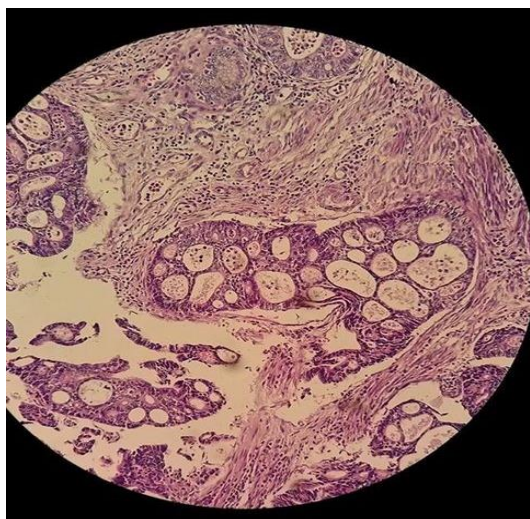**Fig: 1(A) and 1(B): Grayish white clouded growth visible at uterine cervix on gross**



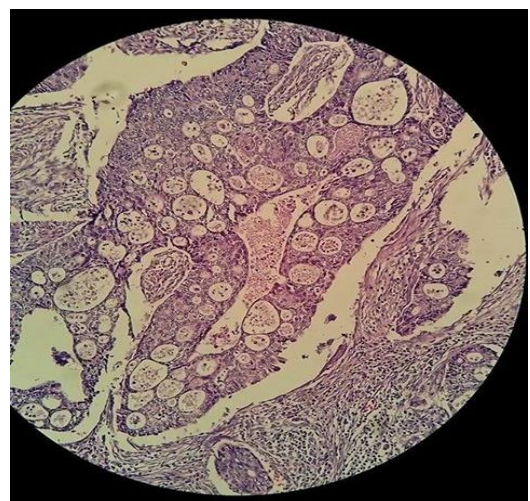
**Fig 2: Lower magnification-showing glandular and cystic spaces filled with eosinophilic secretions.**



**Fig. 5**  
**Fig. 3, 4 & 5 (higher magnification) showing histologically tumour cells are arranged in cribriform pattern, with eosinophilic secretions.**



**Fig. 3**



**Fig. 4**

### Discussion

Irrespective of its anatomic location, Adenoid cystic carcinoma has a characteristic histological appearance<sup>[1]</sup>. Its common sites of occurrence are salivary glands, respiratory tract, nasopharynx, nasal sinuses and lacrimal glands. It is a highly aggressive tumour capable of local and distant metastasis. Uterine cervix is a rare location for Adenoid cystic carcinoma<sup>[2]</sup>.

Grossly it usually has a solid appearance and an infiltrative pattern of growth. Histologically typical adenoid cystic carcinoma has cribriform pattern with nests and columns of cells arranged concentrically around glandlike spaces(pseudocysts) filled with homogenous eosinophilic Periodic acid-Schiff(PAS) positive material. There is presence of both true and false glandular lumina which is required to make a diagnosis of adenoid cystic carcinoma<sup>[3]</sup>. The different patterns of growth in adenoid cystic carcinoma are tubular(most common), solid and sclerosing. It is mostly associated with neural invasion.

The main ultrastructural features of Adenoid cystic carcinoma are pseudocysts, intercellular spaces, abundant basal lamina and true glandular lumens. The cell types present combine features of intercalated ducts, myoepithelial cells, secretory cells and pluripotential reserve cells.

Immunohistochemically tumour cells are positive for keratin, lysozyme, CD117. There is a strong reactivity for the basement membrane components like type IV collagen and laminin<sup>[4]</sup>. And those around pseudocysts are positive for S-100 and Actin which are suggestive of myoepithelial origin.

Differential diagnosis of Adenoid cystic carcinoma is adenoid basal carcinoma. Adenoid basal carcinoma is a very low grade lesion with low mitotic rate, good prognosis, less metastasizing capacity and less stromal reaction<sup>[5,6]</sup>. Another differential diagnosis of adenoid cystic carcinoma is adenocarcinoma cervix<sup>[7]</sup>. Adenoid cystic carcinoma frequently metastasize to lungs. Factors that influence prognosis of Adenoid cystic carcinoma are pattern of arrangement of tumour cells, margin involvement, anatomic site & size, degree of atypic, mitotic activity and lymph node metastasis<sup>[8]</sup>. The solid or anaplastic variant of adenoid cystic carcinoma are associated with higher incidence of metastasis.

Treatment of Adenoid cystic carcinoma is same as that of squamous cell carcinoma<sup>[9]</sup>. In this case hysterectomy was performed and then followed by radiotherapy. The patient was followed up and showed no evidence of recurrence or metastasis to other organs. Rose et al. advocated chemotherapy involving Cisplatin and Radiotherapy to improve survival rates and progression free survival rates among women with locally advanced cervical cancer<sup>[10]</sup>.

## Conclusion

Adenoid cystic carcinoma is a very rare carcinoma reported at uterine cervix notorious for its local recurrence and metastasis to distant organs. A radical surgery with chemo-radiotherapy is the treatment modality of choice.

**Consent:** A fully informed consent from the patient family for the publications of this case-report and accompanying images was taken.

**Conflict of interests:** The author declares that there is no conflict of interests.

## References:

1. Juan Rosai, Rosai and Ackerman's Surgical pathology, Volume 1, 10e, Major and minor salivary glands, 833-835.
2. Fowler, WC, Jr, Miles, PA, Surwit, EA, et al. 1978 Adenoid cystic carcinoma of the cervix. Report of nine cases and a reappraisal *Obstet Gynecol* 52:337-373
3. Sousa, J, Sharma, RR, Delmendo, A, et al. 2001 Primary orbito-cranial adenoid cystic carcinoma with torcular metastasis: a case report and review of the literature *J Clin Neurosci* 14:1731-1736
4. Grayson, W, Taylor, LF, Cooper, K 1999 Adenoid cystic and adenoid basal carcinoma of the uterine cervix: comparative morphologic, mucin, and immunohistochemical profile of two rare neoplasms of putative "reserve cell" origin *Am J Surg Pathol* 23:44
5. Miles, PA, Norris, HJ 1971 Adenoid cystic carcinoma of the cervix. An analysis of 12 cases *Obstet Gynecol* 38:1031-1040
6. Tchertkoff, V, Sedlis, A 1962 Cyndroma of the cervix *Am J Obstet Gynecol* 84:749-752
7. Dixit, S, Singhal, S, Vyas, R, et al. 1993 Adenoid cystic carcinoma of the cervix *J Postgrad Med* 39:211-215.
8. Ellis, G., and Auclair, P. (1996). Tumors of the salivary glands, Fascicle 17, Third edn (Washington, D.C., Armed Forces Institute of Pathology).
9. Fordice, J., Kershaw, C., el-Naggar, A., and Goepfert, H. (1999). Adenoid cystic carcinoma of the head and neck. Predictors of morbidity and mortality. *Arch Otolaryngol Head Neck Surg* 125, 149-152.
10. Spiers, A., Esseltine, D., Ruckdeschel, J., Davies, J., and Horton, J. (1996). Metastatic adenoid cystic carcinoma of salivary glands: Case reports and review of the literature, *Cancer Control* 3, 336-342.