



## Original Research Article

## Clinicopathological study of Tubo ovarian masses- A study of 110 cases

Sunita Bhargava<sup>1</sup>, Gunjan Bhatia<sup>1,\*</sup><sup>1</sup>Dept. of Pathology, RNT Medical College, Udaipur, Rajasthan, India

## ARTICLE INFO

## Article history:

Received 17-05-2020

Accepted 30-11-2020

Available online 20-02-2021

## Keywords:

Adnexal mass

Ectopic pregnancy

Ovarian neoplasms

## ABSTRACT

**Introduction:** An adnexal mass is a common clinical presentation in gynecological practice. Differential diagnosis of an adnexal mass can vary from a life threatening emergency like ectopic gestation to a malignant lesion with a high mortality rate, so it poses diagnostic challenge for treating gynecologist.

**Aim:** To study the histopathological nature of adnexal masses.

**Material and Methods:** 110 cases of adnexal masses who underwent surgical intervention during the study period of one year were included in the study. Specimen received in the department of Pathology and was subjected to histopathological examination.

**Results:** A total of 110 cases formed the study group. In our study 79% of cases of adnexal masses had an ovarian origin, 15.45% cases were of tubal origin and 5.45% cases had combined pathology i.e due to tuboovarian abscess and endometriosis. Among Ovarian lesions 9.1% had non neoplastic cyst like corpus luteal cyst or endometriosis whereas 50% cases had a surface epithelial lesion. 77 cases out of a total of 110 were ovarian in origin, out of which 57(74%) were benign, 05(6.5%) were borderline and 15(19.5%) were malignant.

**Discussion:** To conclude, adnexal mass often poses a diagnostic dilemma to the treating physician. Ectopic gestation is often a cause of adnexal mass among patients of reproductive age group. Ovarian neoplasm constitute another major cause of adnexal mass, serous cyst adenoma is the commonest benign lesion seen while serous cyst adenocarcinoma is the commonest malignant ovarian lesion.

© This is an open access article distributed under the terms of the Creative Commons Attribution License (<https://creativecommons.org/licenses/by/4.0/>) which permits unrestricted use, distribution, and reproduction in any medium, provided the original author and source are credited.

## 1. Introduction

An adnexal mass (mass arising from ovary, fallopian tube or the surrounding connective tissue) is a common clinical presentation in gynecological practice. The term Adnexal mass is most often used to denote masses arising from the ovary because of high propensity of ovary for neoplasia. Differential diagnosis of an adnexal mass is complex and can vary from functional cyst to life threatening ectopic pregnancies to ovarian malignancy.<sup>1</sup>

Ovarian Cancer remains the leading cause of cancer among females and constitutes about 30% of all cancers of female genital tract.<sup>2</sup> Globally Ovarian malignancy is the sixth most common cancer (age standardized incidence

rate 6.6/100,000) and seventh leading cause of cancer deaths (Mortality rate 4.0/100,000).<sup>3,4</sup> In India ovarian cancer has emerged as the third common malignancy among females with an incidence varying between 5.4-8 per 100000 population.<sup>5</sup>

Since ovarian malignancies have very few and non-specific symptoms they are mostly diagnosed at a very late stage leading to a very poor prognosis in most cases. The overall 5-year survival is approximately 45%, primarily due to the late stage of the diagnosis of the disease. Early detection of ovarian malignancy is of paramount importance as it would lead to better prognosis. Histopathology remains the gold standard for diagnosis of Ovarian Malignancy.

\* Corresponding author.

E-mail address: [gunjanpath@gmail.com](mailto:gunjanpath@gmail.com) (G. Bhatia).

## 2. Aims and Objectives

1. To study the histopathological nature of adnexal masses.

## 3. Material and Methods

The study was carried out in a government medical college and hospital. The study was conducted on adnexal masses which were operated in Department of Obstetrics and Gynecology and Surgery during a period of one year from July 2018 to 2019 and specimens sent to department of Pathology for Histopathological examination.

Prior approval from the Institutional Ethics committee was sought. Written consent was taken from all patients and details were recorded on a pre designed proforma. Detailed Clinical history, ultrasound findings, CA 125 levels (wherever available) was recorded in the proforma.

A total of 110 cases of adnexal masses were included in the study. Specimens received in the department of Pathology were labeled, Gross examination was done and the tissue was preserved in 10% formalin immediately. After fixation of the tissue for 24-48 hours, it was sectioned and processed for microscopy. Slides were stained with Hematoxylin and Eosin stain.

## 4. Results

A total of 110 cases formed the study group. In our study most of the patients were in their reproductive age group i.e. in 21-40 years, they comprised 58.18% of cases of adnexal masses. The youngest patient in our study was of 15 years of age and the oldest was of 75 years of age. (Table 1).

Out of the 110 patients included in our study, 10 females were unmarried and 100 females were married. The most common lesion in unmarried females were mature cystic teratoma (60%) followed by benign serous cyst adenoma (30.0%).

In present study we found that 79% of adnexal masses were due to ovarian pathology, 15.45% cases were due to tubal lesion mostly due to ectopic gestation, only 5.45% cases had combined pathology i.e. due tubovarian abscess and endometriosis.(Table 2)

Our study revealed that most common of adnexal masses due to ectopic gestation or benignancy were seen upto 2<sup>nd</sup> decade of life. Inflammatory lesions were mostly in 3<sup>rd</sup> to 4<sup>th</sup> decade similarly incidence of malignancy was increased with increasing age.(Table 3)

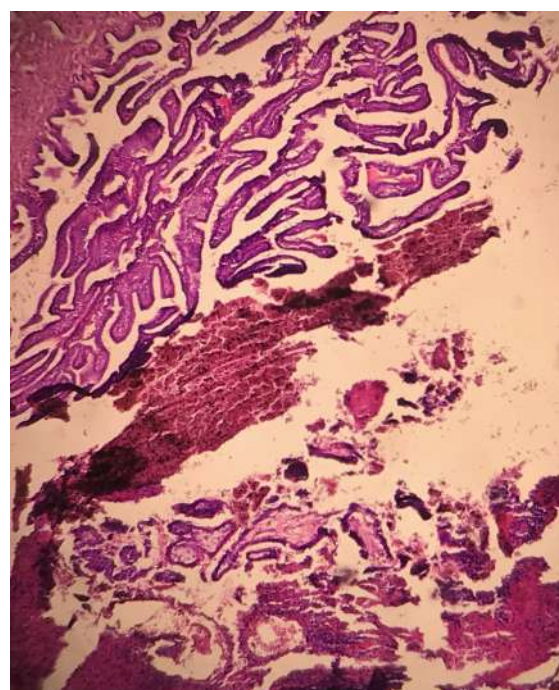
The most common clinical symptom noted in our study was Pain Abdomen, followed by palpable lump and menstrual irregularities. Some patients also had symptoms of dysuria, weight loss and fatigue (Table 4).

In our study 79% of cases of adnexal masses had an ovarian origin, 15.45% cases were of tubal origin and 5.45% cases had combined pathology i.e due to tubovarian abscess and endometriosis. Among Ovarian lesions 9.1% had non

neoplastic cyst like corpus luteal cyst or endometriosis whereas 50% cases had a surface epithelial lesion (Tables 5 and 6).

77 cases out of a total of 110 were ovarian in origin, out of which 57(74%) were benign, 05(6.5%) were borderline and 15(19.5%) were malignant. The most common benign lesion was serous cystadenoma (21 cases) followed by mucinous cyst adenoma (14 cases). The most common malignant lesion was Papillary adenocarcinoma (10 cases) followed by metastatic adenocarcinoma (3 cases).

In our study out of 110 cases of adnexal masses, 90 were in pre menopausal group and 20 were from post menopausal age group. Among the 90 cases which belonged to pre menopausal age, 81 of them (90%) had benign lesion while 9 had malignant or borderline pathology. Similarly out of 20 cases of post menopausal age 11 had malignant lesion (55%) while 9(45%) had benign lesion.



**Fig. 1:** M/E 200 X view showing intra luminal Chorionic villi

**Table 1:** Age wise distribution of patients in the study group

Age Wise Distribution	Number of Patients	Percentage (%)
<20 years	12	10.90%
21-40 years	64	58.18%
41-60 years	27	24.54%
>60 years	07	6.38%

**Table 2:** Site of lesion in adnexal mass

Tubal lesion	Ovarian origin	Combined pathology
17(15.45%)	87(79.1%)	06(5.45%)

**Table 3:** Correlation of age with histopathological lesion of adnexal masses

Age group	Ectopic gestation		Non neoplastic		Inflammatory		Benign /Borderline		Malignant		Total
1-20 Years	4	33.4%	0	0.00%	0	0.00%	8	66.7%	0	0.00%	12
21-40 Years	13	20.3%	9	14.0%	4	6.3%	35	54.7%	3	4.7%	64
41-60 Years	0	0.00%	1	3.7%	2	7.4%	16	59.5%	8	57.1%	27
61 and above	0	0.00%	0	0.00%	0	0.00%	3	42.9%	4	29.65	7
Total	17		10		06s		62		15		110

**Table 4:** Distribution of cases according to clinical presentation

Symptoms	Number of Patients(%)
Pain	60(54.54%)
Abdominal Mass	40(36.36%)
Menstrual irregularities	32(29.09%)
Other Complaints	08(7.27%)

**Table 5:** Histopathological categorization of adnexal masses

Histology of Adnexal Masses	Number of Cases	Percentage
Ectopic Gestation	17	15.5%
Inflammatory Lesion	06	5.5%
Non Neoplastic Cyst	10	9.1%
Surface Epithelial Lesion	55	50%
Germ Cell Tumor	14	12.7%
Sex Cord Stromal Tumor	04	3.6%
Metastatic Malignancy	04	3.6%
Total Cases	110	100

**Table 6:** Categorization of ovarian masses according to histopathology

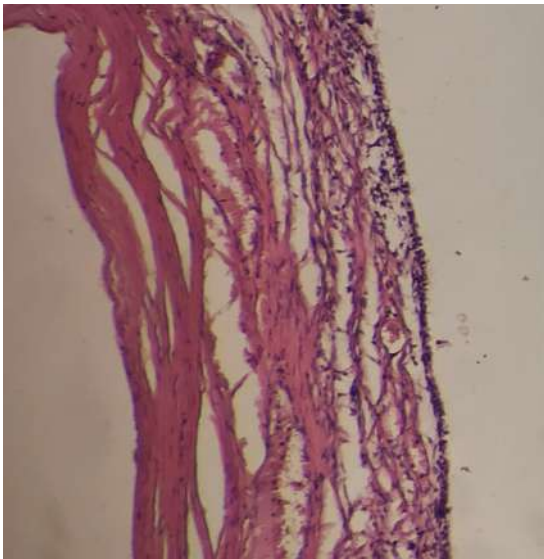Ovarian nroplasm	Number	Percentage
Benign	57	74.0%
Borderline	05	6.5%
Malignant	15	19.5%
Total cases	77	

## 5. Discussion

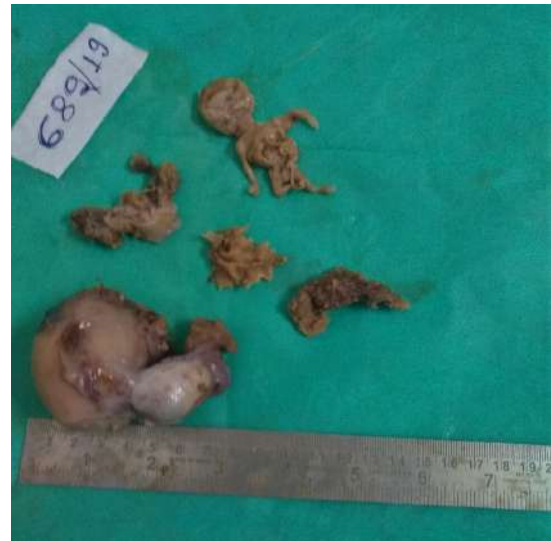Adnexal mass is a lesion arising from the ovary, fallopian tube or the surrounding connective tissue. It is a fairly common gynecological problem with a prevalence of 0.17% to 5.9% in asymptomatic females and 7.1% to 12% in symptomatic females.<sup>6</sup> In the reproductive age group ectopic pregnancy, benign neoplasms, endometriotic cyst and tubo ovarian abscess are common whereas malignancy is rare. In post menopausal women with adnexal masses both primary and secondary neoplasms of ovary must be considered along with leiomyoma and broad ligament fibroid. Ovarian malignancy carries the worst prognosis

amongst all gynecological malignancies and it becomes imperative to diagnose it as early as possible.

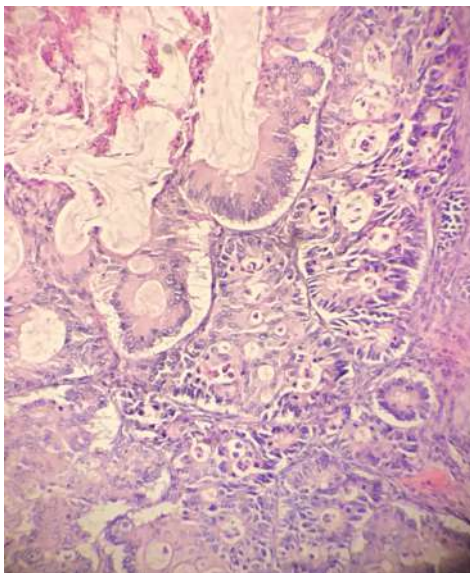
In the present study incidence of malignancy was highest in the 7<sup>th</sup> decade of life. Our findings are similar to those of Dotlic et al.<sup>7</sup> who studied 87 cases of adnexal masses and found maximum from the reproductive age group while malignancy was found to be higher in post menopausal age. Radhamani et al.<sup>8</sup> studied 100 cases of adnexal masses where the age of patients ranged from 17-80 years with a mean age of 38.11 years while the mean age of patients with malignancy was higher and was 45 years. Mittal et al.<sup>9</sup> carried out a study on 75 cases of adnexal masses, their



**Fig. 2:** M/E 400 x view Single layer of bland looking epithelial cells lining the cyst wall of Serous cyst adenoma



**Fig. 4:** Gross Examination: Ruptured Tubo Ovarian Mass showing areas of Hemorrhage and a tiny embryo



**Fig. 3:** 400X view Complex branching papillary architecture with nuclear atypia and high mitotic activity



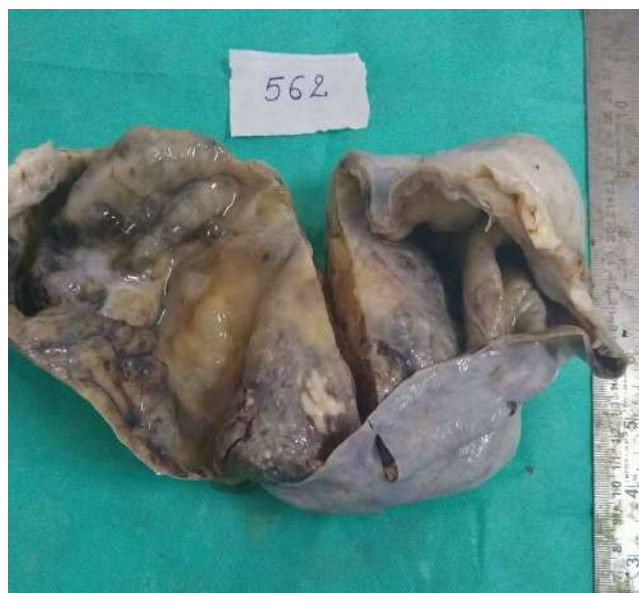**Fig. 5:** Gross examination: Hysterectomy specimen showing bilateral cystic adnexal mass with smooth outer surface

study group had a mean age of 36 years and the maximum number of malignant cases were seen above 40 years of age.

In our study the commonest clinical presentation was abdominal pain, followed by lump abdomen. Dysuria, Gastrointestinal and constitutional symptoms were less commonly seen. Our observations are consistent with Shaddha et al.<sup>10</sup> who found abdominal pain to be the commonest symptom (61.8%) followed by menstrual irregularities (25.6%). Wassim et al.<sup>11</sup> studied 110 cases of ovarian neoplasms and found abdominal pain to be the commonest clinical symptom (76%) followed by Lump

abdomen(41%). Seemer et al.<sup>12</sup> found the most common clinical presentation was lump abdomen (70.83%) followed by pain abdomen (61%) and menstrual irregularities (20.83%).

In our study out of the 110 cases, most of the cases were ovarian in origin and only few cases were both tubal and ovarian in origin. Our findings are in concordance with Mittal et al.<sup>9</sup> who studied 75 cases of adnexal masses and found 24% were tubal in origin, 68% were ovarian in origin and 8% had a dual origin i.e from the tubes and the ovaries. Seemer et al.<sup>12</sup> observed tubal pathology in 33.33% cases, ovarian pathology in 60% cases and 6.66% showed combined pathology. However our findings are in discordance with Tripathi et al.<sup>13</sup> who studied 100 cases of adnexal masses and found 56% of cases were ectopic



**Fig. 6:** Gross examination: Predominantly cystic cut surface with central solid necrotic mass

gestation, 10% were ovarian in origin, 31% had a dual origin while 3% cases were found originating from the broad ligament.

Out of the 110 cases in our study, incidence of ectopic pregnancy was seen in 15.45%. Other non-neoplastic lesions were endometriotic cyst and tuboovarian abscess. 77 out of 110 cases presented as ovarian neoplasm, out of which 74% were benign, 6.5% had border line pathology while 19.5% were malignant. The most common benign lesion was Serous cyst adenoma followed by Mucinous cyst adenoma and dermoid cyst. The most common malignant lesion Papillary adenocarcinoma followed by metastatic adenocarcinoma.

Modi et al.<sup>14</sup> studied 97 cases of ovarian neoplasms and found 84.5% to be benign, 2.1% border line and 13.4% to be malignant. Surface epithelial tumor was the commonest histological type in both benign and malignant categories followed by germ cell tumours. Their findings are similar to our study.

Kumari et al.<sup>15</sup> studied 65 cases of adnexal masses out of which 40 were diagnosed benign on histopathological examination, 4 were borderline and 21 were labeled as malignant. Among the malignant tumors mucinous cyst adenocarcinoma was the commonest(12.3%) followed by serous cystadenocarcinoma(10.8%). In their study the commonest malignant tumor was surface epithelial in origin a finding which is similar to ours.

Priya et al.<sup>16</sup> studied 150 cases of ovarian neoplasms. They found 103 to be benign(68.66%), 3 were borderline(2.0%) and 44 were malignant(25.33%). Histopathologically surface epithelial tumors were the commonest seen in 93(62%) cases followed by germ cell

tumors 37(24.67%) cases and sex cord stromal tumors in 14 cases(9.33%).

Mondal et al.<sup>17</sup> evaluated histological pattern of 957 ovarian neoplasms over a ten year period. The most common histological type was serous cystadenoma (29.2%) followed by mature teratoma(15.9%) and mucinous cyst adenoma(11.2%). Major portion of malignant tumors were seen arising from the surface epithelium. Serous cystadenocarcinoma was the commonest malignant tumor in their study.

Forae et al.<sup>18</sup> studied 236 cases of ovarian masses, they found 121 cases were non neoplastic lesions(functional cysts), 79 (33.5%) were benign neoplasms and 36(15.6%) were malignant lesions. Among the non neoplastic lesion corpus luteal cyst was the commonest lesion encountered histopathologically followed by haemorrhagic cyst. The commonest malignant lesion in their study was germ cell tumor followed by surface epithelial cell tumor. This in discordance with our study wherein the commonest malignant lesion was surface epithelial in origin.

To conclude, adnexal mass often poses a diagnostic dilemma to the treating physician. Ectopic gestation is often a cause of adnexal mass among patients of reproductive age group. Ovarian neoplasm constitute another major cause of adnexal mass, serous cyst adenoma is the commonest benign lesion seen while serous cyst adenocarcinoma is the commonest malignant ovarian lesion. The limitation of our study is a relatively small sample size of 110 patients and relevant ultrasonographic findings were not available for all patients. Large multi centric studies are required to comment on the histopathological subtypes seen in adnexal masses.

## 6. Source of Funding

None.

## 7. Conflict of Interest

The authors declare that there is no conflict of interest.

## References

1. Graham L. ACOG Releases Guidelines on management of adnexal masses. *Am Fam Physician*. 2008;77(9):1320–3.
2. Souilly RE, Young RH, Clement PB. Atlas of Tumor Pathology. In: Tumors of ovary, maldeveloped gonads, fallopian tube and broad ligament. Washington DC: Armed Forces Institute of Pathology; 1999. p. 1–168.
3. Parkin DM, Bray F, Ferlay J, Pisani P. Global Cancer Statistics, 2002. *Cancer J Clin*. 2005;55(2):74–108. doi:10.3322/canjclin.55.2.74.
4. Bhatla N, Annwen. The world ovarian cancer coalition. Atlas; 2018.
5. Consolidated Report of Population Based Cancer Registries 2001–2004. National Cancer registry program. Indian Council of Medical Research, Bangalore, 2006.
6. Bhagde AD, Jani SK, Patel MS, Shah SR. An analytical study of 50 women presenting with an adnexal mass. *Int J Reprod, Contracept, Obstet Gynecol*. 2016;6(1):262–5. doi:10.18203/2320-1770.ijrcog20164671.

7. Dotlic J, Terzic M, Likic I, Atanackovic J, Ladjevic N. Evaluation of adnexal masses: Correlation between clinical, ultrasound and histopathological findings. *Vojnosanitetski Pregled*. 2011;68(10):861–6. doi:10.2298/vsp1110861d.
8. Radhamani S, Akhila MV. Evaluation of Adnexal Masses. Correlation of Clinical, Sonological and Histopathological findings in adnexal masses. *Int J Sci Study*. 2017;4(1):88–92.
9. Mittal A, Kundal RK, Kaur K, Mathur M, Sandhu A, Kaushal N. Clinico-Pathological Correlation of Tubo-Ovarian Lesions. *Ann Int Med Dent Res*. 2018;4(3):51–5. doi:10.21276/aimdr.2018.4.3.pt11.
10. Sharadha SO, Sridevi TA, Renukadevi TK, Gowri R, Binayak D, Indra V. Ovarian Masses: Changing Clinico Histopathological Trends. *J Obstet Gynecol India*. 2015;65(1):34–8. doi:10.1007/s13224-014-0575-7.
11. Wasim T, Majrroh A, Siddiq S. Comparison of clinical presentation of benign and malignant Ovarian tumours. *J Pak Med Assoc*. 2009;59:18–21.
12. Seemer H, Ramesh K, Marwah P. Clinico-pathological co-relation of tubo ovarian lesions. A study of 75 cases; Research and Review. *J Med Health Sci*. 2014;3(4):117–26.
13. Tripathi U, Munda G. Study of correlation of ultrasonography with surgical evaluation of adnexal masses: a prospective study. *Int J Reprod, Contracept Obstet Gynecol*. 2018;7(10):4218–22. doi:10.18203/2320-1770.ijrcog20184155.
14. Modi D, Rathore GB, Delwadia KN, Goswami HN. Histopathological pattern of neoplastic ovarian leiosns. *IAIM*. 2016;3(1):51–7.
15. Kumari N, Gupta V, Kumari R, Makhija A. Evaluation of risk of malignancy index as a diagnostic tool in cases with adnexal mass. *Int J Reprod, Contracept, Obstet Gynecol*. 2016;5(6):1857–61. doi:10.18203/2320-1770.ijrcog20161677.
16. Parmar P, Sehgal S, Mathur K, Yadav A. Histopathological study of ovarian tumours in tertiary care center. *Int J Med Res Prof*. 2017;3(2):96–8.
17. Mondal SK, Banyopadhyay R, Nag DR, Roychowdhury S, Mondal PK. Histopathological pattern, bilaterality and clinical evaluation of 957 cases of ovarian neoplasm: A 10 year study in a tertiary hospital in eastern india. *J Cancer Res Ther*. 2011;7(4):433–7.
18. Forae G, Aligbe J. Ovarian Tumors among Nigerian females: A private practice experience in Benin city, Nigeria. *Adv Biomed Res*. 2016;5(1):61. doi:10.4103/2277-9175.179183.

### Author biography

**Sunita Bhargava**, Senior Professor

**Gunjan Bhatia**, Senior Demonstrator

**Cite this article:** Bhargava S, Bhatia G. Clinicopathological study of Tubo ovarian masses- A study of 110 cases. *Indian J Pathol Oncol* 2021;8(1):26-31.