



Case Report

Radiation-induced angiosarcoma masquerading as recurrent carcinoma cervix - A diagnostic challenge

Varsha P^{1,*}

¹Dept. of Pathology, Kidwai Cancer Institute, Bangalore, Karnataka, India



ARTICLE INFO

Article history:

Received 24-04-2020

Accepted 01-05-2020

Available online 19-08-2020

Keywords:

Carcinoma cervix

Immunohistochemistry

ABSTRACT

Angiosarcomas are malignant mesenchymal tumours that develop from the endothelium of a blood vessel. It is an uncommon cancer that occurs among men and women, more often among older adults and usually in the skin, soft tissue, breast, or liver. Angiosarcoma is a rare but well recognised complication after radiation therapy. Most post radiation angiosarcomas are seen in the breast and very few cases of angiosarcoma have been reported following radiotherapy for cervical cancer.

We report one such case of post radiation angiosarcoma which developed years after radiation therapy for carcinoma cervix.

© 2020 Published by Innovative Publication. This is an open access article under the CC BY-NC license (<https://creativecommons.org/licenses/by-nc/4.0/>)

1. Case Report

1.1. Case history

A 56 year old female was diagnosed with focally keratinising grade 3 squamous cell carcinoma for which she had undergone hysterectomy elsewhere and was referred to our institute for radiotherapy. She underwent external beam radiotherapy of the pelvis (Telecobalt, total 3771 cGy in 25 fractions) and intravaginal brachytherapy (30 Gy). After a latency period of 6 years the patient presented with a lower abdominal wall nodule in the midline.

1.2. Imaging

CT pelvis showed a nodular heterogeneously enhancing soft tissue lesion in the lower anterior abdominal wall in the midline, 3 cm superior to the pubic symphysis. No recurrent lesion was seen in the vault.

1.3. Cytology

PAP smear from vaginal vault showed no malignant cells. FNA of abdominal wall nodule was reported as Positive for

malignancy with a differential diagnosis of -

1. Recurrent squamous cell carcinoma with abdominal wall metastasis.
2. Post radiation sarcoma.

1.4. Histopathological examination

A wide local excision of the abdominal wall nodule was done and sent for histopathological examination.

1.5. Gross findings

Skin with an underlying grey tan tumour with ill defined borders measuring 4x3.5x1.8 cms.

1.6. Microscopy

Sections showed highly pleomorphic spindle shaped cells arranged in sheets and nodules infiltrating into the subcutaneous tissue. Areas of necrosis, haemorrhage and dilated vascular spaces were also seen. Overlying skin showed features of seborrheic keratosis. Differential diagnosis on the basis of morphology alone included -

1. Metastatic squamous cell carcinoma.

* Corresponding author.

E-mail address: drvarshaprakash@gmail.com (Varsha P).

2. Endometrial stromal sarcoma.
3. Malignant melanoma.
4. Post radiation sarcomas viz angiosarcoma.

1.7. Immunohistochemistry (IHC)

The tumour cells showed strong CD34, CD31 immunoreactivity, strong Cyclin D1 nuclear staining, weak D2-40 and CD10 cytoplasmic staining. Ki67 proliferative index was 30%. The tumour cells were negative for panCK, EMA, ER, PR, p16, p40, p63, HMB45 and S100 which excluded the diagnosis of metastatic squamous cell carcinoma, endometrial stromal sarcoma and malignant melanoma. Following IHC a diagnosis of post-radiation angiosarcoma was given.

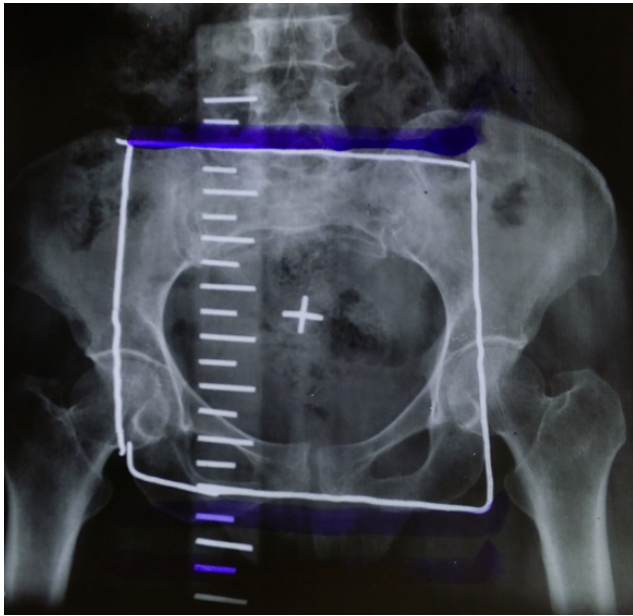


Fig. 1: X-ray of pelvis with the area marked for external beam radiotherapy

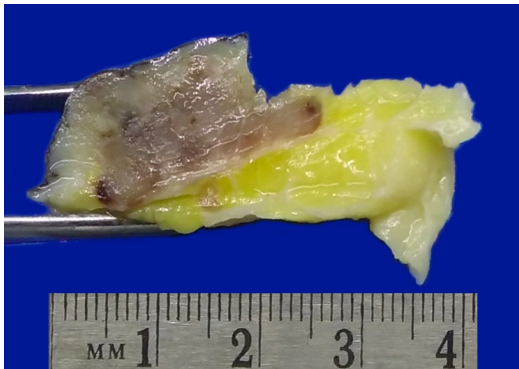


Fig. 2: Grey tan tumour arising within the abdominal wall with skin showing thickening

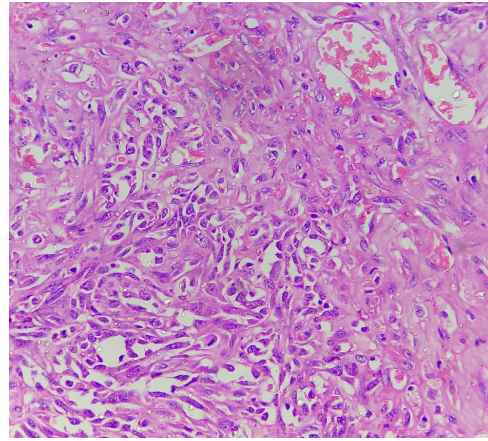


Fig. 3: Neoplastic oval to spindle cells with open chromatin, prominent nucleoli & scant cytoplasm. Many mitotic figures are noted (H&E X40)

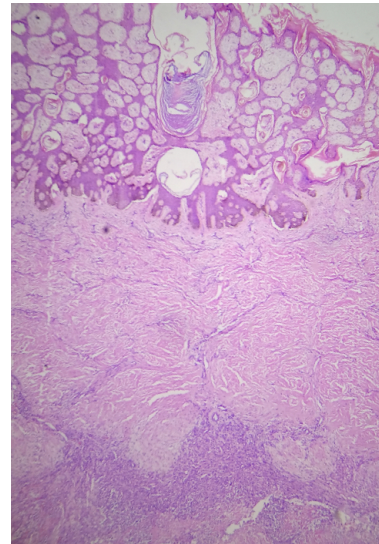


Fig. 4: Overlying skin showing features of seborrheic keratosis (H&E X10)

2. Discussion

Angiosarcoma is a malignant tumour the cells of which variably recapitulate the morphologic and functional features of normal endothelium.¹ Mean age at diagnosis is 59 years among patients with radiotherapy and 66 years among patients without radiotherapy.² Angiosarcomas can be subdivided into cutaneous angiosarcoma, lymphoedema-associated angiosarcoma, radiation-induced angiosarcoma, primary breast angiosarcoma, and soft-tissue angiosarcoma.³

2.1. Radiation-induced angiosarcoma

Radiotherapy is an independent risk factor for the development of angiosarcoma.³ The median interval

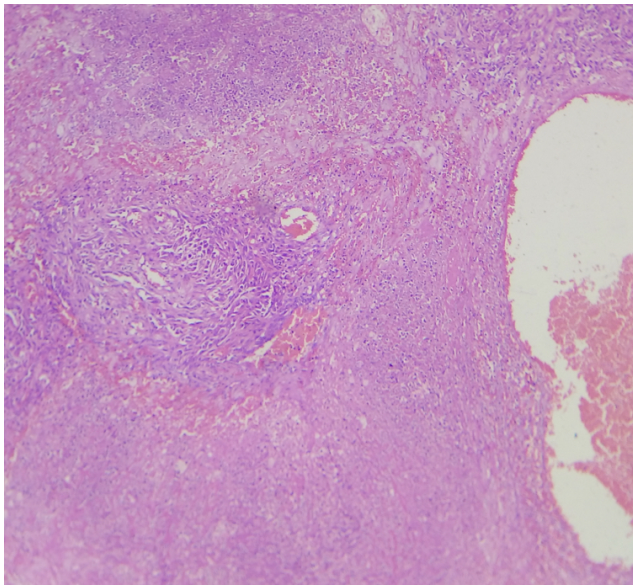


Fig. 5: Areas of necrosis, haemorrhage and dilated vascular spaces seen (H&E X4)

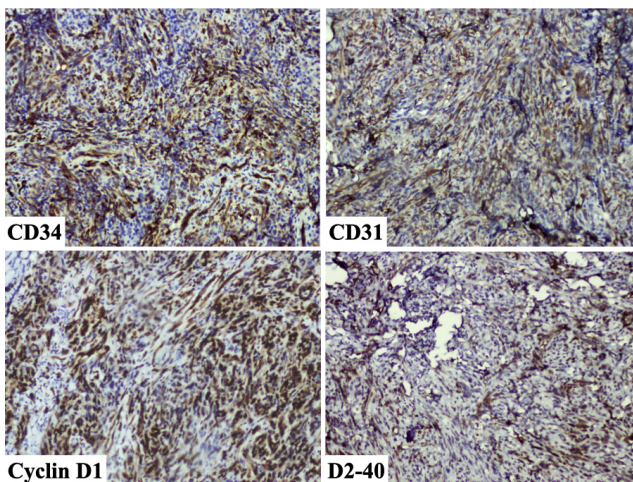


Fig. 6: Immunohistochemistry showing CD34, CD31, Cyclin D1 and D2-40 positivity

between irradiation and diagnosis of angiosarcoma was 6 years in one study.⁴ Although the association between radiotherapy and subsequent angiosarcoma is best described for breast cancer therapy, it is not exclusive to breast lesions and can occur in patients with cancers of cervix, uterus, ovary, melanoma, Hodgkin's lymphoma.^{2,4} There have been around 22 cases of post radiation angiosarcoma reported following irradiation for the treatment of carcinoma cervix. The most common sites of involvement of angiosarcoma following irradiation for carcinoma cervix include abdominal wall, gluteal region, vaginal vault, small intestine and rarely the mesentery and serosa of appendix.^{5,6} The histological spectrum of angiosarcoma varies from well to poorly

differentiated lesions with vascular channels.⁴ The poorly differentiated angiosarcomas pose a challenge in diagnosis because the vascular channels are difficult to identify. Therefore immunohistochemistry becomes an important adjunctive procedure in identifying these lesions.¹ Angiosarcomas typically express endothelial markers including von Willebrand factor, CD34, CD31, Ulex europaeus agglutinin 1, and vascular endothelial growth factor (VEGF).³ Laminin and type IV collagen can also be used to accentuate the vascular channel formation.¹ D2-40 immunostaining is seen in a subset of post radiation angiosarcomas.⁷ Also MYC over expression was found to be a hallmark of secondary angiosarcoma.⁷ In our case neoplastic cells expressed endothelial cell markers like CD34, CD31 and D2-40 with over expression of Cyclin D1 which is an unusual finding previously reported in one case of uterine angiosarcoma.⁸

3. Conclusion

Post radiation angiosarcoma is a rare entity encountered following radiotherapy for cervical carcinoma. We have reported a case of angiosarcoma of the abdominal wall following radiotherapy for carcinoma cervix. The diagnosis was challenging due to the poorly differentiated morphology and immunohistochemistry was helpful in arriving at a diagnosis of post radiation angiosarcoma.

4. Source of Funding

None.

5. Conflict of Interest

None.

References

1. M Fletcher CD, Unni KK. Angiosarcoma of soft tissue. In: Weiss SW, Lasota J, Miettinen MM, editors. World Health Organization Classification of Tumours Pathology and Genetics of Tumours of Soft Tissue and Bone. vol. 2010. Lyon, France: IARC press; p. 175–7.
2. Virtanen A, Pukkala E, Auvinen A. Angiosarcoma after radiotherapy: a cohort study of 332163 Finnish cancer patients. *Br J Cancer*. 2007;97(1):115–7.
3. Young RJ, Brown NJ, Reed MW, Hughes D, Woll PJ. Angiosarcoma. *Lancet Oncol*. 2010;11(10):983–91.
4. Brenn T, Fletcher C. Radiation-Associated Cutaneous Atypical Vascular Lesions and Angiosarcoma Clinicopathologic Analysis of 42 Cases. *Am J Surg Pathol*. 2005;29:983–96.
5. Policarpio-Nicolas MLC, Nicolas MM, Keh P, Laskin WB. Post-radiation angiosarcoma of the small intestine: a case report and review of literature. *Ann Diagn Pathol*. 2006;10(5):301–5.
6. Report C. Angiosarcoma of the vagina A light and electronmicroscopy study. *Acta Obstet Gynecol Scand*. 1991;70:169–72.
7. Guo T, Zhang L, Chang NE, Singer S, Maki RG, Antonescu CR. Consistent MYC and FLT4 gene amplification in radiation-induced angiosarcoma but not in other radiation-associated atypical vascular lesions. *Genes, Chromosomes Cancer*. 2011;50(1):25–33.
8. Liu Y. Case Report Uterine Angiosarcoma : A Case Report and Literature Review. *Int J Gynecol Pathol*. 2016;35:264–8.

Author biography

Varsha P Pathologist

Cite this article: Varsha P . Radiation-induced angiosarcoma masquerading as recurrent carcinoma cervix - A diagnostic challenge. *Indian J Pathol Oncol* 2020;7(3):491-494.